

Effects of melatonin hormone on hippocampus in pinealectomized rats: An immunohistochemical and biochemical study

Murat Abdulgani KUS¹, Mustafa SARSILMAZ², Omur KARACA³, Tolgahan ACAR², Burak GÜLCEN³, Adnan Adil HISMIOGULLARI⁴, Murat OGETURK⁵, Ilter KUS³

¹ Health of College, University of Mehmet Akif Ersoy, Burdur, Turkey

² Department of Anatomy, Faculty of Medicine, University of Sifa, Izmir, Turkey

³ Department of Anatomy, Faculty of Medicine, University of Balikesir, Turkey

⁴ Department of Biochemistry, Faculty of Medicine, University of Balikesir, Turkey

⁵ Department of Anatomy, Faculty of Medicine, University of Firat, Elazig, Turkey

Correspondence to: Prof. Dr. Ilter Kus
University of Balikesir, School of Medicine, Department of Anatomy
Cagis Yerleskesi, 10145, Balikesir, Turkey.
TEL: +90-266-6121455; FAX: +90-266-6121459; E-MAIL: ilterkus@hotmail.com

Submitted: 2013-04-26 Accepted: 2013-06-13 Published online: 2013-08-03

Key words: hippocampus; pinealectomy; melatonin; immunohistochemistry; rat

Neuroendocrinol Lett 2013; 34(5):418–425 PMID: 23922041 NEL340513A06 ©2013 Neuroendocrinology Letters • www.nel.edu

Abstract

OBJECTIVE: The effects of melatonin on antioxidant status were examined in pinealectomized rats using enzymatic, histological and immunohistochemical techniques. The aim of this study is to investigate the effects of melatonin on hippocampal apoptosis.

MATERIALS AND METHODS: Male Wistar rats (n=21) were divided into 3 groups: Group I and group II were designated as control (sham-pinealectomy) and pinealectomized rats, respectively. Rats in group III were pinealectomized and injected daily with melatonin (1 mg/kg) for 3 months beginning at day 7 after surgery. At the end of experimental period, all rats were killed by decapitation. The brains of the rats were removed and the hippocampus tissue was obtained from all brain specimens. The right hippocampal specimens of all rats were used for determination of superoxide dismutase (SOD), glutathione peroxidase (GSH-Px), and malondialdehyde (MDA) levels. The left hippocampus tissue specimens of all animals were used for immunohistochemical and histological evaluation.

RESULTS: The levels of SOD and GSH-Px were significantly decreased, and MDA levels were significantly increased in pinealectomized rats compared to the controls. In the histological and immunohistochemical evaluation of this group, increase of pyknotic cells, vacuolar degeneration and apoptosis were observed. However, increased SOD and GSH-Px enzyme activities, and decreased MDA levels were detected in the rats administered melatonin after pinealectomy. Furthermore, histological and apoptotic changes in hippocampus caused by pinealectomy were lost in the rats treated with melatonin.

CONCLUSIONS: The results of our study revealed that pinealectomy-induced oxidative damage and morphological changes in the hippocampal tissue were suppressed by melatonin.

INTRODUCTION

The hippocampus (Cornu Ammonis) is a bilaterally symmetrical structure shaped somewhat like a cashew nut and extends along the ventromedial border of the temporal lobe. It is a cytoarchitecturally distinct structure folded into the cerebral cortex. The hippocampus is divided into four areas, known as CA1, CA2, CA3 and CA4, due to their cellular differences. CA1 is the nearest area to the subiculum while CA3 is the nearest area to the gyrus dentatus. Short-term memory, which is recognized as the location for the storage of new information, is closely related to the hippocampus, furthermore, the right hippocampus shows a higher degree of activity in functions related to visual memory, whereas the left hippocampus shows a higher degree of activity in functions related to verbal memory (Teyler & Discenna 1984; Songur *et al.* 2001).

The function of hippocampus is regulated by cholinergic innervations that arise mainly from the medial septum. Lesioning the medial septum removes the hippocampal cholinergic innervation and it induces a memory defect in experimental animals (Teyler & Discenna 1984). In humans, hippocampectomy disrupted the memory formation in almost all kinds of tasks that require new learning, in particular declarative memory, leaving only implicit forms of long-term memory, such as procedural memory and priming intact (Warrington & Weiskrantz 1968). In rats, however, some tasks were relatively unaffected by the damage of the hippocampus, for example recognition memory (Aggleton *et al.* 1986) and fear conditioning (Phillips & Ledoux 1994), however, the most dramatic memory failure in animals was observed in tasks that required spatial memory (Morris *et al.* 1982).

Melatonin (N-acetyl-5-methoxytryptamine) is an endogenous neurohormone produced by the pineal gland in mammals and is found in all body fluids after its release from the pineal (Reiter *et al.* 2013). It possesses both hydrophilic and lipophilic characteristics and easily penetrates all biological membranes including both the placenta and the blood-brain barrier (Costa *et al.* 1995; Okatani *et al.* 1998). Melatonin is known to be involved in a variety of physiological processes including the regulation of endocrine rhythms (Barrett & Bolborea 2011), antigonadotropic effects (Kus *et al.* 2002), neuroprotective effects (Tan *et al.* 1998) and stimulation of the immune function (Mauriz *et al.* 2013). Besides these functions, many recent studies have shown that melatonin functions effectively as an antioxidant, i.e., a hydroxyl radical and a peroxy radical scavenger (Galano *et al.* 2011). Also, melatonin stimulates enzymes of the antioxidative defense system such as superoxide dismutase and glutathione peroxidase, moreover, it acts to protect cell components including nuclear DNA, membrane lipids and cytosolic proteins from oxidative attack (Reiter *et al.* 1997).

Oxidative damage and decrease of cells have been reported in hippocampus following pinealectomy – the

surgical removal of pineal gland and exogenous melatonin hormone has been reported to improve pinealectomy-induced hippocampal tissue injury (Reiter *et al.* 1999; Delibas *et al.* 2002; Ates *et al.* 2006; Turgut *et al.* 2006; De Butte & Pappas 2007). However no immunohistochemical studies concerning apoptotic changes that may develop in hippocampus tissue after pinealectomy have been encountered and no studies putting forward the effect of exogenous melatonin hormone on apoptosis that may develop in hippocampus following pinealectomy are available.

The aim of this study was to investigate the effects of melatonin hormone on apoptotic changes in hippocampus induced by pinealectomy.

MATERIALS AND METHODS

Animals and treatments

Adult male Wistar rats (weighing 230–250 g, n=21) were obtained from Experimental Research Centre of Firat University (Elazig, Turkey). The animal studies were carried out according to the guidelines of European Community Council for experimental animal care. They were kept at a constant temp (21±1 °C) and controlled light conditions (light, 07.00–19.00). Food (standard pellet diet) and tap water were supplied *ad libitum*.

The animals were divided into three groups. Group I (n=7) and group II (n=7) were designated as control (sham-pinealectomy) and pinealectomized rats, respectively. They received 10% ethanol (0.1 ml s.c.) alone. Rats in group III (n=7) were pinealectomized and injected daily with melatonin (1 mg/kg dissolved in 0.1 ml 10% ethanol s.c.; Sigma, St. Louis MO, USA) for 3 months beginning at day 7 after surgery.

Pinealectomy procedure

Pinealectomy was performed as described by Hoffman & Reiter (1965). Rats were anesthetized with ketamine hydrochloride (75 mg/kg) and xylazine (8 mg/kg) before the operation and the entire procedure was completed within 15 min. In brief, the skull skin was opened by a longitudinal midline incision and using a pointed dental burr, a piece of bone was removed at the juncture of the lambda and the sagittal suture lines. The pineal was grasped with fine forceps and removed. The bone disk was returned to its original position and the skin flaps pulled together and pinealectomy was confirmed by the histological evaluation of the gland for each animal. In sham pinealectomized animals, the same procedure was used except that the pineal gland was not removed.

At the end of the three-month experimental period, all rats were killed by decapitation and the brains of rats were removed and hippocampus tissues were obtained from all the brain specimens. The right hippocampus tissue specimens of all rats were washed twice with cold saline solution, placed into glass bottles, labelled and

stored frozen (-30°C) for eventual determination of superoxide dismutase (SOD), glutathione peroxidase (GSH-Px) and malondialdehyde (MDA) production. The left hippocampus tissue specimens were used for histological and immunohistochemical evaluation.

Biochemical analysis of hippocampus tissues

For biochemical analysis, the tissues were weighed and homogenized in four volumes of ice-cold Tris-HCl buffer (50 mM, pH 7.4) containing 0.50 ml/l Triton X-100 with a homogenizer (IKA Ultra-Turrax T 25 Basic) for 2 min at 18,705 g. All procedures were performed at $+4^{\circ}\text{C}$. Tissue MDA levels were determined on the homogenate which was centrifuged at 5,000 g for 60 min to remove debris and the clear supernatant fluids were separated and kept at -40°C until the enzyme activity measurements were performed (within a week of completion of experiments).

Determination of superoxide dismutase activity

Total (Cu-Zn and Mn) SOD (EC 1.15.1.1) activity was determined based on the method of Sun *et al.* (1988). The principle of the method is based on the inhibition of Nitro Blue Tetrazolium (NBT) reduction by the xanthine-xanthine oxidase system as a superoxide generator. Activity was assessed in the ethanol phase of the supernatant after 1 ml of ethanol-chloroform mixture (5:3, v/v) was added to the same volume of sample and centrifuged. One unit of SOD is defined as the amount of enzyme causing 50% inhibition in the NBT reduction rate. The SOD activity was expressed as U/g protein.

Determination of glutathione peroxidase activity

Glutathione peroxidase (GSH-Px, EC 1.6.4.2) activity was measured by the method of Paglia & Valentine (1967). The enzyme reaction in the tube containing NADPH, reduced glutathione (GSH), sodium azide and glutathione reductase was initiated by addition of H_2O_2 , and the change in absorbance at 340 nm was monitored by a spectrophotometer. Glutathione peroxidase activity was expressed as U/g protein.

Determination of malondialdehyde level

The tissue malondialdehyde (MDA) level was determined using a method of (Esterbauer & Cheeseman 1990), based on reaction with thiobarbituric acid (TBA) at $90-100^{\circ}\text{C}$. In the TBA test reaction, MDA and TBA react to produce a pink pigment with an absorption maximum at 532 nm. The reaction was performed at pH 2–3 and 90°C for 15 min. The sample was mixed with two volumes of cold 10% (w/v) trichloroacetic acid to precipitate the protein. The precipitate was centrifuged and an aliquot of the supernatant was reacted with an equal volume of 0.67% (w/v) TBA in a boiling water-bath for 10 min. After cooling, the absorbance was read at 532 nm and the results were expressed as nmol/g wet tissue, by reference to a standard curve pre-

pared from measurements made with a standard solution (1,1,3,3-tetramethoxypropane).

Histological examination

The hippocampus tissue specimens were fixed in a neutral formalin solution (10%). After dehydration procedures, the tissue specimens were embedded in paraffin wax and sectioned (thickness, 5 mm). Levels of sections and CA1, CA2 and CA3 areas in the hippocampus were found with the help of the stereotaxic atlas and were stained with Hematoxylin-Eosine and Bax. Measurements were obtained from 4 images per rat for the left hemispheres (coordinates were adjusted to 2.64–3.00 mm posterior from the bregma, according to the (Paxinos & Watson 2007). In stained with Hematoxylin-Eosine areas, the numbers of pyknotic neurons in the pyramidal cell layer were counted using light microscopy (Olympus BX 50) under a 40-fold magnification objective with the help of the eyepieces graticules. Four sections were taken from each animal to obtain an average number of pyknotic cells in a fixed field.

Immunohistochemical procedure

For immunohistochemical staining of Bax (a marker protein of apoptosis), paraffin sections were cleaned in xylene, hydrated and then placed in phosphate buffered saline (PBS; pH 7.6). Antigen retrieval was performed by boiling for 15 min in citrate buffer (0.01 M). Sections were treated with 3% hydrogen peroxide for 5 min to quench endogenous peroxidase activity, rinsed with deionized water and then washed with PBS. Sections were incubated first with 1% pre-immune rabbit serum to decrease non-specific staining and then with a monoclonal antibody against Bax protein (Dako, Carpinteria CA, USA) at 23°C in a moist chamber for 1 h. Detection of the antibody was performed using a biotin-streptavidin detection system (Bio-Genex, San Ramon CA, USA) with 3-amino 9-ethyl carbazole (AEC) as chromogen (Dako, Carpinteria CA, USA). Sections were counterstained with Mayer's hematoxylin, dehydrated and then cover-slipped with Permount.

Immunoreactivity for the Bax protein was scored semi-quantitatively and stained sections were evaluated using a light microscope with the results expressed as a score based on the percentage of the total field stained positively with monoclonal antibody against Bax protein. Scores were based on the following scale; (heavy, 5+): over 80% of the field showing positive staining; (strong, 4+): 60–79%; (moderate 3+): 40–59%; (low 2+): 20–39%; (minimal, 1+): 1–19%; and no staining (0) (Zararsiz *et al.* 2007). The brightness setting of the light microscope was optimized to show more clearly all the apoptotic cells in the groups and the background staining was not considered for assessment.

All histological and immunohistochemical evaluations were performed by an experienced pathologist in a blind manner.

Statistical analysis

Quantitative data (The numbers of pyknotic cells, SOD, GSH-Px and MDA values) are expressed as means \pm standard deviations (SD). All statistical analyses were made with the statistical software package SPSS, version 11.0 (SPSS, Chicago, IL, USA). Data were tested for normal distribution using the Kolmogorov-Smirnov test. Since all data were found to be normally distributed, within group comparisons were made using one-way ANOVA followed by an LSD post-hoc test and the level of significance was set at $p < 0.05$.

RESULTS

Biochemical findings

SOD, GSH-Px enzyme values, and MDA levels were determined in the hippocampus tissue samples of all

rats. In pinealectomized rats, the values of SOD and GSH-Px (oxidative antioxidant enzymes) were significantly decreased compared to those in the control group ($p < 0.05$) (Figures 1 and 2, Table 1). In addition, the MDA level, which is considered to be an important parameter of oxidative damage determination and a marker for lipid peroxidation of the tissue, was significantly higher in the pinealectomized group than in the control group ($p < 0.05$) (Figure 3, Table 1). Biochemical data from the animals that received melatonin after pinealectomy showed an increase in SOD and GSH-Px values and a decrease in MDA levels ($p < 0.05$) (Figures 1–3, Table 1).

Histological findings

When the hippocampus sections belonging to rats in the control group were examined, they were found to have a normal histological appearance (Figure 5A)

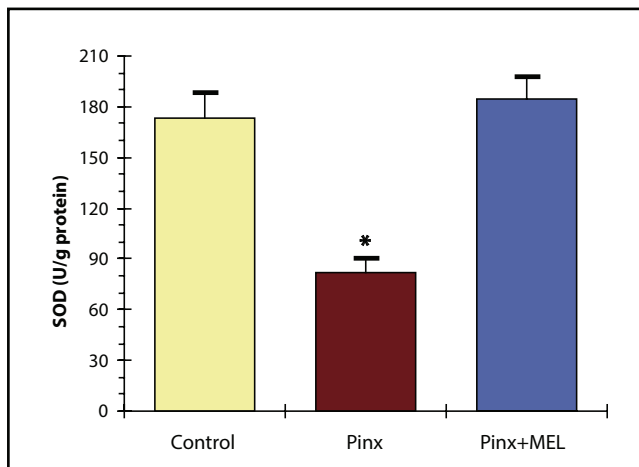


Fig. 1. Superoxide dismutase (SOD) activities in the hippocampi of rats divided into control, pinealectomy (Pinx.) and pinealectomy plus melatonin (Pinx.+MEL) subgroups. * $p < 0.05$ significant differences compared to other groups.

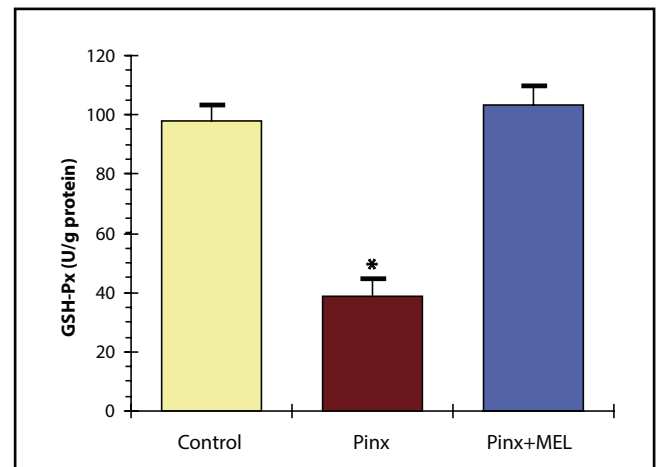


Fig. 2. Glutathione peroxidase (GSH-Px) activities in the hippocampi of rats divided into control, pinealectomy (Pinx.) and pinealectomy plus melatonin (Pinx.+MEL) subgroups. * $p < 0.05$ significant differences compared to other groups.

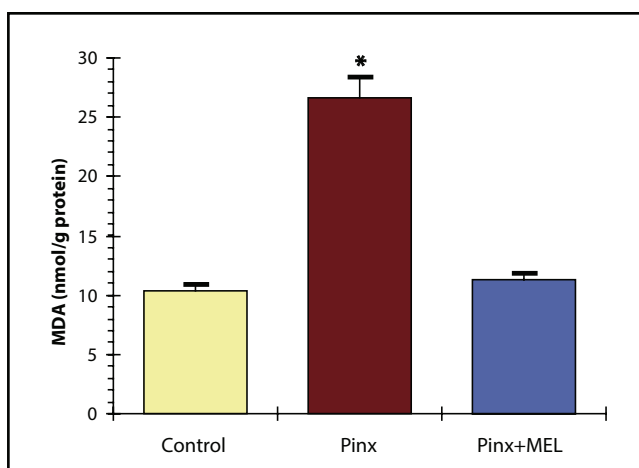


Fig. 3. Malondialdehyde (MDA) levels in the hippocampi of rats divided into control, pinealectomy (Pinx.) and pinealectomy plus melatonin (Pinx.+MEL) subgroups. * $p < 0.05$ significant differences compared to other groups.

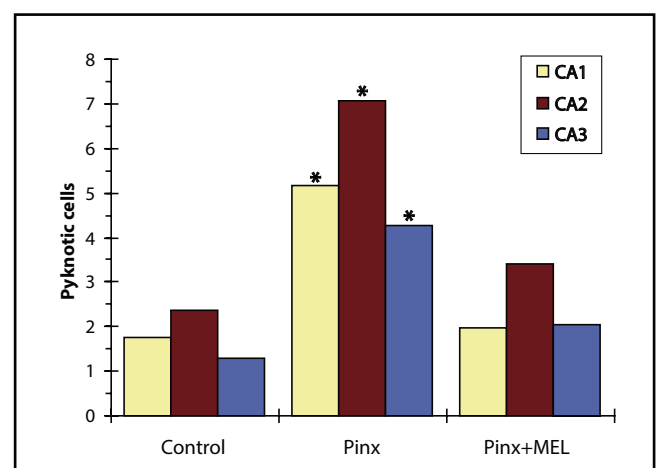


Fig. 4. The numbers of pyknotic cells per unit area in pyramidal cell layer of CA1, CA2 and CA3 regions of the hippocampi of rats divided into control, pinealectomy (Pinx.) and pinealectomy plus melatonin (Pinx.+MEL) subgroups. * $p < 0.05$ significant differences compared to other groups.

Tab. 1. SOD, GSH-Px and MDA values in the hippocampus of all groups (n=7 for per group).

PARAMETERS	CONTROL	PINEALECTOMY	PINEALECTOMY +MELATONIN
MDA (nmol/g protein)	10.36±0.56	26.62±1.77*	11.28±0.52
SOD (U/g protein)	173.41±15.13	81.63±8.76*	184.32±13.70
GSH-Px (U/g protein)	97.94±5.42	38.99±5.69*	103.28±6.23

Values are expressed as Mean±SD. * $p<0.05$ significant differences compared to other groups.

Tab. 2. The numbers of pyknotic cells per unit area in pyramidal cell layer of CA1, CA2 and CA3 regions of the hippocampus of all groups (n=7 for per group).

REGIONS	CONTROL	PINEALECTOMY	PINEALECTOMY +MELATONIN
CA1	1.76±0.44	5.16±1.32*	1.98±1.46
CA2	2.36±0.53	7.08±0.81*	3.41±0.72
CA3	1.29±0.64	4.28±1.02*	2.04±0.60

Values are expressed as Mean±SD. * $p<0.05$ significant differences compared to other groups.

In the pinealectomized rats, the number of pyknotic cells (an indicator of cell death) in hippocampus were increased compared to those in the control group ($p<0.05$) (Figures 4 and 5B, Table 2). Additionally, vacuolar degeneration was seen in this group (Figure 5C). Whereas, the rats treated with melatonin after pinealectomy showed a decrease in the number of pyknotic cells ($p<0.05$) (Figure 4 and Table 2). Furthermore, vacuolar degeneration observed after pinealectomy was lost in rats that received melatonin (Figure 5D).

Immunohistochemical findings

The hippocampus tissue sections of the rats in all three groups were semi-quantitatively evaluated for apoptosis using Bax antibody staining. Bax-stained cells were not observed (0) in the control group (Figure 6A). However, a high number of Bax-stained cells (+5) were determined in the hippocampus structure of pinealectomized rats (Figures 6B and 6C). Finally, the group that was exposed to pinealectomy along with melatonin administration had no immune positive cells (0) (Figure 6D).

DISCUSSION

In this study, we investigated the changes that occurred in the hippocampus structure after pinealectomy and the effect of externally administered melatonin on these changes. We used biochemical methods in the

present study and investigated the activity of melatonin on the hippocampus especially on oxidative damage. Additionally, tissue samples of the hippocampus were assessed by histological and immunohistochemical procedures.

The antioxidant defense systems play a protective role against oxidative stress caused by pathological processes or physiological conditions. Enzymes such as superoxide dismutase (SOD) and glutathione peroxidase (GSH-Px) are functional at this effective cellular level (Reiter *et al.* 1999). The present study revealed that SOD and GSH-Px enzyme levels in tissue samples of the hippocampus significantly decreased after pinealectomy when compared with the samples of the control group. This decrease demonstrated that the antioxidant defense mechanisms in the hippocampus tissue deteriorated after pinealectomy and that, as a result, oxidative damage had occurred.

Another indicator of damage that occurred due to oxidative stress can be seen in the malondialdehyde level (MDA), a product that forms as a result of lipid peroxidation (Reiter *et al.* 1999). In our study, we determined that hippocampus MDA levels significantly increased in the pinealectomy group as compared to the control group. The increase observed in the MDA level demonstrates that oxidative damage has been occurred in the tissue as a result of lipid peroxidation after pinealectomy.

Delibas *et al.* (2002) reported the decrease in SOD enzyme activity and the increase in levels of MDA in brain tissues of rats after functional pinealectomy. Ates *et al.* (2006) reported that oxidative damage and increase of MDA levels in hippocampus were occurred in pinealectomized rats. Similarly, lipid peroxidation has been occurred in hippocampus of rats following pinealectomy (Reiter *et al.* 1999). The impairment of antioxidant defense system in neural tissues after pinealectomy was reported in several other studies performed on rats (Turgut *et al.* 2006; De Butte & Pappas 2007) and the biochemical results of our study are consistent with the above studies (Delibas *et al.* 2002; De Butte & Pappas 2007).

It has also been reported that pinealectomy causes histological changes in the structure of hippocampus after pinealectomy. De Butte & Pappas, (2007) showed that degeneration of pyramidal cells occurred in the hippocampal CA1 and CA3 regions of pinealectomized rats. Furthermore; a decrease in the amount of pyramidal cells was also demonstrated in this experimental study. Turgut *et al.* (2006) also showed apoptotic changes in the pyramidal cells of hippocampus in pinealectomized rats. In our investigation, the number of pyknotic cells in hippocampus were increased after pinealectomy compared to those in the control group and additionally, vacuolar degeneration was seen in pinealectomized animals. In terms of histological changes which pinealectomy caused in the hippocam-

Fig. 5. **A-** Hippocampus section from control group showing a normal histological appearance. H&E; Scale bar, 200 μ m. **B-** The amount of pyknotic cells (arrows) were increased in hippocampus of pinealectomized rats. H&E; Scale bar, 200 μ m. **C-** Vacuolar degenerations (asterisks) were occurred in the pinealectomized animals. Arrows: pyknotic cells. H&E; Scale bar, 100 μ m. **D-** The rats treated with melatonin after pinealectomy showed a decrease in the number of pyknotic cells (arrow). H&E; Scale bar, 200 μ m.

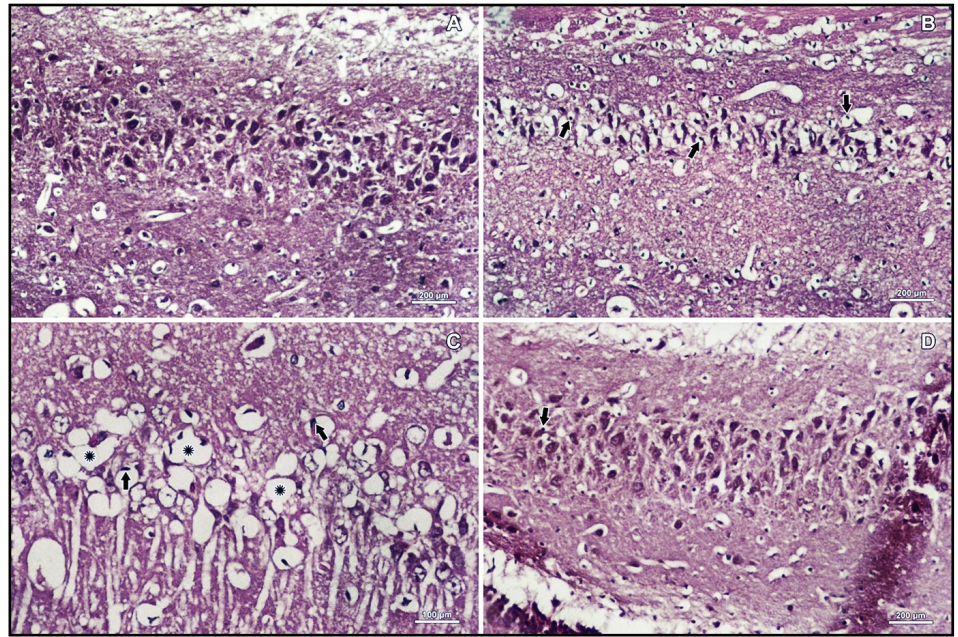
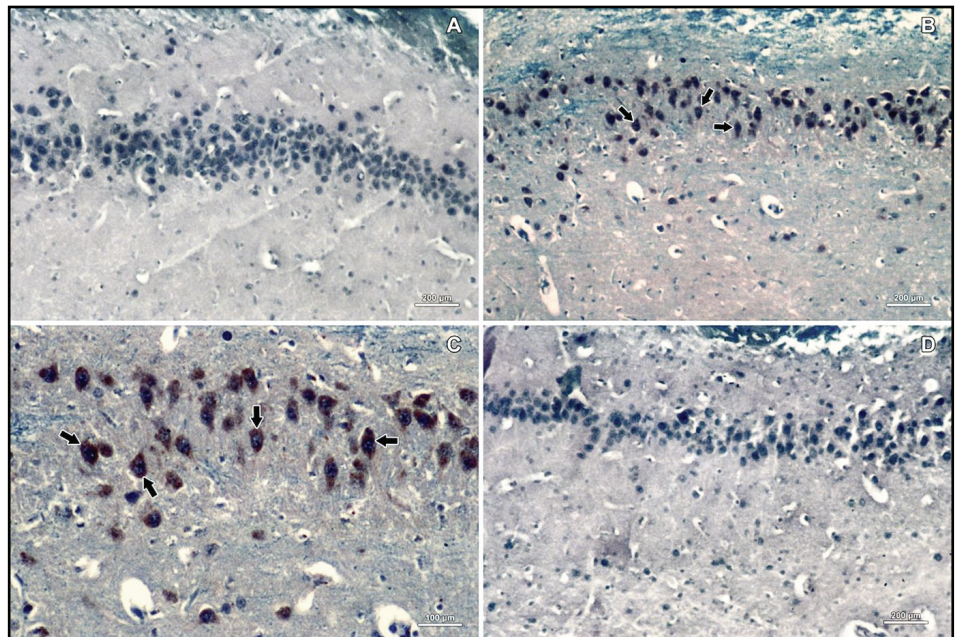


Fig. 6. **A-** Immunohistochemically, Bax-stained cells were not observed in hippocampus of control rats. Scale bar, 200 μ m. **B-** The percentage of bax immune positive cells (arrows) was high in hippocampus of pinealectomized animals. Scale bar, 200 μ m. **C-** A high number of immunohistochemically Bax-stained cells was observed in the hippocampus structure of pinealectomized rats. Scale bar, 100 μ m. **D-** Hippocampus sections of the rats administered melatonin after pinealectomy had not Bax stained cells. Scale bar, 200 μ m.



pus, our microscopic findings are in agreement with previous studies.

Apoptosis is the genetically regulated form of cell death (programmed cell death) that permits the safe disposal of cells when they are damaged or have fulfilled their intended biological function (Nagata 1997). Mitochondria play an important role in the apoptotic process. Death signals cause an increase in the permeability of the outer mitochondrial membrane, which in turn causes apoptosis. Some proteins regulate the permeability of the outer membrane of mitochondria and the most important of these are the proteins of the Bcl-2 family. Some of the proteins in this family are pro-apoptotic, whereas some are anti-apoptotic. Bax is a pro-apoptotic protein and it causes cytochrome c

release into cytoplasm from the mitochondrial membrane. Then, cytochrome c starts the apoptotic process by activating caspase in the cytoplasm. However, Bcl-2 is an anti-apoptotic protein and it inhibits cytochrome c release by preventing Bax insertion into the mitochondrial membrane. To sum up, immunohistochemical Bax staining in cytoplasm of the cells indicates apoptosis has occurred (Nagata 1997). In the present study, we immunohistochemically showed that pinealectomy caused apoptosis in the hippocampus.

The pineal gland and its main hormone, melatonin (N-acetyl-5-methoxytryptamine), are known to be involved in a variety of physiological processes including the regulation of endocrine rhythms, antigonadotropic effects and stimulation of the immune function.

Besides these functions, recently, many *in vitro* studies have shown that melatonin functions effectively as an antioxidant, i.e., a hydroxyl radical and a peroxy radical scavenger. It has also been shown that when animals and tissues are subjected to lipid peroxidation, melatonin causes a substantial protection against the oxidative destruction of lipids (Costa *et al.* 1995; Okatani *et al.* 1998; Kus *et al.* 2002; Reiter *et al.* 1997).

Additionally, melatonin possesses protective effects against neuronal damage induced by oxidative stress through exerting antioxidant properties (Tan *et al.* 1998). Kabuto *et al.* (1998) determined that iron-induced oxidative damage in brain cortex was prevented by melatonin application in rats as *in vivo* studies. Skaper *et al.* (1999) showed that the neuronal damage that occurred as a result of aging was prevented by melatonin. Mason *et al.* (1999) reported that administration of melatonin inhibits oxidative stress-induced apoptosis in granulos cells of cerebellum of rats. In other experimental study involving rats, melatonin was shown to alleviate elevated MDA levels in response to the gamma-radiation-induced damage to the brain cortex (Erol *et al.* 2004). Similarly, it has been mentioned that formaldehyde-induced oxidative tissue damage in the prefrontal cortex of rats was decreased by melatonin administration (Zararsiz *et al.* 2007).

It has also been shown that melatonin possesses the protective effects on the hippocampus. De Butte & Pappas (2007) have revealed that the losses of pyramidal cells in the hippocampal CA1 and CA3 areas in rats due to pinealectomy were eliminated by exogenous melatonin. Ozdemir *et al.* (2005) have reported that experimental-induced hippocampal damage in rats was alleviated by melatonin treatment. Similarly, it has been reported that oxidative damage in rat hippocampus induced by exposure of ethanol was decreased after melatonin application (Gonenc *et al.* 2005). Furthermore, Kus *et al.* (2007) showed that decrease of SOD and GSH-Px enzyme activities and increase of MDA levels in hippocampus caused by formaldehyde exposure were reversed by melatonin administration. Similarly, it has been determined that occurring of apoptosis in the hippocampus of rats caused by homocysteine exposure was prevented by exogenous melatonin (Baydas *et al.* 2005). Additionally, neuronal damage and increase of pyknotic cell in the hippocampus of rats resulting from cyanic acid toxicity were blocked by melatonin (Shen *et al.* 2002). Moreover, Dominguez-Alonso *et al.* (2012) have reported that melatonin increases dendritogenesis in the hilus of hippocampus. We have also showed the antioxidant effect of melatonin on hippocampus at biochemical level. In our study, increased SOD and GSH-Px enzyme activities, and decreased MDA levels were detected in the rats administered melatonin after pinealectomy. Furthermore, histological and apoptotic changes in hippocampus caused by pinealectomy were lost in these rats.

In conclusion, the results obtained in the present study indicate that melatonin treatment prevents pinealectomy-induced oxidative tissue damage and apoptosis in the hippocampus of rats, possibly through its antioxidant action.

ACKNOWLEDGEMENTS

The authors wish to express their appreciation to Prof. Dr. Khalid Rahman from Liverpool John Moores University, School of Pharmacy and Biomecular Sciences, UK for final linguistic revision of the manuscript and his valuable comments.

REFERENCES

- 1 Aggleton JP, Hunt PR, Rawlins JN (1986). The effects of hippocampal lesions upon spatial and non-spatial tests of working memory. *Behav Brain Res* **19**: 133–146.
- 2 Ates O, Cayli S, Gurses I, Yucel N, Iraz M, Altinoz E, et al (2006). Effect of pinealectomy and melatonin replacement on morphological and biochemical recovery after traumatic brain injury. *Int J Dev Neurosci* **24**: 357–363.
- 3 Barrett P, Bolborea M (2011). Molecular pathways involved in seasonal body weight and reproductive responses governed by melatonin. *J Pineal Res* **52**: 376–388.
- 4 Baydas G, Reiter RJ, Akbulut M, Tuzcu M, Tamer S (2005). Melatonin inhibits neural apoptosis induced by homocysteine in hippocampus of rats via inhibition of cytochrome c translocation and caspase-3 activation and by regulating pro- and anti-apoptotic protein levels. *Neuroscience* **135**: 879–886.
- 5 Costa EJX, Lopez RH, Lamy-Freund MT (1995). Permeability of pure lipid bilayers to melatonin. *J Pineal Res* **19**: 123–126.
- 6 De Butte M, Pappas BA (2007). Pinealectomy causes hippocampal CA1 and CA3 cell loss: reversal by melatonin supplementation. *Neurobiol Aging* **28**: 306–313.
- 7 Delibas N, Tuzmen N, Kilinc I, Altuntas I (2002). Effects of functional pinealectomy on lipid peroxidation and antioxidant enzyme activities in the blood, brain and hippocampus of young and old rats. *Turk J Bioch* **27**: 94–100.
- 8 Dominguez-Alonso A, Ramirez-Rodriguez G, Benitez-King G (2012). Melatonin increases dendritogenesis in the hilus of hippocampal organotypic cultures. *J Pineal Res* **52**: 427–436.
- 9 Erol FS, Topsakal C, Ozveren MF, Kaplan M, Ilhan N, Ozercan IH, et al (2004). Protective effects of melatonin and vitamin E in brain damage due to gamma radiation: an experimental study. *Neurosurg Rev* **27**: 65–69.
- 10 Esterbauer H, Cheeseman KH (1990). Determination of aldehydic lipid peroxidation products: malonaldehyde and 4-hydroxynonenal. *Methods Enzymol* **186**: 407–421.
- 11 Galano A, Tan DX, Reiter RJ (2011). Melatonin as a natural ally against oxidative stress: a physicochemical examination. *J Pineal Res* **51**: 1–16.
- 12 Gonenc S, Uysal N, Acikgoz O, Kayatekin BM, Sonmez A, Kiray M, et al (2005). Effects of melatonin on oxidative stress and spatial memory impairment induced by acute ethanol treatment in rats. *Physiol Res* **54**: 341–348.
- 13 Hoffman RA, Reiter RJ (1965). Rapid pinealectomy in hamsters and other small rodents. *Anat Rec* **153**: 19–21.
- 14 Kabuto H, Yokoi I, Ogawa N (1998). Melatonin inhibits iron-induced epileptic discharges in rats by suppressing peroxidation. *Epilepsia* **39**: 237–243.
- 15 Kus I, Akpolat N, Ozen OA, Songur A, Kavakli A, Sarsilmaz M (2002). Effects of melatonin on Leydig cells in pinealectomized rat: an immunohistochemical study. *Acta Histochem* **104**: 93–97.
- 16 Kus I, Zararsiz I, Ogeturk M, Yilmaz HR (2007). Hippocampal Oxidative Damage Due To Formaldehyde Neurotoxicity and Protective Effect of Melatonin Hormone: An Experimental Study. *Firat Med J* **12**: 256–260.

- 17 Mason RP, Leeds PR, Jacob RF, Hough CJ, Zhang KG, Mason PE, et al (1999). Inhibition of excessive neuronal apoptosis by the calcium antagonist amlodipine and antioxidant in cerebellar granule cells. *J Neurochem* **72**: 1448–1456.
- 18 Mauriz JL, Collado PS, Veneroso C, Reiter RJ, Gonzalez-Gallego J (2013). A review of the molecular aspects of melatonin's anti-inflammatory actions: recent insights and new perspectives. *J Pineal Res* **54**: 1–14.
- 19 Morris RG, Garrud P, Rawlins JN, Keefe O (1982). Place navigation impaired in rats with hippocampal lesions. *Nature* **297**: 681–683.
- 20 Nagata S (1997). Apoptosis by death factor. *Cell* **88**: 355–365.
- 21 Okatani Y, Okamoto K, Hayashi K, Wakatsuki A, Tamura S, Sogara Y (1998). Maternal-fetal transfer of melatonin in pregnant women near term. *J Pineal Res* **25**: 129–134.
- 22 Ozdemir D, Tugyan K, Uysal N, Sonmez U, Sonmez A, Acikgoz O, et al (2005). Protective effect of melatonin against head trauma-induced hippocampal damage and spatial memory deficits in immature rats. *Neurosci Lett* **385**: 234–239.
- 23 Paglia DE, Valentine WN (1967). Studies on the quantitative and qualitative characterisation of erythrocyte glutathione peroxidase. *J Lab Clin Med* **70**: 158–169.
- 24 Paxinos G, Watson C (2007). *The Rat Brain: in Stereotaxic Coordinates*. Elsevier, London.
- 25 Phillips RG, Ledoux JE (1994). Lesions of the dorsal hippocampal formation interfere with background but not foreground contextual fear conditioning. *Learn Mem* **1**: 34–44.
- 26 Reiter R, Tang L, Garcia JJ, Munoz-Hoyos A (1997). Pharmacological actions of melatonin in oxygen radical pathophysiology. *Life Sci* **60**: 2255–2271.
- 27 Reiter RJ, Tan D, Kim SJ, Manchester LC (1999). Augmentation of indices of oxidative damage in life-long melatonin-deficient rats. *Mechanisms of Ageing and Development* **110**: 157–173.
- 28 Reiter RJ, Tan DX, Rosales-Corral S, Manchester LC (2013). The universal nature, unequal distribution and antioxidant functions of melatonin and its derivatives. *Mini Rev Med Chem* **13**: 373–384.
- 29 Shen YX, Xu SY, Wang XL, Wang H (2002). Melatonin blocks rat hippocampal neuronal apoptosis induced by amyloid beta-peptide. *Pineal Res* **32**: 163–167.
- 30 Skaper SD, Floreani M, Ceccon M, Facci L, Giusti P (1999). Excitotoxicity, oxidative stress and the neuroprotective potential of melatonin. *Ann N Y Acad Sci* **890**: 107–118.
- 31 Songur A, Ozen OA, Sarsilmaz M (2001). Hippocampus. *T Klin J Med Sci* **21**: 427–431.
- 32 Sun Y, Oberley LW, Li Y (1988). A simple method for clinical assay of superoxide dismutase. *Clin Chem* **34**: 497–500.
- 33 Tan DX, Manchester LC, Reiter RJ, Qi W, Kim SJ, El-Sokkary GH (1998). Melatonin protects hippocampal neurons in vivo against kainic acid-induced damage in mice. *J Neurosci Res* **54**: 382–389.
- 34 Teyler TJ, Discenna P (1984). The topological anatomy of the hippocampus: a clue to its function. *Brain Res Bull* **12**: 711–719.
- 35 Turgut M, Uyanikgil Y, Ates U, Baka M, Yurtseven ME (2006). Pinelectomy stimulates and exogenous melatonin inhibits harmful effects of epileptiform activity during pregnancy in the hippocampus of newborn rats: an immunohistochemical study. *Childs Nerv Syst* **22**: 481–488.
- 36 Warrington EK, Weiskrantz L (1968) New method of testing long-term retention with special reference to amnesic patients. *Nature* **217**: 972–974.
- 37 Zararsiz I, Kus I, Ogeturk M, Akpolat N, Kose E, Meydan S, et al (2007). Melatonin prevents formaldehyde-induced neurotoxicity in prefrontal cortex of rats: an immunohistochemical and biochemical study. *Cell Biochem Funct* **25**: 413–418.