

See discussions, stats, and author profiles for this publication at: <https://www.researchgate.net/publication/271196057>

# Evaluation of polylactide film for prevention of pericardial adhesion in a rabbit model

Article in Turkish Journal of Thoracic and Cardiovascular Surgery · January 2015

DOI: 10.5606/tgkdc.dergisi.2015.10487

CITATION

1

READS

82

7 authors, including:



**Orcun Gurbuz**

Ceylan International Hospital Bursa

26 PUBLICATIONS 57 CITATIONS

[SEE PROFILE](#)



**Abdulkadir Ercan**

Ceylan International Hospital, Bursa, Turkey

24 PUBLICATIONS 55 CITATIONS

[SEE PROFILE](#)



**Murat Bicer**

Uludag University

25 PUBLICATIONS 68 CITATIONS

[SEE PROFILE](#)



**Gencehan Kumtepe**

Balikesir University

20 PUBLICATIONS 41 CITATIONS

[SEE PROFILE](#)

Some of the authors of this publication are also working on these related projects:



Experimental-Thoracic Surgery [View project](#)



esophagial disease [View project](#)

## Evaluation of polylactide film for prevention of pericardial adhesion in a rabbit model

*Perikardiyal adezyonların önlenmesinde polilaktid bariyerin bir tavşan modelinde değerlendirilmesi*

Orçun Gürbüz,<sup>1</sup> Abdülkadir Ercan,<sup>1</sup> Murat Biçer,<sup>2</sup> Gencehan Kumtepe,<sup>1</sup> Sami Bayram,<sup>3</sup> Işık Şenkaya,<sup>2</sup> Davit Saba<sup>2</sup>

*Institution where the research was done:*  
Medical Faculty of Uludağ University, Bursa, Turkey

*Author Affiliations:*

<sup>1</sup>Department of Cardiovascular Surgery, Medical Faculty of Balıkesir University, Balıkesir, Turkey  
Departments of <sup>2</sup>Cardiovascular Surgery and <sup>3</sup>Thorasic Surgery, Medical Faculty of Uludağ University, Bursa, Turkey

### ABSTRACT

**Background:** This study aims to evaluate the efficacy of a bioabsorbable polylactide film, which was proven to be effective in preventing pelvic adhesions, in prevention of postoperative pericardial adhesions in an animal model.

**Methods:** Forty New Zealand white rabbits were divided equally into control and treatment groups. Subjects were performed left anterior thoracotomy and partial pericardiectomy followed by epicardial abrasion. In control groups (group 1 and 2), the pericardium was left open to allow retrosternal adhesions. In treatment groups (group 3 and 4), the pericardial defect was closed with 0.02 mm bioabsorbable polylactide film. Postoperative macroscopic and microscopic evaluations were made by the same blinded observers at the end of the third week in group 1 and 3, and at the end of the sixth week in group 2 and 4.

**Results:** Macroscopic and histopathologic examinations revealed no significant differences between control and treatment groups in terms of adhesion formation. However, polylactide film supported the growth of a mesothelium-like layer in the treatment groups.

**Conclusion:** Although polylactide film assists in the regeneration of mesothelial cells layer, it does not prevent the development of pericardial adhesions.

**Keywords:** Bioabsorbable polylactide film; cardiac surgery; pericardial adhesions.

### ÖZ

**Amaç:** Bu çalışmada pelvik yapışıklıkları önlemede etkinliği kanıtlanmış biyoemilebilir polilaktid bariyerin ameliyat sonrası perikardiyal yapışıklıkları önlemedeki etkinliği bir hayvan modelinde değerlendirildi.

**Çalışma planı:** Kırk Yeni Zelanda beyaz tavşanı eşit olarak kontrol ve tedavi gruplarına ayrıldı. Deneklere sol anterior torakotomi ve parsiyel perikardiyektomi sonrası epikardiyal abrazyon uygulandı. Kontrol gruplarında (grup 1 ve 2) retrosternal yapışıklıklara izin vermek için perikard açık bırakıldı. Tedavi gruplarında ise (grup 3 ve 4) perikardiyal defekt 0.02 mm biyoemilebilir polilaktid bariyer ile kapatıldı. Ameliyat sonrası makroskopik ve mikroskopik değerlendirmeler gruplar hakkında bilgisi olmayan değerlendirmeciler tarafından grup 1 ve 3'te üçüncü haftanın sonunda, grup 2 ve 4'te ise altıncı haftanın sonunda yapıldı.

**Bulgular:** Makroskopik ve histopatolojik değerlendirmeler kontrol ve tedavi grupları arasında adezyon gelişimi açısından anlamlı farklılık olmadığını gösterdi. Ancak polilaktid bariyer tedavi gruplarında mezotelyum benzeri hücre tabakasının gelişimini destekledi.

**Sonuç:** Polilaktid bariyer mezotel hücre tabakasının rejenerasyonuna yardımcı olsa da perikardiyal yapışıklıkların gelişimini önlemektedir.

**Anahtar sözcükler:** Biyoemilebilir polilaktid bariyer; kalp cerrahisi; perikardiyal yapışıklıklar.



Available online at  
www.tgkdc.dergisi.org  
doi: 10.5606/tgkdc.dergisi.2015.10487  
QR (Quick Response) Code

Received: December 26, 2012 Accepted: March 30, 2013

Correspondence: Orçun Gürbüz, M.D. Balıkesir Üniversitesi Tıp Fakültesi Kalp ve Damar Cerrahisi Anabilim Dalı, 10145 Balıkesir, Turkey.

Tel: +90 266 - 612 10 10 e-mail: gurbuzorcun@gmail.com

The study presented in the 4<sup>th</sup> Congress of Update in Cardiology and Cardiovascular Surgery, 28 November - 2 December 2008

Since the adhesions that develop after cardiac surgery are mostly asymptomatic, research conducted on the prevention of postoperative adhesions has mostly focused on abdominopelvic surgery. However, the number of patients who require a re sternotomy, which causes a higher operative risk, is steadily increasing.<sup>[1]</sup> Accordingly, there has been an increase in the amount of research concerning the prevention of pericardial adhesions since more cardiac reoperations have been performed in the last 15 years.

Mesothelial cells play a key role in adhesion progression and recovery.<sup>[2]</sup> Following tissue damage, the mesothelium releases a fibrinogen-rich exudate that includes chemical and inflammatory mediators, and the conversion of fibrinogen to fibrin through these mediators leads to fibrous adhesions. In addition, it has been reported that fibrinolytic activity is significantly decreased in injured mesothelial cells.<sup>[2-4]</sup> Mesothelial cell migration from undamaged areas occurs in the first 48 hours, and mesothelial recovery is completed within seven days.<sup>[4]</sup> Therefore, methods implemented to prevent adhesion formation have focused on decreasing the inflammatory response, inhibiting the coagulation system, and activating the fibrinolytic system through pharmacological agents or separating adhesive surfaces from each other by using physical barriers during the recovery process. Even though there has been success in animal models,<sup>[5-7]</sup> it is very difficult to keep the pharmacological agents in the correct anatomic region in every day practice due to mediastinal drainage. Consequently, separating the affected surfaces from each other using physical barriers is the most effective method for preventing adhesions.

There are two types of physical barriers: bioabsorbable and non-absorbable. Recent studies have focused on bioabsorbable materials because non-absorbable barriers can cause a long-term foreign body reaction that can lead to an increased risk of infection and fibrosis development that obscures the view of the cardiac anatomy during a reoperation. Successful results have also been reported in animal models with hyaluronic acid-carboxymethylcellulose,<sup>[8-10]</sup> polyvinyl alcohol,<sup>[11]</sup> and collagen membranes,<sup>[12]</sup> as well as fibrin sealant patches.<sup>[13]</sup>

The role of polylactic acid (PLA)-based bioabsorbable membranes in the prevention of abdominal adhesions is widely known. This acid does not interfere with wound recovery and it does not stimulate fibrosis formation. In addition, PLA is metabolized to the water (H<sub>2</sub>O) and carbon dioxide (CO<sub>2</sub>) within weeks and is then discharged through respiration. Furthermore, it does not lose its

effectiveness with the presence of blood and external objects, and it can be manipulated easily and utilized whether suturing takes place or not. Moreover, a few studies have reported on the effectiveness of PLA for preventing pericardial adhesions,<sup>[14,15]</sup> but more research is needed to assess its efficacy in the prevention of postoperative pericardial adhesions.

In this study, we investigated the effect of PLA-based bioabsorbable membranes on pericardial adhesions in a rabbit model at the macroscopic and histopathological level.

## MATERIALS AND METHODS

Forty four-month-old, female, New Zealand-type white rabbits that weighed between 2.5 and 4 kg were used in this study. They were bred in the Uludag University Experimental Animals Central Laboratory and were fed under standard diet conditions. The rabbits were included within the scope of the study as per a decision of the Uludag University Animal Experiments Local Ethics Committee and were divided into four groups consisting of 10 rabbits each. During the research, all of the animals were treated based on the recommendations in the Guide for the Care and Use of Laboratory Animals.

The standard diet was stopped two hours before the surgical procedure, and the animals were only permitted to have water after that point. General anesthesia was provided by an intramuscular injection of 35 mg/kg ketamine (Ketalar®, Eczacibasi Ilac Sanayi ve Ticaret A.S., Luleburgaz, Turkey) and 5 mg/kg xylazine (Rompun®, Bayer Healthcare AG, Leverkusen, Germany). After being anesthetized, the animals were ventilated through a specially-designed Ambu bag with oxygen (O<sub>2</sub>), and skin antisepsis was provided by applying polyvinylpyrrolidone iodine (Batticon, Adeka Ilac Sanayi ve Ticaret A.S., Istanbul, Turkey) after the rabbits were shaved. Under aseptic conditions, the mediastinum was reached by performing a left anterior thoracotomy from the fourth intercostal space followed by an approximately 2 cm<sup>2</sup> pericardiectomy. Abrasion was performed with sterile gauze on the front and lateral surface of the heart. While the pericardium was left open in the control groups (groups 1 and 2), it was closed with a PLA-based membrane in 0.02 mm width (Surgi Wrap™, Macropore Biosurgery, Inc., San Diego, CA, USA) suturing to the pericardium with 6-0 prolene (Ethicon Inc., Cincinnati, OH, USA), in the treatment groups (groups 3 and 4) (Table 1). After placing a Minivac drain into the thoracic cavity, the muscle layer and skin were closed, and respiration continued to be supported by the Ambu bag until

**Table 1. Groups characteristics**

	Control (group 1, n=10)	Control (group 2, n=10)	Treatment (group 3, n=10)	Treatment (group 4, n=10)
Age	4 months	4 months	4 months	4 months
Gender	New Zealand white	New Zealand white	New Zealand white	New Zealand white
Pericardium	Left open	Left open	Closed with PLA film	Closed with PLA film
Follow-up	3 weeks	6 weeks	3 weeks	6 weeks

PLA: Polylactic acid.

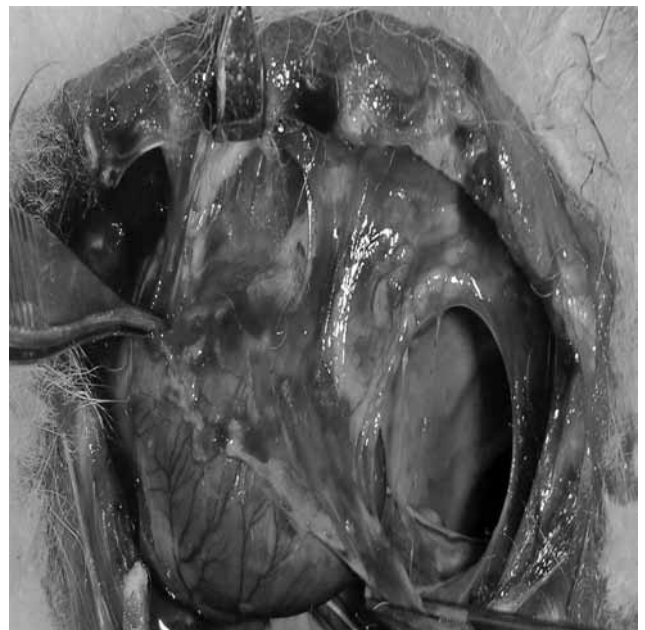the rabbits regained consciousness. Once they were fully awake, the minivac drain was removed, and the animals were closely monitored for almost two hours.

The rabbits were permitted to have a standard diet and were given water postoperatively. However, 500 mg paracetamol tablets (Parol, Atabay İlaç Fabrikası A.S., Istanbul, Turkey) were added to the postoperative food for three days to provide adequate analgesia, and 100 mg/kg ampicillin was given intramuscularly for four days.

The subjects were sacrificed at the end of either three weeks (groups 1 and 3) or six weeks (groups 2 and 4) using the same lethal dose of ketamine and xylazine, and then the mediastinum was reached via a sternotomy. The adhesion level was graded macroscopically by a surgeon who was blinded to the animal groups using the scale described in the study by Heydorn et al.<sup>[16]</sup> (0= no adhesion, 1= adhesion which could be separated easily by finger dissection, 2= intermediate adhesion strength, and 3= adhesion which necessitated sharp dissection) (Figure 1). The heart was removed along with its pericardium, and then the myocardium and epicardium specimens, including the adhesions, were taken. Ten tissue samples were obtained from every heart, and these samples were fixed in standard 10% neutral buffered formalin solution for at least three days.

The tissue samples were then embedded in paraffin blocks using the Shandon Histocentre™ 3 Embedding Center (Thermo Fisher Scientific, Inc., Waltham, MA, USA) and sectioned at 2 microns on the Leica SM2000R sliding microtome (Leica Biosystems GmbH, Wetzlar, Germany). Next, the sections were stained with hematoxylin-eosin (H-E) and examined under a Nikon Eclipse 80i microscope and the Nikon All-in-One Digital Imaging Controller DS-L1 (Nikon Instruments Europe BV, Amsterdam, The Netherlands) at medium zoom (100-400 x plus objective) by the same blinded pathologist in order to examine the inflammation, fibrosis, and mesothelial layer formation.

The scoring schemes of Lu et al.<sup>[17]</sup> were used to grade the inflammation (0= no cell infiltration, 1= sparse infiltration of the neutrophils, lymphocytes, and plasma cells, 2= focal infiltration of the neutrophils, plasma cells, and lymphocytes, 3= diffuse infiltration of the neutrophils, plasma cells, and lymphocytes) and the fibrosis (0= no fibrous reaction, 1= sparse, focal fibrous connective tissue, hyalinization, and fibrin deposition, 2= a thin layer of fibrous connective tissue, hyalinization, and fibrin deposition, 3= a thick layer of fibrous connective tissue, hyalinization, and fibrin deposition). The mesothelial cell layer thickness was graded from 1 to 5 as described by Tsukihara et al.<sup>[18]</sup> in which 1 represented a very thin mesothelial cell layer and 5 signified a mesothelial cell layer with the same thickness as the native pericardium (Figures 2a, b, c, and d).



**Figure 1.** Three weeks after the initial operation, severe pericardial adhesions (grade 3), which necessitated a sharp dissection, were observed between the epicardium and mediastinal tissues in group 1.

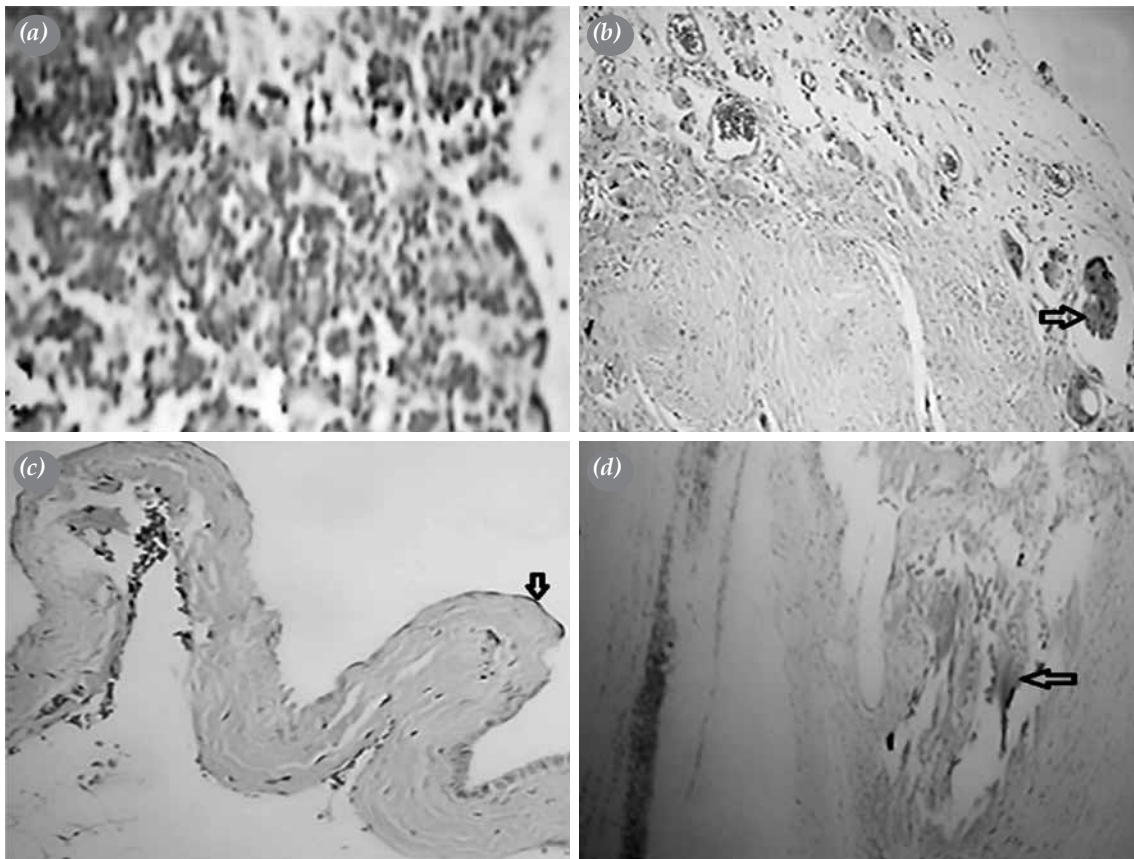
### Statistical analysis

The analysis was performed using SPSS version 15.0 for Windows (SPSS, Inc., Chicago, IL, USA). The values were expressed as mean  $\pm$  standard deviation (SD). The Kruskal-Wallis H test was used to determine the differences among the groups in terms of the macroscopic adhesion, inflammatory reaction, fibrosis, and mesothelial cell thickness scores, and the Mann-Whitney U test was used to compare the differences between two independent groups. The level of significance was set at  $p < 0.05$ .

### RESULTS

After three weeks, it was observed that in groups 1 and 3, the bioabsorbable material was totally

absorbed both macroscopically and microscopically, and there were no significant differences between the control and PLA-based treatment groups regarding the macroscopic adhesion, inflammatory reaction, and fibrosis scores ( $p > 0.05$ ). However, the mesothelial cell thickness scores were statistically significantly higher in treatment group 3 than in control group 1 after three weeks ( $p < 0.001$ ) (Table 2). However, after six weeks, treatment group 4 did not demonstrate statistically significant superiority over control group 2 (Table 3). In addition, the fibrosis scores were statistically significantly lower in PLA-based treatment group 4 at six weeks than in PLA-based treatment group 3 at three weeks ( $p = 0.035$ ) (Table 4).



**Figure 2.** (a) Severe inflammation (grade 3) is shown (diffuse infiltration of neutrophils, plasma cells, and lymphocytes in the epicardium) in a rabbit in the three-week control group (group 1) (H-E x 400). (b) The epicardium from a rabbit at the postoperative sixth week is shown following the use of a 0.02 mm, bioabsorbable, polylactic acid membrane to close the pericardium (group 4). A moderate fibrous connective tissue formation can be seen in the epicardium (grade 2). The arrow indicates mild epicardial hyalinization. (H-E x 400). (c) The black arrow shows the grade 2 mesothelial-like cell proliferation (with 1 being the thinnest and 5 being the same thickness as the pericardium) and the mild fibrous reaction in the epicardium in a rabbit at the postoperative third week following the use of a 0.02 mm, bioabsorbable, polylactic acid membrane to close the pericardium (group 3) (H-E x 100). (d) Severe fibrosis and hyalinization in the epicardium (grade 3) as represented by a thick layer of fibrous connective tissue, the hyalinization, and fibrin deposition is shown in a rabbit in the postoperative six-week control group (group 2). The arrow indicates the hyalinization area (H-E x 200).

**Table 2. Comparison of the control and treatment groups at three weeks**

	Control (group 1, n=10)	Treatment (group 3, n=10)	<i>p</i>
	Mean±SD	Mean±SD	
Macroscopic adhesion score	2.8±0.42	2.0±0.94	0.075
Microscopic scores			
Inflammatory reaction	2±0.67	1.4±0.52	0.075
Fibrosis reaction	2±0.94	2.6±0.52	0.19
Mesothelium-like cell layer	0	1.6±0.84	<0.001*

SD: Standard deviation; \* Statistically significant difference.

In addition, two of the rabbits were lost due to tamponade, one on the seventh postoperative day and the other on the 11<sup>th</sup> postoperative day, so two new rabbits were added to the study. Furthermore, no morbidity was seen in any of the groups.

## DISCUSSION

As a result of an inflammatory response to surgical trauma, adhesions develop between neighboring tissues after all surgical procedures. Postoperative complication rates are approximately twice as high in recurrent coronary bypass operations because of the presence of fibrotic adhesions between the sternum and right ventricle.<sup>[1,19,20]</sup> Moreover, mediastinal adhesions are associated with increased hospital costs due to increased

morbidity rates and prolonged hospital stays.<sup>[1]</sup> One way to prevent adhesions is to separate the affected surface from one another via a physical barrier. Several attempts have been made to reduce the formation of adhesions by using different types of pericardial substitutes to form a barrier between the epicardium and surrounding tissue until mesothelial healing occurs. However, this needs to occur without an increase in the tendency towards infection.<sup>[8,11-15,21-23]</sup> In spite of efforts to find an appropriate barrier, no satisfactory substitute has been found so far.

Polyactic acid-based membranes, which have been approved by the Food and Drug Administration (FDA) for abdominopelvic surgery, have only recently started to be used to prevent the formation of pericardial

**Table 3. Comparison of the control and treatment groups at six weeks**

	Control (group 2, n=10)	Treatment (group 4, n=10)	<i>p</i>
	Mean±SD	Mean±SD	
Macroscopic adhesion score	2.3±0.67	2.2±0.79	1.00
Microscopic scores			
Inflammatory reaction	1.6±1.07	1.2±0.79	0.39
Fibrosis reaction	2.0±1.33	1.6±1.07	0.39
Mesothelium-like cell layer	0.6±0.5	1.0	0.14

SD: Standard deviation.

**Table 4. Comparison between the treatment groups**

	Treatment (group 3, n=10)	Treatment (group 4, n=10)	<i>p</i>
	Mean±SD	Mean±SD	
Macroscopic adhesion score	2.0±0.94	2.2±0.79	0.68
Microscopic scores			
Inflammatory reaction	1.4±0.52	1.2±0.79	0.68
Fibrosis reaction	2.6±0.52	1.6±1.07	0.035*
Mesothelium-like cell layer	1.6±0.84	1.0	0.143

SD: Standard deviation; \* Statistically significant difference.

adhesions.<sup>[14,24]</sup> Following the reports by Okuyama et al.,<sup>[15,22]</sup> Schreiber et al.,<sup>[23]</sup> in a comparative, random, single-center, blinded study, began utilizing PLA-based membranes during the gradual surgery of 13 cases with hypoplastic left heart syndrome in which they reported a decrease in the number of postoperative adhesions at a rate close to statistically significant levels. The FDA then approved other multicenter studies after their findings. In our study, we decided to use a PLA-based, 0.02 mm thick transparent film sheet. Furthermore, we also chose to perform a left thoracotomy over a sternotomy because of the better survival and low morbidity rates that had been reported in several studies conducted on rabbits. Furthermore, we selected a three-week period for our study because this is the timeframe within which most adhesions are observed. For the second evaluation period, six weeks was preferable because it allowed for the opportunity to evaluate long-term adhesion formation. No statistically significant differences were detected among the control and treatment groups in terms of macroscopic adhesion scores. However, when the three-week control and treatment groups were compared, the adhesion scores in treatment group 3 were lower than in control group 1, and like the results of Okuyama et al.,<sup>[15,22]</sup> they were close to statistical significance ( $p=0.075$ ). However, it is possible that our results might have been affected by the thickness of the PLA membrane that was used. Iliopoulos et al.<sup>[14]</sup> used PLA films with various levels of absorption and found that the slowly-absorbed 0.05 mm material was more effective for preventing adhesion formation.

In terms of the inflammatory reaction scores, we detected no statistically significant differences among the control and treatment groups, which might be explained by the fact that bioabsorbable membranes do not prevent the inflammatory response from occurring after tissue damage, which is in contrast to the performance of pharmacological agents, but they separate the injured surfaces until the end of the healing process. In addition, when our fibrosis scores were analyzed, six-week treatment group 4 had markedly lower fibrosis scored than three-week treatment group 3 ( $p=0.035$ ), but this could be related to the fibrinolytic activity because it decreases after injuries and increases over time. In both treatment groups, we observed a mesothelial-like layer on the epicardial surface, lending support to the hypothesis that the PLA membrane forms a skeleton for tissue regeneration during the recovery period. Microscopically, we observed that the 0.02 mm thick PLA-membrane layer was completely absorbed in both the three- and six-week groups, which lends credence

to the findings of Iliopoulos et al.<sup>[14]</sup> in which the PLA was completely bioabsorbed over a four-week period.

Limitations of the hereby study could be noted as minimal epicardial damage, not applying CPB and minimal bleeding. Consequently, results in experimental studies displayed better results than human studies, explaining in relation with the coagulation system activated after CPB.<sup>[25]</sup>

### Conclusion

The 0.02 mm thick PLA-membranes did not prevent pericardial adhesion formation in our study. It appears that developing bioabsorbable barriers which include slow-release pharmacological agents in an effort to prevent postoperative pericardial adhesions would affect all aspects of the problem by decreasing the inflammatory reaction while also serving as a scaffold for mesothelial regeneration. However, further studies are needed to confirm our findings.

### Acknowledgment

We would like to thank Prof. Dr. Omer Yerci at the Uludag University Faculty of Medicine Department of Pathology for his support during the evaluation period of the specimens and Dr. Deniz Singirli at the Uludag University Faculty of Medicine Department of Statistics for her help with the statistical analyses in our study.

### Declaration of conflicting interests

The authors declared no conflicts of interest with respect to the authorship and/or publication of this article.

### Funding

The authors received no financial support for the research and/or authorship of this article.

### REFERENCES

1. Sabik JF 3rd, Blackstone EH, Houghtaling PL, Walts PA, Lytle BW. Is reoperation still a risk factor in coronary artery bypass surgery? *Ann Thorac Surg* 2005;80:1719-27.
2. Yener A, Bardakci Y, İriz E, Özoğul C, Yener N, Bayram H, et al. Intraoperative changes in the pericardium: a study via electron microscope. *Turk Gogus Kalp Dama* 2011;4:576-85.
3. Nkere UU, Whawell SA, Sarraf CE, Schofield JB, Thompson JN, Taylor KM. Perioperative histologic and ultrastructural changes in the pericardium and adhesions. *Ann Thorac Surg* 1994;58:437-44.
4. Cannata A, Petrella D, Russo CF, Bruschi G, Fratto P, Gambacorta M, et al. Postsurgical intrapericardial adhesions: mechanisms of formation and prevention. *Ann Thorac Surg* 2013;95:1818-26.
5. Orhan A, Görmüş N, Toy H, Görmüş IS, Çağlayan O,

- Tanyeli Ö. Prevention of retrosternal pericardial adhesions after cardiac surgery with mitomycin C. *Heart Lung Circ* 2014;23:357-62.
6. Alizzi AM, Summers P, Boon VH, Tantiogco JP, Thompson T, Leslie BJ, et al. Reduction of post-surgical pericardial adhesions using a pig model. *Heart Lung Circ* 2012;21:22-9.
  7. Colak N, Nazli Y, Alpay MF, Aksoy ON, Akkaya IO, Bayrak R, et al. Effect of topical N-acetylcysteine in the prevention of postoperative pericardial adhesion formation in a rabbit model. *Cardiovasc Pathol* 2013;22:368-72.
  8. Naito Y, Shin'oka T, Hibino N, Matsumura G, Kurosawa H. A novel method to reduce pericardial adhesion: a combination technique with hyaluronic acid biocompatible membrane. *J Thorac Cardiovasc Surg* 2008;135:850-6.
  9. Shen J, Xu ZW. Combined application of acellular bovine pericardium and hyaluronic acid in prevention of postoperative pericardial adhesion. *Artif Organs* 2014;38:224-30.
  10. Mueller XM, Tevæarai HT, Augstburger M, Burki M, von Segesser LK. Prevention of pericardial adhesions with a bioresorbable membrane. *Swiss Surg* 1999;5:23-6. [Abstract]
  11. de Oliveira PP, Bavaresco VP, Silveira-Filho LM, Schenka AA, Vilarinho KA, Barbosa de Oliveira Severino ES, et al. Use of a novel polyvinyl alcohol membrane as a pericardial substitute reduces adhesion formation and inflammatory response after cardiac reoperation. *J Thorac Cardiovasc Surg* 2014;147:1405-10.
  12. Bel A, Ricci M, Piquet J, Bruneval P, Perier MC, Gagnieu C, et al. Prevention of postcardiopulmonary bypass pericardial adhesions by a new resorbable collagen membrane. *Interact Cardiovasc Thorac Surg* 2012;14:469-73.
  13. Kuschel TJ, Gruszka A, Hermanns-Sachweh B, Elyakoubi J, Sachweh JS, Vázquez-Jiménez JF, et al. Prevention of postoperative pericardial adhesions with TachoSil. *Ann Thorac Surg* 2013;95:183-8.
  14. Iliopoulos J, Cornwall GB, Evans RO, Manganas C, Thomas KA, Newman DC, et al. Evaluation of a bioabsorbable polylactide film in a large animal model for the reduction of retrosternal adhesions. *J Surg Res* 2004;118:144-53.
  15. Okuyama N, Rodgers KE, Wang CY, Girgis W, Oz M, St Amand K, et al. Prevention of retrosternal adhesion formation in a rabbit model using bioresorbable films of polyethylene glycol and polylactic acid. *J Surg Res* 1998;78:118-22.
  16. Heydorn WH, Daniel JS, Wade CE. A new look at pericardial substitutes. *J Thorac Cardiovasc Surg* 1987;94:291-6.
  17. Lu JH, Chang Y, Sung HW, Chiu YT, Yang PC, Hwang B. Heparinization on pericardial substitutes can reduce adhesion and epicardial inflammation in the dog. *J Thorac Cardiovasc Surg* 1998;115:1111-20.
  18. Tsukihara H, Takamoto S, Kitahori K, Matsuda K, Murakami A, Novick RJ, et al. Prevention of postoperative pericardial adhesions with a novel regenerative collagen sheet. *Ann Thorac Surg* 2006;81:650-7.
  19. Loging JA, New RB, Baicu SC, King MK, Hendrick JW, Crawford FA Jr, et al. Effects of angiotensin type-I receptor blockade on pericardial fibrosis. *J Surg Res* 1999;87:101-7.
  20. Mitchell JD, Lee R, Hodakowski GT, Neya K, Harringer W, Valeri CR, et al. Prevention of postoperative pericardial adhesions with a hyaluronic acid coating solution. Experimental safety and efficacy studies. *J Thorac Cardiovasc Surg* 1994;107:1481-8.
  21. Krause TJ, Zazanis G, Malatesta P, Solina A. Prevention of pericardial adhesions with N-O carbonylmethylchitosan in the rabbit model. *J Invest Surg* 2001;14:93-7.
  22. Okuyama N, Wang CY, Rose EA, Rodgers KE, Pines E, diZerega GS, et al. Reduction of retrosternal and pericardial adhesions with rapidly resorbable polymer films. *Ann Thorac Surg* 1999;68:913-8.
  23. Schreiber C, Boening A, Kostolny M, Pines E, Cremer J, Lange R, et al. European clinical experience with REPEL-CV. *Expert Rev Med Devices* 2007;4:291-5.
  24. Sakuma K, Iguchi A, Ikada Y, Tabayashi K. Closure of the pericardium using synthetic bioabsorbable polymers. *Ann Thorac Surg* 2005;80:1835-40.
  25. Gabbay S, Guindy AM, Andrews JF, Amato JJ, Seaver P, Khan MY. New outlook on pericardial substitution after open heart operations. *Ann Thorac Surg* 1989;48:803-12.