

# The Effect of a Special Amino Acid Mixture on Healing of Left Colonic Anastomosis: an Experimental Study

## Özel Amino Asit Karışımının Sol Kolon Anastomozunun İyileşmesindeki Etkisi: Deneysel Çalışma

İsmail YAMAN,<sup>a</sup>  
Cemal KARA,<sup>b</sup>  
Hayrullah DERİCİ,<sup>a</sup>  
Güliden DİNİZ,<sup>c</sup>  
Ragıp ORTAÇ,<sup>c</sup>  
Beyhan Cengiz ÖZYURT<sup>d</sup>

<sup>a</sup>Department of General Surgery,  
Balıkesir University Faculty of Medicine,  
Balıkesir

<sup>b</sup>Clinic of General Surgery,  
İzmir Karşıyaka State Hospital,

<sup>c</sup>Clinic of Pathology,

Dr. Behçet Uz Children's Hospital, İzmir

<sup>d</sup>Department of Public Health,  
Celal Bayar University Faculty of Medicine,  
Manisa

Geliş Tarihi/Received: 11.05.2012

Kabul Tarihi/Accepted: 19.11.2012

Yazışma Adresi/Correspondence:

İsmail YAMAN

Balıkesir University Faculty of Medicine,  
Department of General Surgery, Balıkesir,  
TÜRKİYE/TURKEY

ismailyaman35@gmail.com

**ABSTRACT Objective:** Arginine, glutamine, and Beta-hydroxy-beta-methylbutyrate were combined in a dietary supplement. This specialized amino acid mixture enhances wound collagen accumulation and increases wound healing. We aimed to investigate the effects of this special amino acid mixture on the healing process of experimental left colonic anastomosis. **Material and Methods:** The study included 20 adult male Wistar-Albino rats. The study group (n=10) received 685 mg/kg/day specialized amino acid mixture for 7 days until 12 h before surgery and was maintained throughout the study. Following midline laparotomy a 1-cm segment of the left colon was resected. Bowel continuity was restored with an end-to-end anastomosis. The animals were re-anesthetized on day 7 after the operation and anastomotic bursting pressure was measured by passing a catheter per anum up to the area of anastomosis. Anastomotic segments were removed en bloc and were vertically divided into two. One was used for hydroxyproline measurement and the other for histopathological examination. Abramov's histologic scoring system was used in this study. **Results:** The hydroxyproline levels and bursting pressures in the study group were superior compared to the control group. Collagen deposition and reepithelization scores of the study group were higher than that of the control group. **Conclusion:** Results of the present study indicates that significantly enhancing the anastomotic bursting pressure, hydroxyproline level and collagen deposition may improve anastomosis healing.

**Key Words:** Colorectal surgery; arginine; glutamine; beta-hydroxyisovaleric acid

**ÖZET Amaç:** Arjinin, glutamin ve beta-hidroksi-beta-metilbütirat, diyet desteği olarak kombine edilmiştir. Bu özel amino asit karışımı, yara yerinde kollajen birikimini artırır ve yara iyileşmesini geliştirir. Bu çalışmanın amacı, deneysel sol kolon anastomozunun iyileşmesinde özel amino asit karışımının etkilerini araştırmaktır. **Gereç ve Yöntemler:** Çalışmada 20 adet yetişkin Wistar-Albino sıçan kullanıldı. Çalışma grubu (n=10) ameliyattan 7 gün öncesinden başlayarak tüm çalışma süresince 685 mg/kg/gün özel amino asit karışımı aldı. Orta hattan karın açıldı ve 1 cm'lik sol kolon segmenti rezekt edildi. Uç-uç anastomoz yapılarak barsak lümeninin devamlılığı sağlandı. Sıçanlara bu ameliyattan 7 gün sonra tekrar anestezi verildi. Anastomoz patlama basıncı, anüsten yerleştirilip anastomozun üzerine çıkan bir kateter ile ölçüldü. Anastomoz sahaları sağlam sınırlarla çıkarıldı ve dikey olarak iki parçaya bölündü. Bir parça hidroksiprolin ölçümünde, diğer parça histolojik değerlendirmede kullanıldı. Histolojik değerlendirme için Abramov'un skorlama sistemi kullanıldı. **Bulgular:** Hiroksiprolin düzeyleri ve patlama basınçları çalışma grubunda, kontrol grubuna göre daha yüksekti. Kollajen birikimi ve reepitelizasyon skorları çalışma grubunda daha belirgindi. **Sonuç:** Bu çalışmanın sonuçları, özel amino asit karışımının, anastomoz patlama basıncı, hidroksiprolin düzeyi ve kollajen birikimini artırarak anastomoz iyileşmesinde yararlı olabileceğini göstermiştir.

**Anahtar Kelimeler:** Kolorektal cerrahi; arjinin; glutamin; beta-hidroksivalerik asit

doi: 10.5336/medsci.2012-30385

Copyright © 2013 by Türkiye Klinikleri

Türkiye Klinikleri J Med Sci 2013;33(3):678-84

Anastomotic leakage (AL) is one of the most serious surgical complications after colorectal surgery. Although many local and systemic factors affecting anastomotic healing have been determined, AL is still a serious problem that significantly increases morbidity and mortality rates.<sup>1</sup> The prevalence of AL varies in the literature between 0.5% and 30%.<sup>2,3</sup> Therefore, research has focused on various systemically or locally applied materials that can improve anastomotic healing.<sup>1-3</sup>

Arginine (ARG) is a dietary semi essential amino acid that becomes conditionally indispensable in trauma and surgical patients.<sup>4,5</sup> Dietary ARG supplementation induces positive nitrogen balance, increases hydroxyproline (HP) content, wound collagen accumulation, shows antioxidative effect and enhances wound healing.<sup>4-7</sup> Glutamine (GLU) is a preferred energy source for cells of the intestinal mucosa and of the immune system; furthermore GLU and ARG have immune stimulatory effects.<sup>5,8</sup> GLU is the most abundant amino acid, but its concentration falls after injury, surgery, or infection.<sup>3</sup> In various experimental and clinical studies, GLU had a positive effect on both wound and anastomotic healing.<sup>9,10</sup> Beta-hydroxy-beta-methylbutyrate (HMB) is a metabolite of the essential amino acid leucine.<sup>4</sup> It reduces muscle proteolysis, improves nitrogen balance and wound collagen deposition.<sup>4,7,11</sup> ARG, GLU and HMB have been combined in a dietary supplement specifically designed for patients with catabolic diseases.<sup>7</sup> Williams et al.<sup>4</sup> reported that this special amino acid mixture enhanced wound collagen accumulation and increased wound healing. With these findings in mind, we aimed to examine the therapeutic efficacy of the special amino acid supplement on the healing process of experimental left colonic anastomosis by measuring HP level, bursting pressure (BP) and inflammatory changes in anastomosis.

## MATERIAL AND METHODS

The study included 20 adult male 5-month-old Wistar-Albino rats weighing between 250 and 300 g. The procedures were run at the Ege University Faculty of Medicine animal research laboratory. All animals were housed in cages under standard con-

ditions (room temperature 22°-24°C, 12-hour light/dark cycle). All experimental manipulations and postoperative care were undertaken in accordance with the National Institutes of Health Guide for the Care and Use of Laboratory Animals. The study was also approved by the Animal Ethics Committee of the Balikesir University Medical School. The rats were fed on standard laboratory diet and water ad libitum and had free access to water and standard rat chow until 12 h before surgery. Twenty rats were randomized into two groups of 10 each. The study group (SG, n=10) received 685 mg/kg/day specialized amino acid mixture (Abound® Abbott, İstanbul, Turkey) dissolved in 1ml water per day for 7 days until 12 h before the surgery and was maintained throughout the study while the control group (CG, n=10) received the same amount of saline orally with orogastric tube.

## OPERATION PROCEDURE

Each rat was anesthetized with intramuscular injection of ketamin hydrochloride (Ketalar, Eczacıbası, Warner-Lambert Laboratories, Levent, İstanbul, Turkey) 60 mg/kg and xylazine hydrochloride (Rompun, Bayer Laboratories, Şişli, İstanbul, Turkey) 10 mg/kg. All procedures were performed under sterile conditions. All animals were allowed to breathe spontaneously during the experiments. After the abdominal wall was shaved and was disinfected with a 10% solution of povidone-iodine, a 3-cm midline laparotomy was made. Body temperature was maintained between 36° and 38°C using a heating lamp. The intestines were covered with sterile gauze pads soaked with saline at 37°C to minimize evaporation from the tissue. A 1-cm segment of the left colon was resected approximately 3 cm proximal to the peritoneal reflection. Bowel continuity was restored with an end-to-end anastomosis of nine or ten interrupted sutures (6/0 monofilament polypropylene, Ethicon, UK). The abdominal fascia and skin were closed in a continuous fashion with running 3/0 silk sutures. One operator performed all procedures. Five ml saline solution was given subcutaneously to prevent dehydration in the animals during the experimental period. Animals were fed with standard rat chow and water starting at six hours after the laparotomy.

The animals in each group were re-anesthetized on day seven after the operation for *in vivo* analytic procedures. After relaparotomy, the abdomen and anastomoses were examined macroscopically. Wound complications, intestinal obstructions, anastomotic complications (macroscopic abscess, and dehiscence), and abscess formation were recorded. Intestinal obstruction was recorded as present when the diameter of the segment proximal to the anastomosis was twice the diameter of the segment distal to the anastomosis.

### BURSTING PRESSURE MEASUREMENT

Seven days after the surgery, the animals underwent re-laparotomy to determine the *in vivo* BP prior to death (by cardiac puncture) without detaching adhesions. Anastomotic BP was measured by passing a catheter per anum up to the area of anastomosis. Fecal content of the bowel was cleared by gentle washout with saline. Without disturbing the adhesions, the bowel (2 cm above and below the anastomosis) was tied with a 0 silk ligature. The distal catheter was connected via a pressure transducer to the recorder (Abbott, Monitoring Kit, Ireland). The bowel was infused with a continuous flow of physiological saline (5 ml/min). BP (mmHg) was recorded as the highest figure reached before evident saline leakage or sudden loss of pressure. It was measured by two surgeons blind to the group assignment.

After sacrifice, anastomotic segments, approximately 4 cm in length with the suture line in the middle, were carefully removed en bloc with adhered tissues and were vertically divided into two. One was used for HP measurement and the other was placed in 10% formaline for histopathological examination. All representative anastomotic segment sections in each rat were examined histologically under a light microscope by two pathologists in blinded fashion.

### MEASURING HYDROXYPROLINE

Another 2×1-cm portion of the sample, including the anastomotic segment in the middle, was frozen in liquid nitrogen and was stored at -80°C for further biochemical analysis. After the samples had been thawed, dried, weighed, and homogenized

separately, the HP levels were determined according to the method of Prochop and Kivirikko as mg/100 g of tissue.<sup>12</sup>

### HISTOLOGIC GRADING

Biopsy specimens from each anastomotic segment wounds were obtained as described above. The samples were immediately fixed in formalin, embedded in paraffin, sectioned, and stained with hematoxylin & eosin and Gomori's trichrome stains and were examined under ×100- ×400 magnification. The main histologic outcome measures included the amount of acute and chronic inflammatory infiltrates, the amount and maturation of granulation tissue, collagen deposition, reepithelialization, and neovascularization. Acute inflammation was defined as the presence of neutrophils, while chronic inflammation was defined as the presence of plasma and monocytic cells. We used the Abramov's histologic scoring system<sup>13</sup> for this study. Abramov's system assessed each parameter independently and scored it from 0-3. Acute and chronic inflammatory infiltrates, the amount of granulation tissue and collagen deposition were graded as: 0 (none), 1 (scant), 2 (moderate), 3 (abundant). The maturation of granulation tissue was graded as: 0 (immature), 1 (mild maturation), 2 (moderate maturation), 3 (fully matured). Reepithelialization was graded as: 0 (none), 1 (partial), 2 (complete but immature or thin), 3 (complete and mature). Neovascularization was graded as: 0 (none), 1 [up to five vessels per high-power field (HPF)], 2 (6-10 vessels per HPF), 3 (more than 10 vessels per HPF).<sup>12</sup>

### STATISTICAL ANALYSIS

The results were expressed as median (min-max). Comparisons between two groups were performed using the Mann-Whitney U and Fisher exact test. Differences were considered statistically significant when  $p < 0.05$ .

## RESULTS

A rat in SG died one hour after the surgery due to anesthesia complication. Another rat in CG died on day three after the surgery due to peritoneal sepsis. These two rats were excluded from any further

analysis. The remaining 18 rats (SG=9, CG=9) survived the surgical procedures with no complications (wound infection, anastomotic dehiscence, intraabdominal abscesses, and intestinal obstruction) during the study. The mean values of HP levels and BPs of the anastomotic segments for both groups and the statistical comparisons of the groups were shown in Table 1. The HP levels, and BPs in SG were superior compared to the the CG, and the difference was statistically significant ( $p < 0.001$ , Figure 1, 2 respectively).

Collagen deposition and reepithelization scores of the SG were higher than that of the CG ( $p = 0.029$ , collagen deposition: Figure 3). There was no significant difference between the two groups in terms of acute inflammation, chronic inflammation, the amount of granulation tissue, fibroblast maturation and neovascularization ( $p = 0.637$ ,  $p = 1.000$ ,  $p = 1.000$ ,  $p = 1.000$  and  $p = 1.000$  respectively). Histological comparisons of SG and CG for anastomotic segments were shown in Table 2.

## DISCUSSION

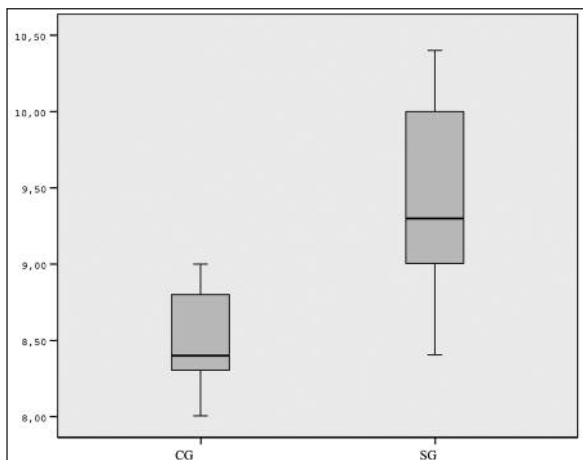
Although preoperative preparation and surgical techniques have improved significantly, leakage of colonic anastomoses is still a serious problem in surgery and causes increased mortality and morbidity.<sup>1,2</sup> Anastomotic colon healing is affected by many local and systemic factors. Materials such as GLU, short-chain fatty acids, erythropoietin, fibrin glue and peritoneal graft have been experimentally reported to be beneficial in the healing of colonic anastomoses.<sup>1-3,10,14,15</sup>

ARG is a dietary semi-essential amino acid and it is metabolized to ornithine and subsequently to proline and polyamines both known to interact in collagen synthesis.<sup>4,16</sup> Dietary ARG supplementation increases wound collagen accumulation.<sup>4,17</sup> GLU is a preferred energy source for cells of the intestinal mucosa.<sup>8</sup> It has the potential to stimulate wound healing, because one of the products of GLU metabolism is proline.<sup>3</sup> GLU enhances gut mucosal

**TABLE 1:** Comparison of tissue hydroxyproline levels (mg/100 gr tissue) and bursting pressures (mmHg) of the colon anastomosis between two groups.

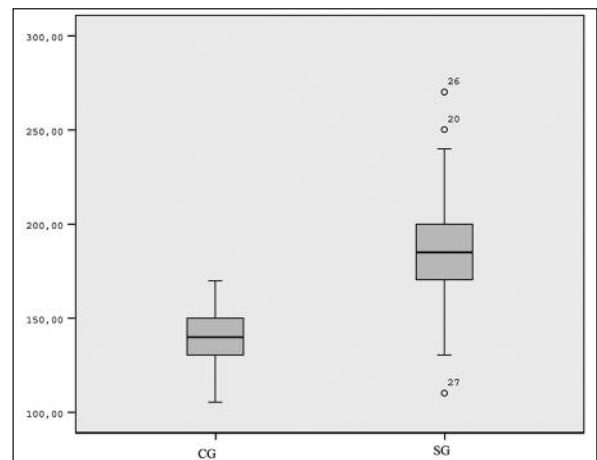
Scores	CG Median (min-max)	SG Median (min-max)	p
Hydroxyproline levels	8.4 (8.0-9.0)	9.3 (8.4-10.4)	<0.001
Bursting pressures	140.0 (105.0-170.0)	185.0 (110.0-270.0)	<0.001

CG: Control groups, SG: Study groups



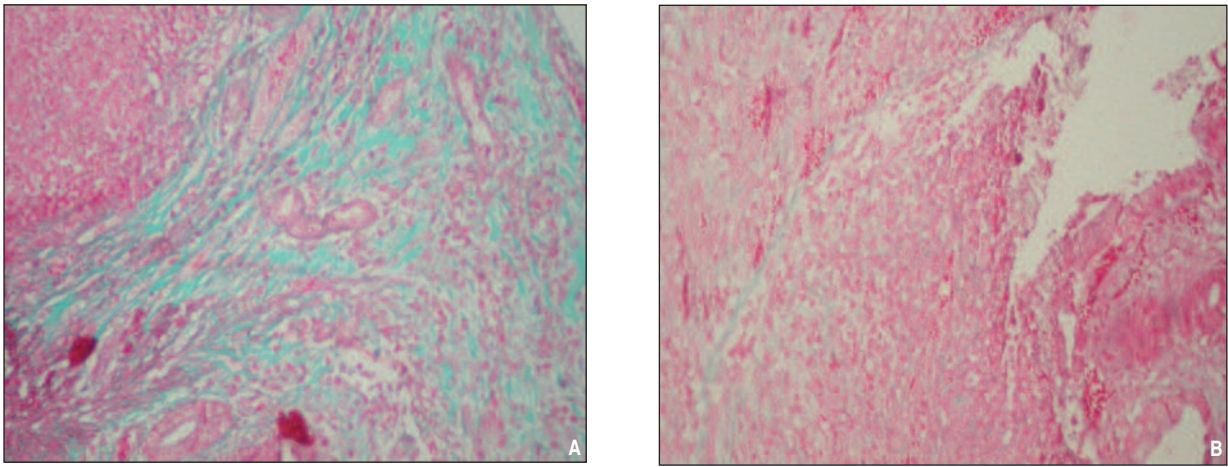
**FIGURE 1:** Comparison of tissue hydroxyproline levels (mg/100 gr tissue) of the colon anastomosis between two groups.

CG: Control groups; SG: Study group; HP: Hydroxyproline.



**FIGURE 2:** Comparison of bursting pressures (mmHg) of the colon anastomosis between two groups.

CG: Control groups; SG: Study group; BP: Bursting pressure.



**FIGURE 3:** Histologic picture of SG (A) and CG (B): prominent collagen deposition (A: score 3 out of 3; B: score 2 out of 3, Gomori's trichrom X100). (See color figure at <http://tipbilimleri.turkiyeklinikleri.com/>)

**TABLE 2:** Comparison of acute inflammation, chronic inflammation, the amounts of granulation tissue, fibroblast maturation, collagen deposition, reepithelization, neovascularization scores between two groups.

Scores		CG (n%)	SG (n%)	p
Acute inflammation	Scant	3 (33.3%)	5 (55.6%)	0.637
	Moderate-abundant	6 (66.7%)	4 (44.4%)	
Chronic inflammation	None-Scant	8 (88.9%)	8 (88.9%)	1.000
	Moderate	1 (11.1%)	1 (11.1%)	
The amounts of granulation tissue	Scant	4 (44.4%)	3 (33.3%)	1.000
	Moderate	5 (55.6%)	6 (66.7%)	
Fibroblast maturation	Immature-Mild	8 (88.9%)	7 (77.8%)	1.000
	Moderate	1 (11.1%)	2 (22.2%)	
Collagen deposition	Scant	5 (55.6%)	0 (0%)	<b>0.029</b>
	Moderate-abundant	4 (44.4%)	9 (100.0%)	
Reepithelization	None-Partial	4 (44.4%)	9 (100.0%)	<b>0.029</b>
	Complete immature-mature	5 (55.6%)	0 (0.0%)	
Neovascularization	< 5/HPF	8 (88.9%)	9 (100%)	1.000
	6-10/HPF	1 (11.1%)	0 (0%)	

CG: Control groups; HPF: High-power field; SG: Study groups.

growth, repair, and improves intestinal injuries of animals and humans.<sup>3</sup> Postoperative GLU-enriched diet was shown to improve wound healing in rats.<sup>18</sup> HMB is the bioactive metabolite of the essential amino acid leucine.<sup>4</sup> HMB inhibits muscle proteolysis, and enhances wound collagen deposition.<sup>4</sup> Specialized amino acid mixture was reported to enhance wound collagen accumulation and increase wound repair.<sup>4</sup> To our knowledge, there is no study that has investigated the effect of special amino acid mixture supplementation on the healing of

colonic anastomosis. We hypothesized that special amino acid mixture might improve the healing of colonic anastomosis.

Anastomotic BP and HP levels have been widely used to assess the intrinsic resistance of anastomoses to rupture.<sup>19</sup> Collagen is important in all phases of wound healing and critical for the return of tissue integrity and strength.<sup>20-22</sup> Between the fifth and seventh days after surgery, collagen synthesis peaks and the wound strength depends mainly on these newly formed, organized collagen

fibers.<sup>3</sup> Thus, postoperative day seen was chosen to evaluate the anastomotic wound healing in our study. There is no study that has investigated the dose of special amino acid mixture supplementation in rats. Williams et al.<sup>4</sup> reported the use of 14 g ARG, 3 g HMB, and 14 g GLU in humans. This dose equals to 685 mg/kg/day of special amino acid mixture. Therefore, we based the doses 685 mg/kg/day in our study on this trial in humans. We used the Abramov's histologic scoring system<sup>13</sup> for this study. Correlating this scoring system with objective measures, such as HP level for collagen deposition, polarized light microscopy for assessment of granulation tissue maturation, and immunohistochemistry for characterization of inflammatory cells were all beyond the scope of this study. In our study, the investigated outcome measures were gross anastomotic healing, BP, HP level, and parameters of histopathological healing. HP levels were significantly higher in SG. Barbul et al.<sup>17</sup> also reported that injured rodents given a perioperative dietary supplementation of ARG had significantly improved wound healing, as assessed by wound breaking strength and the HP content. BPs, fibroblast maturation and collagen deposition scores were significantly higher in SG. Da Costa et al.<sup>23</sup>

studied the effects of oral GLU supplementation on the healing of colonic anastomosis in rats and they also reported improvement in BP and increased mature collagen in the GLU group. Rolandelli et al.<sup>24</sup> investigated the effects of butyrate infusion on the healing of colonic anastomosis in rats and the authors observed improvement of BP in the butyrate group. Williams et al.<sup>4</sup> also reported that healthy elderly volunteers given a dietary supplementation of specialized amino acid mixture accumulated 67% more collagen, as assessed by the HP content and had significantly improved wound healing. It seems that high HP levels, and collagen deposition strengthens the anastomosis mechanically, resulting in increased BP of the anastomosis.

## CONCLUSION

In conclusion, our findings show that special amino acid mixture can be used as a supporting factor for the healing of colonic anastomosis. Results of the present study indicates that it could improve anastomosis healing by significantly enhancing the anastomotic BP, HP level and collagen deposition. Further clinical studies are needed to clarify the usefulness of special amino acid mixture for healing of colonic anastomosis.

## REFERENCES

- Uludag M, Citgez B, Ozkaya O, Yetkin G, Ozcan O, Polat N, et al. Effects of amniotic membrane on the healing of normal and high-risk colonic anastomoses in rats. *Int J Colorectal Dis* 2009;24(7):809-17.
- Irkocurcu O, Comert M. Effects of intraperitoneal sildenafil administration on healing of left colonic anastomoses and intra-abdominal adhesion formation in the presence of intra-abdominal infection. *Dis Colon Rectum* 2009; 52(5):1026-7.
- Girgin S, Gedik E, Ozturk H, Akpolat V, Akbulut V, Kale E, et al. Effects of combined pulse electromagnetic field stimulation plus glutamine on the healing of colonic anastomosis in rats. *Dig Dis Sci* 2009;54(4):745-50.
- Williams JZ, Abumrad N, Barbul A. Effect of a specialized amino acid mixture on human collagen deposition. *Ann Surg* 2002;236(3):369-75.
- May PE, Barber A, D'Olimpio JT, Hourihane A, Abumrad NN. Reversal of cancer-related wasting using oral supplementation with a combination of  $\beta$ -hydroxy- $\beta$ -methylbutyrate, arginine, and glutamine. *Am J Surg* 2002; 183(4):471-9.
- Ozdemir G, Inanç Tolun F, Imrek S. The effect of L-NAME treatment on leptin associated retinal nitrosylation in hypercarbic oxygen induced retinopathy in newborn rats. *Turkiye Klinikleri J Med Sci* 2011;31(4):780-4.
- Marcora S, Lemmey A, Maddison P. Dietary treatment of rheumatoid cachexia with  $\beta$ -hydroxy- $\beta$ -methylbutyrate, glutamine and arginine: a randomised controlled trial. *Clinical Nutrition* 2005;24(3):442-54.
- De-Souza DA, Greene LJ. Pharmacological nutrition after burn injury. *J Nutr* 1998;128(5): 797-803.
- Jian ZM, Cao JD, Zhu XG, Zhao WX, Yu JC, Ma EL, et al. The impact of alanyl-glutamine on clinical safety, nitrogen balance, intestinal permeability, and clinical outcome in postoperative patients: a randomized, doubleblind, controlled study of 120 patients. *JPEN J Parenter Enteral Nutr* 1999;23(5 Suppl):62-6.
- Guven A, Pehlivan M, Gokpinar I, Gurleyik E, Cam M. Early glutamine-enriched enteral feeding facilitates colonic anastomosis healing: light microscopic and immunohistochemical evaluation. *Acta Histochem* 2007;109(2):122-9.
- Clements RH, Saraf N, Kakade M, Yellumhanthi K, White M, Hackett JA. Nutritional effect of oral supplement enriched in beta-hydroxybeta-methylbutyrate, glutamine and arginine on resting metabolic rate after laparoscopic gastric bypass. *Surg Endosc* 2011; 25(5):1376-82.
- Prockop DJ, Kivirikko KI. Relationship of hydroxyproline excretion in urine to collagen metabolism. *Ann Intern Med* 1967;66(6):1243-66.
- Abramov Y, Golden B, Sullivan M, Botros SM, Miller JJ, Alshahrour A, et al. Histologic characterization of vaginal vs. abdominal surgical wound healing in a rabbit model. *Wound Repair Regen* 2007;15(1):80-6.

14. Topçu O, Karadayı K, Kuzu MA, Ulukent S, Erkek B, Alacayır I. Enteral and intraluminal short-chain fatty acids improves ischemic left colonic anastomotic healing in the rat. *Int J Colorectal Dis* 2002;17(3):171-6.
15. Giuratrabocchetta S, Rinaldi M, Cuccia F, Lemma M, Piscitelli D, Polidoro P, et al. Protection of intestinal anastomosis with biological glues: an experimental randomized controlled trial. *Tech Coloproctol*. 2011;15(2):153-8.
16. Witte MB, Vogt N, Stuelten C, Gotoh T, Mori M, Becker HD. Arginase acts as an alternative pathway of L-arginine metabolism in experimental colon anastomosis. *J Gastrointest Surg* 2003;7(3):378-85.
17. Barbul A, Rettura G, Levenson SM, Seifter E. Arginine: a thymotropic and wound-healing promoting agent. *Surg Forum* 1977;28:101-3.
18. Tekin E, Taneri F, Ersoy E, Oguz M, Eser E, Tekin I, et al. The effects of glutamine-enriched feeding on incisional healing in rats. *Eur J Plast Surg* 2000;23(2):78-81.
19. Dinc S, Ozbirecikli B, Gulcelik MA, Erdem E, Korukoglu B, Alagol H. [The effects of intraoperative radiation on the bowel anastomosis in rats]. *Turkiye Klinikleri J Med Sci* 2002; 22(2):148-51.
20. Aytakin FO, Teke Z, Aydin C, Kabay B, Yenisey C, Sacar S, et al. Effects of a membranepermeable radical scavenger, tempol, on healing of colonic anastomoses in the cecal ligation and pucture model of polymicrobial sepsis in rats. *Am Surg* 2007;193(6): 723-9.
21. Colak T, Nayci A, Polat G, Polat A, Comelekoglu U, Kanik A, et al. Effects of trypsin on the healing of colonic anastomoses in an experimental rat model. *ANZ J Surg* 2003; 73(11):916-21.
22. Gunal O, Ghandouri S, Aslaner A. The effect of intrarectal paclitaxel lavage on the healing of rectal anastomosis: a comparison with povidone iodine. *Turkiye Klinikleri J Med Sci* 2005;25(5):653-7.
23. da Costa MA, Campos AC, Coelho JC, de Barros AM, Matsumoto HM. Oral glutamine and the healing of colonic anastomoses in rats. *JPEN J Parenter Enteral Nutr* 2003;27(3): 182-5.
24. Rolandelli RH, Buckmire MA, Bernstein KA. Intravenous butyrate and healing of colonic anastomoses in the rat. *Dis Colon Rectum* 1997;40(1):67-70.

Reproduced with permission of the copyright owner. Further reproduction prohibited without permission.