

Acute Suppurative Thyroiditis Accompanied by Thyrotoxicosis after Fine-Needle Aspiration: Treatment with Catheter Drainage

MURAT YILDAR¹, GULEN DEMIRPOLAT², MEHTAP AYDIN³

ABSTRACT

Fine needle aspiration (FNA) biopsy is commonly used in the diagnosis of thyroid diseases. Serious complications are rare and this procedure is generally safe. Acute suppurative thyroiditis (AST) after FNA has been seldomly reported. We report a case of a 57-year-old woman with diabetes mellitus who developed AST with thyrotoxicosis after FNA. She was successfully treated by sonographically guided percutaneous drainage and antithyroid agent.

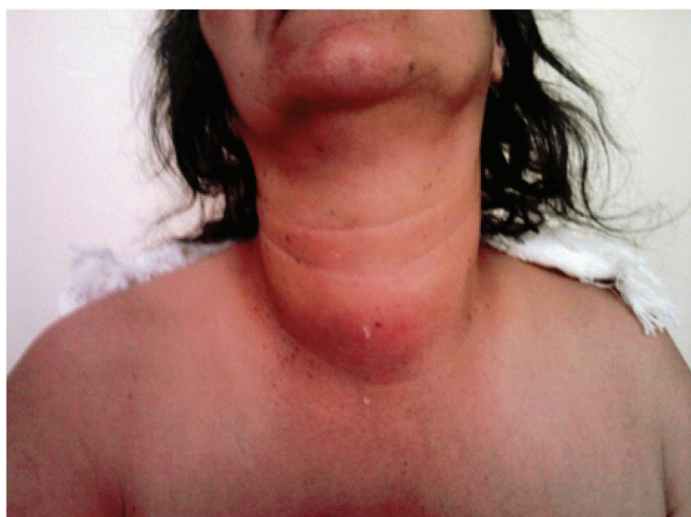Keywords: Abscess, FNA, Thyroiditis, Thyrotoxicosis

CASE REPORT

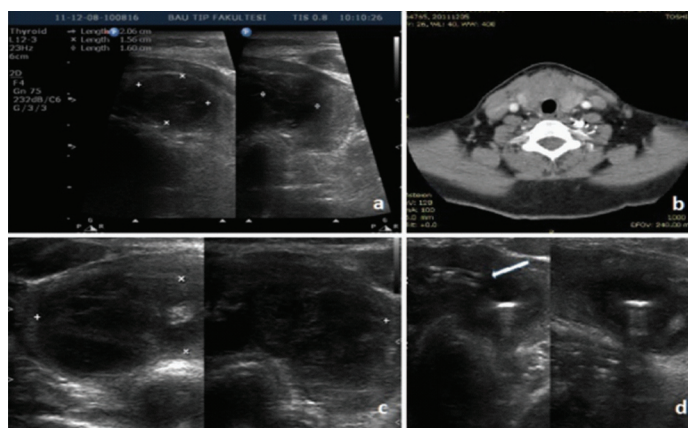
A 57-year-old female patient with symptoms of painful swelling in the neck, high fever, dyspnea and dysphagia that had appeared and worsened two days ago arrived at our clinic [Table/Fig-1]. Anamnesis revealed that thyroid nodule biopsy had been performed 15 days ago. Vital signs are temperature 39°C, blood pressure 100/70 mmHg, pulse 106/min. Examination revealed hoarseness with mild stridor and mild midline swelling and acute sensitivity in the neck above the thyroid gland. Ultrasound examination revealed an ill-defined hypoechoic area with central macroscopic cystic spaces, 2.0 x 1.5 x 1.6 cm in size at the junction of the thyroid isthmus and left lobe [Table/Fig-2a]. Cervical computerized tomography (CT) revealed a hypodense area in the thyroid isthmus [Table/Fig-2b]. The patient had a leukocytosis and elevated CRP levels. Abscess drainage with a 20 gauge needle accompanied by ultrasound was performed in three consecutive times, once a day. The aspirated material was brown and particulate. Thyroid abscess was diagnosed, and intravenous 1.5 g ampicillin sulbactam (1,000 mg ampicillin and 500 mg sulbactam, Duocid 1 g IV, Pfizer Inc., Istanbul, Turkey) four times daily was started. Methicillin-sensitive *Staphylococcus aureus* grew in abscess culture. No malignancy was determined at pathological examination of the abscess material. HbA1c at 6.88%

(Range: 4.80-5.90) and elevated blood sugar were determined, and insulin therapy was started. Thyrotoxicosis began developing on the 7th day of treatment. Tc 99m pertechnetate thyroid scintigraphy revealed a hypoactive nodule and increased activity in the tissue in which exception of the nodule. Propylthiouracil 150 mg/day (3 times a day) and propranolol 80 mg/day (twice daily) p.o. were started. Following 14-day parenteral antibiotherapy, clinical and ultrasound abscess findings completely resolved. Thyrotoxicosis began to improve, and the patient was discharged with ampicillin-sulbactam (750 mg) given orally twice daily, and antithyroid therapy on the 14th day of treatment.

At check-up on the 12th day after treatment, ultrasound examination revealed a hypo-anechogenic internal structure containing fine linear echogenic striations approximately 52x25 mm in size and heterogeneous echogenicity surrounding both lobes around the nodule on which FNA biopsy had been performed inside the thyroid gland [Table/Fig-2c]. Drainage was performed with a 6F percutaneous pigtail abscess drainage catheter [Table/Fig-2d]. The material removed was yellow, thick and non-odorous. Temperature, leukocytosis and CRP were normal. The patient's laboratory findings are shown in [Table/Fig-3]. No bacteria were observed at Gram-staining of the abscess material. There was no growth in aerobic and anaerobic



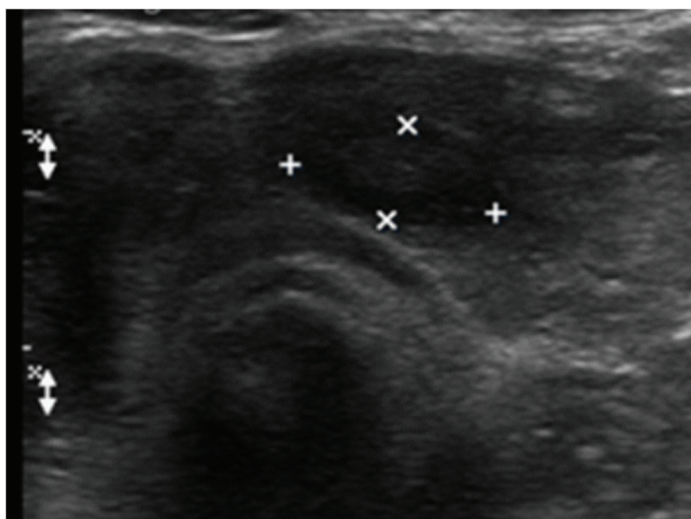
[Table/Fig-1]: Pre-operative image



[Table/Fig-2]: a) A heterogeneous hypoechoic area in the isthmus-left lobe junction at thyroid USG; b) an abscess within the isthmus and a part of the left lobe on neck CT; c) a heterogeneous area with a hypo-anechogenic internal structure involving the right and left lobes at thyroid USG; d) the abscess drainage catheter (arrow) can be seen inside the thyroid gland at USG

Biochemical parameters	First Hospitalization					Second Hospitalization			After discharge			
	1st day	2nd day	7th day*	10th day	13th day	1st day	7th day	14th day	1 month	3 months	6 months	12 months
Glucose (mg/dl) (74-109)	129	153	284			137						
HbA1c (%) (4.8-5.9)			6.88									
WBC (103/ μ L) (4.5-11.0)	13.3	7.6	5.1	7.5		10.3	7.3	5.8	10.2	6.6	6.5	8.8
Neutrophil (103/ μ L) (1.9-8.0)	9.5	4.5	2.4	3.5		5.8	3.7	2.5	5.1	2.9	3.7	4.6
CRP (mg/L) (0-0.5)	32.12	20.58	5.88		3.02	3.16	0.63	0.12	0.13	0.06		
Sedimentation rate (1 hour)	57		73			75		14	10	12	12	9
AntiTGA (IU/ml) (0-115)	52.97					11.07						
Free T3 (pg/ml) (2.0-4.4)	3.95	4.90	9.69	7.99	4.56	3.07	2.45	2.21		2.84		2.84
Free T4 (ng/dl) (0.93-1.70)	2.18	3.47	6.99	7.69	6.80	2.20	1.37	1.11	0.88	1.05	1.00	1.15
TSH (μ U/ml) (0.27-4.20)	0.190	0.040	0.007	0.006	0.005	0.008	0.062	1.65	1.52	2.04	1.29	1.30

[Table/Fig-3]: The patient's laboratory findings., * Antithyroid treatment was started



[Table/Fig-4]: [Table/Fig-4]: Well-circumscribed, hypoechoic area in the left lobe on thyroid USG.

cultures or Lowenstein Jensen. No antibiotic treatment was started. Following drainage of the abscess cavity for 16 d with a 6 french catheter, with the application of negative pressure, ultrasound was performed when serous discharge appeared from the catheter and collections in both lobes were seen to have decreased. The drainage catheter was removed, and the patient was seen to be euthyroid. Antithyroid treatment was stopped, and the patient was discharged. At ultrasound performed on the 17th month after treatment, only a well-circumscribed, hypoechoic nodular area 9 x 8 x 7 mm in diameter was determined in the left lobe [Table/Fig-4].

DISCUSSION

Factors such as its possession of a high iodine content and widespread lymphatic drainage, the richness of its arterial blood flow and having a capsule that completely surrounds it, mean that the thyroid gland is resistant to bacterial infections [1,2]. Therefore, acute suppurative thyroiditis (AST) is a rare condition. The infection agent leading to AST generally reaches the thyroid gland through hematogenous or lymphatic spread from respiratory tract infection in adults and may be sinus fistula-mediated in children [3]. Underlying diseases including diabetes mellitus, tuberculosis, and human immunodeficiency virus infection, appear to increase the risk for developing of thyroid abscess [4]. The suppurative process generally develops in the presence of underlying thyroid pathology

[5]. The most frequent pre-existing thyroid pathology is multinodular goiter [2,6]. Other causes of AST are neoplastic thyroid nodule, Hashimoto thyroiditis, subacute thyroiditis, and penetration of the thyroid gland by foreign bodies such as fish bones and trauma [2,7]. Fine needle aspiration (FNA) biopsy is a minimally invasive, economical and a reliable technique used in the diagnosis of thyroid pathologies. Local hematoma and pain are the most common complications of FNA [8]. AST can also develop (though rarely) after thyroid fine needle biopsy performed for diagnostic purposes [1,4,9,10]. Here, we report a case of thyrotoxicosis developing with AST after FNA. The patient has been newly diagnosed diabetes mellitus

AST onset is generally sudden, and the clinical picture progresses very rapidly. As in our patient, it frequently leads to symptoms such as painful swelling in the neck, hyperemia in the skin, hoarseness, dyspnea, dysphagia and high fever. It can also lead to life-threatening complications such as laryngeal oedema or tracheal compression-related airway obstruction [1].

As in our patient, during the course of the disease, leukocytosis, high erythrocyte sedimentation rate and elevated CRP level can be seen. Thyroid hormones may slightly rise in association with destruction of follicular cells, but thyrotoxicosis is rarely seen [4,5]. A few cases thyrotoxicosis developing with AST have been reported to date [3,4,11,12]. Moreover, to our knowledge, acute suppurative thyroiditis associated with thyrotoxicosis after FNA was reported only one case [4]. In this reported case of Nishihara E et al., antibiotic treatment for approximately one month did not improved to the inflammatory findings and left thyroid lobectomy performed. In our case, the patient was successfully treated with catheter drainage without lobectomy. AST associated with thyrotoxicosis generally temporary, and most patients will be improved without any specific treatment [12]. In the reported case of Nishihara E et al., thyroid hormone profile gradually returned to normal after surgery without antithyroid therapy [4]. Panamonta O et al., was reported the first child case of AST with thyrotoxicosis [11]. In this case, thyrotoxicosis was not treated with antithyroid therapy and thyroid function test returned to the normal levels five days after abscess drainage. In our case, antithyroid therapy was started a seven days after admission and thyroid hormones decreased immediately following the start of antithyroid therapy. In generally, at thyroid scintigraphy, thyroid gland activity is normal apart from a cold suppurative area [13]. In the reported cases of both Panamonta O et al., and Nishihara E et al., were not performed scintigraphy [4,11]. We fortunately performed

scintigraphy. Because, in our case, the activity was increased outside a cold area in which abscess developed and antithyroid therapy was started. If we didn't start to antithyroid therapy thyrotoxicosis may lead to thyroid storm, the worst complication of hyperthyroidism [14]. This can further exacerbate the existing picture.

As in our case, abscess in the thyroid gland can be confirmed with ultrasound [1] and tissue/fluid sampling can be performed with ultrasound guidance [2]. Computerized tomography or magnetic resonance imaging shows the abscess' topographical relations with neighbouring structures, such as the trachea. They may also reveal causes such as pyriform sinus fistula and foreign bodies that may occur in young patients and recurrent cases in particular [6].

FNA is a gold standard in diagnosing thyroid abscess, and it renders the isolation of the pathogenic agent. FNA biopsy also makes it possible to determine underlying causes such as thyroid neoplasm [1]. The most frequently isolated agents in AST are *Staphylococcus* and *Streptococcus* species [2,5]. Fungal, parasitic and microbacterial species can sometimes also be identified [5,15]. In our case, *Staphylococcus aureus* is yielded in abscess culture as in the reported case of Nishihara E et al., [4].

Treatment is based on wide-spectrum antibiotherapy and abscess drainage. The widely accepted approach involves surgical drainage of the abscess. Since thyroid abscess can develop due to malignancy, the abscess material must be examined for pathology, and any potential malignancy must be excluded. If malignancy is determined, an appropriate surgical approach must be performed if possible. Some authors have obtained successful results with using needle aspiration or catheter drainage and have recommended it as an alternative to surgical drainage [2]. Ilyin A et al., treated thyroid abscess in two cases with needle aspiration under USG guidance. [2]. In these cases, antibiotic was injected into the abscess cavity after the drainage of pus. In our patient the infection was not cured with simple needle drainage and we had to used drainage catheter.

CONCLUSION

In summary, in these patients, antibiotherapy and drainage procedures should be performed urgently. Antithyroid therapy needs should be determined, if also thyrotoxicosis develops. In

addition, it should be kept in mind that percutaneous drainage can be performed as an alternative to surgical drainage in patients developing AST.

ACKNOWLEDGMENTS

The authors gratefully thank Dr. Faruk Çavdar for contribution on case management.

REFERENCES

- [1] Halenka M, Skodova I, Horak D, Kucerova L, Karasek D, Fryszak Z. Thyroid Abscess as a Complication of Fine-Needle Aspiration Biopsy. *The Endocrinologist*. 2008;18:263-65.
- [2] Ilyin A, Zhelonkina N, Severskaya N, Romanko S. Nonsurgical Management of Thyroid Abscess with Sonographically Guided Fine Needle Aspiration. *Journal of Clinical Ultrasound*. 2007;35:333-37.
- [3] Kantorovich V, Patil N, Rassouli N. Acute suppurative thyroiditis with thyrotoxicosis caused by methicillin resistant staphylococcus aureus. *The International Journal of Medicine*. 2010;13:350-54.
- [4] Nishihara E, Miyauchi A, Matsuzuka F, et al. Acute suppurative thyroiditis after fine-needle aspiration causing thyrotoxicosis. *Thyroid*. 2005;15(10):1183-87.
- [5] Herndon MD, Christie DB, Ayoub MM, Duggan AD. Thyroid abscess: case report and review of the literature. *Am Surg*. 2007;73(7):725-28.
- [6] Dugar M, da Graca Bandeira A, Bruns J Jr, Som PM. Unilateral hypopharyngitis, cellulitis, and a multinodular goiter: a triad of findings suggestive of acute suppurative thyroiditis. *Am J Neuroradiol*. 2009;30(10):1944-46.
- [7] Chen CY, Peng JP. Esophageal fish bone migration induced thyroid abscess: case report and review of the literature. *Am J Otolaryngol*. 2011;32(3):253-55.
- [8] Polyzos SA, Anastasilakis AD. Clinical complications following thyroid fine-needle biopsy: a systematic review. *Clinical endocrinology*. 2009;71(2):157-65.
- [9] Sun JH, Chang HY, Chen KW, Lin KD, Lin JD, Hsueh C. Anaerobic thyroid abscess from a thyroid cyst after fine-needle aspiration. *Head Neck*. 2002;24:84-86.
- [10] Ulütürk U, Ceyhan K, Corapçiolu D. Acute suppurative thyroiditis following fine-needle aspiration biopsy in an immunocompetent patient. *J Clin Ultrasound*. 2013;doi:10.1002/jcu.22077.
- [11] Panamonta O, Panombualert S, Panamonta M, Apinives C. Acute suppurative thyroiditis with thyrotoxicosis. *J Med Assoc Thai*. 2009;92(10):1370-73.
- [12] Kobayashi A, Kuma K, Matsuzuka F, et al. Thyrotoxicosis after needle aspiration of thyroid cyst. *Journal of Clinical Endocrinology and Metabolism*. 1992;75:21-24.
- [13] Szabo SM, Allen DB. Thyroiditis. Differentiation of acute suppurative and subacute. Case report and review of the literature. *Clin Pediatr (Phila)*. 1989;28(4):171-74.
- [14] Chiha M, Samarasinghe S, Kabaker AS. Thyroid Storm: An Updated Review. *J Intensive Care Med*. 2013;doi: 10.1177/0885066613498053.
- [15] Jacobs A, Gros DA, Gradon JD. Thyroid abscess due to *Acinetobacter calcoaceticus*: case report and review of the causes of and current management strategies for thyroid abscesses. *South Med J*. 2003;96(3):300-07.

PARTICULARS OF CONTRIBUTORS:

1. Faculty of Medicine, Department of General Surgery, Balikesir University, Balikesir, Turkey.
2. Faculty of Medicine, Department of Radiology, Balikesir University, Balikesir, Turkey.
3. Faculty of Medicine, Department of Infectious Diseases, Balikesir University, Balikesir, Turkey.

NAME, ADDRESS, E-MAIL ID OF THE CORRESPONDING AUTHOR:

Dr. Murat Yildar,
Faculty of Medicine, Department of General Surgery, Balikesir University, Balikesir-10145, Turkey.
Phone : +90 505 578 43 87, Fax : +90 266 612 14 59, E-mail : muratyildar@hotmail.com

FINANCIAL OR OTHER COMPETING INTERESTS: None.

Date of Submission: **Apr 11, 2014**

Date of Peer Review: **Jul 29, 2014**

Date of Acceptance: **Sep 15, 2014**

Date of Publishing: **Nov 20, 2014**