

See discussions, stats, and author profiles for this publication at: <https://www.researchgate.net/publication/287966021>

Selenium Protects Retinal Cells from Cisplatin Induced Alterations in Carbohydrate Residues

Article in *Balkan Medical Journal* · December 2015

DOI: 10.5152/balkanmedj.2015.155532

CITATIONS

3

READS

86

9 authors, including:



Dilek Aksit

Balikesir University

42 PUBLICATIONS 175 CITATIONS

[SEE PROFILE](#)



Hasan Aksit

Balikesir University

58 PUBLICATIONS 303 CITATIONS

[SEE PROFILE](#)



Arzu Yay

Erciyes Üniversitesi

70 PUBLICATIONS 226 CITATIONS

[SEE PROFILE](#)



Kamil Seyrek

76 PUBLICATIONS 666 CITATIONS

[SEE PROFILE](#)

Some of the authors of this publication are also working on these related projects:



Experimental investigation of effects of platelet-rich plasma on early phases of orthodontic tooth movement [View project](#)



Evaluation of oxidative stress via total antioxidant status, sialic acid, malondialdehyde and RT-PCR findings in sheep affected with bluetongue [View project](#)

PROTECTIVE EFFECTS OF N-ACETYL CYSTEINE ON OLIGOSACCHARIDE RESIDUES IN THE EXPERIMENTAL LIVER INTOXICATION FORMED BY CARBONTETRACHLORIDE (CCl₄) IN RATS

DILEK AKSIT¹, YASEMIN ATICI², HASAN AKSIT³, HATIBE KARA³, AYSEGUL BILDIK⁴, KAMIL SEYREK⁵

¹Pharmacology and Toxicology Department, Faculty of Veterinary, Balikesir University, Balikesir, Turkey- ²Medical Biochemistry Department, Faculty of Medicine, Mustafa Kemal University, Hatay, Turkey- ³Biochemistry Department, Faculty of Veterinary, Balikesir University, Balikesir, Turkey- ⁴Biochemistry Department, Faculty of Veterinary, Adnan Menderes University, Aydin, Turkey- ⁵Medical Biochemistry Department, Faculty of Medicine, Balikesir University, Balikesir, Turkey

ABSTRACT

Aim: In this study, we aimed to investigate the protective effects of N-acetyl cysteine (NAC) that is known playing an important role in detoxification reactions of biomolecules, on rat liver tissue exposed to carbon tetrachloride (CCl₄).

Materials and methods: Twenty-eight rats were divided into four groups each containing seven rats: Control groups (Group 1: Olive oil group, Group 2: Olive oil+NAC group) and experimental groups (Group 3: CCl₄ group, Group 4: CCl₄+NAC group). CCl₄ was given in 1 ml/kg doses intraperitoneally (i.p.), NAC was given in 50 mg/kg doses. Oligosaccharide units were detected histochemically using biotin labeled lectins.

Results: Histochemically, NAC showed no remarkable effect on the staining intensity of biotin labeled lectins. Liver enzyme activities and plasma protein levels were measured using commercial available kits. Compared to the control group in CCl₄ given rats AST, GGT and ALP activities increased significantly (P<0.001), while NAC administration alleviated the toxic effects of CCl₄. CCl₄ decreased serum albumin concentration significantly (P<0.05), however NAC annihilated negative effect of CCl₄ on albumin concentration. The alterations in total protein levels and ALT activities remained insignificant (P>0.05).

Conclusion: Our findings indicate that cells may increase their oligosaccharide units to protect themselves from the toxic effects of CCl₄ and NAC may support cells to scavenge free radicals induced by CCl₄.

Key words: carbon tetra chloride, GSL-1, PSA, MAA, rat.

Received May 30, 2015; Accepted January 02, 2016

Introduction

Liver is an organ with various physiological and biochemical roles including detoxification of toxic substances. Because of its physiological and biochemical roles liver is exposed to several toxic agents and drugs. There are more than 600 chemical substances causing pathological alterations in liver. Carbon tetrachloride (CCl₄) is one of these substances inducing toxic alterations in liver⁽¹⁾. Table

To induce liver toxicity CCl₄ is used commonly in experimental studies. It stimulates free radical

production and is metabolized by mitochondrial monooxygenase enzyme system (P 450 2 E 1). First product of CCl₄ metabolites is a not stable free radical called trichlormethyl (CCl₃). Then this radical binds lipids and proteins covalently and forms peroxy radicals. Peroxy radicals lost their hydrogens and alter into the last product called chloroform^(2,3). Peroxy radicals damage cell membranes by peroxidation of membrane lipids⁽⁴⁾. Pathological alterations such as cirrhosis caused by high doses of CCl₄ in liver cells induce numerous clinical symptoms such as edema, weakness, sickness etc.^(5,6).

N-acetyl cysteine (NAC), a sulfur-based

amino acid, has a role in glutathione synthesis, which is a very significant antioxidant for the immune system⁽⁷⁻⁹⁾. NAC, the precursor of L-cysteine and glutathione (GSH), is used in the treatment of liver injury caused by paracetamol as well as by acetaminophen. Likewise, to impede the harmful effects of free radicals NAC is used following liver transplantation, alcoholism, metal toxicity and fibrosis^(10, 11). NAC regulates the activities of several proteins and inhibits apoptosis in liver cells⁽¹²⁾.

Lectins are carbohydrate binding proteins with are at least two sugar binding sites⁽¹³⁾. They fulfill their physiological and biochemical roles by decoding the biological code encoded in oligosaccharides of tissues. Plant lectins can be used as a tool to detect specific carbohydrate structures in animal tissues^(14,15).

In the present study, we intended to detect the alterations in oligosaccharide units (N-acetylgalactosamine, α -D-mannose and α -2,3 bound sialic acid) as well as some liver enzymes in rat liver exposed to high doses of CCl₄. We also intended to find out the putative protective effect of NAC on liver tissue of rats given CCl₄.

Materials and methods

Institutional ethics committee approval for animal studies was obtained prior to the study. All animals used in the study received care in compliance with the guidelines established by the committee. All studies with animals described herein were reviewed and approved by the university of Balikesir Animal Ethics Committee (approval date-number: 28 November 2011-2011/12).

Animals

Twenty-eight healthy adult male Sprague Dawley rats, 15-17 weeks old and weighing 170-210 gram were used. All the animals were kept at 22±2 °C in standard rat cages with controlled lighting (12 h light/dark). All rats were fed ad libitum standard pelleted diet and tap water. Rats were randomly divided into four equal groups each containing seven rats:

Control groups:

Group 1: Olive oil group,

Group 2: Olive oil+NAC group) and experimental group,

Group 3: CCl₄ group,

Group 4: CCl₄+NAC group). I

In the first control group (Group 1), animals were given three times every other day 1 mg/kg olive oil only i.p. In addition to olive oil in the second control group (Group 2), rats were given NAC (50 mg/kg/day) three days prior to the olive oil administration and continued to the end of the experiment. In the first experimental group (Group 3), rats were given CCl₄ (1 ml/kg), dissolved in olive oil (1/1 proportion) i.p. Administration of CCl₄ was performed three times every other day. To the rats in the second experimental group (Group 4), NAC was administered three days prior to the CCl₄ injection and NAC administration continued to the end of the experiment in 50 mg/kg/day doses i.p. At the end of the experimental period bloods were taken under ether anesthesia from the heart. Thereafter blood samples were centrifuged at 1500×g for ten minutes and serum samples stored at -80°C. Liver samples were removed for histochemical analyses fixed in 10% neutral buffered formalin and embedded in paraffin blocks. All animals were then sacrificed.

Biochemical analysis

In serum samples AST (Aspartate aminotransferase), ALT (alanine aminotransferase), GGT (Gamma glutamyl transferase), ALP (Alkaline phosphatase) activities as well as albumin and total protein levels were measured using commercial available test kits (Archem, Istanbul/Turkey) at an autoanalyzer (Sinnowa D280, China).

Immunohistochemistry for Lectins

Tissues in paraffin blocks were randomly cut in 5 μ m sections by a microtome (Leica RM 2135). After 2 h incubation at 40 °C, sections were deparaffinized in xylene, hydrated through graded ethanol and endogenous peroxidase blocked with 3% H₂O₂ in 70% methanol. The sections were washed as in step 3 for 10 min in phosphate-buffered saline (PBS, pH 7.3), and non-specific binding sites were blocked with 2% bovine serum albumin (Sigma, UK) to reduce background staining.

The sections were processed to detect the localization of oligosaccharide units using biotin labeled lectins such as Griffonia simplicifolia lectin (GSL-1) for N-acetylgalactosamine, Pisum sativum lectin (PSA) for α -D-mannose and Maackia amurensis lectin (MAA) for α - 2,3 bound sialic. Then the samples were processed with 0.05% (w/v) 3,30-diaminobenzidine and 0.010% (v/v) hydrogen

peroxide in PBS (10 mM, pH 7.4).

These sections were counter-stained with hematoxylin and mounted in entellan. Screen shots were taken with Camedia digital camera (C5050 zoom) at Olympus BX51 microscope.

Quantitative immunohistochemistry

All the slides were examined by the same observer who was blind to the tissue sections between groups. To evaluate the staining intensity of lectins (GSL-1, MAA, PSA), 8-10 different areas (per visual fields) from groups were randomly defined for experimental groups. The mean of reactivity intensity calculated by using Image J software at high power fields.

Statistical analysis

The analysis of the data was performed by using the Statistical Package for the Social Sciences (SPSS) 13.0 (SPSS, Inc., Chicago, Illinois, USA) statistical software. The one-way ANOVA and Duncan tests were used to compare the values of the different groups. Data were shown as mean \pm standard deviation. P values <0.05 were considered significant.

Results

As shown in table 1 CCl₄ administration to the rats elevated AST, GGT and ALP activities significantly ($P < 0.001$), while the levels of these enzymes significantly dropped by applying NAC ($P < 0.05$). Carbon tetrachloride decreased serum albumin concentration significantly ($P < 0.05$), however NAC annihilated negative effect of CCl₄ on albumin concentration.

Parameters	CCl ₄ (n = 7)	CCl ₄ +NAC (n = 7)	Control (Olive Oil) (n = 7)	Control (Olive Oil + NAC) (n = 7)	P
AST (U/L)	232.42 \pm 25.82 ^a	197 \pm 29.52 ^a	72 \pm 5.17 ^b	108.23 \pm 13.35 ^{ab}	*
ALT (U/L)	79.64 \pm 5.28	72.25 \pm 6.73	49.52 \pm 5.62	47.19 \pm 5.23	-
GGT (U/L)	13.28 \pm 0.68 ^a	9.12 \pm 0.29 ^b	8.66 \pm 0.49 ^b	8.57 \pm 0.42 ^b	***
ALP (U/L)	34.42 \pm 1.97 ^a	32.62 \pm 1.71 ^a	21.83 \pm 1.04 ^b	23.14 \pm 0.50 ^b	***
Albumin (g/dl)	3.21 \pm 0.06 ^b	3.26 \pm 0.06 ^b	3.50 \pm 0.09 ^a	3.50 \pm 0.07 ^a	*
Total Protein (g/dl)	6.35 \pm 0.18	6.13 \pm 0.12	6.49 \pm 0.22	6.50 \pm 0.20	-

Table 1: Effect of NAC and CCl₄ treatments on biochemical parameters

Statistical significance: * $p < 0.05$; *** $p < 0.001$. a, b: Between groups with different letters in the same row mean difference is significant. CCl₄: Carbon tetrachloride; NAC: N-acetyl cysteine; AST: Aspartate aminotransferase; ALT: Alanine aminotransferase; GGT: Gamma glutamyl transferase; ALP: Alkaline phosphatase.

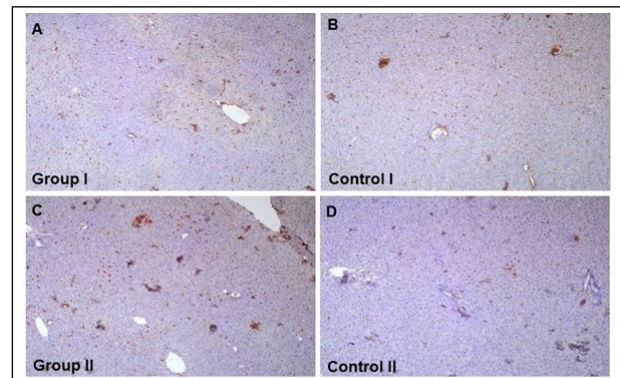


Figure 1. The binding sites for N-acetylgalactosamine specific GSL-1. Reactions are observed in centrilobular vein and sinusoidal capillaries of liver tissues. No staining was detected in hepatocytes. Carbon tetrachloride increased the staining intensity (A), while a slight staining was observed in controls (B,D). N-acetyl cysteine administration had no remarkable effect on staining intensity (C), 220X

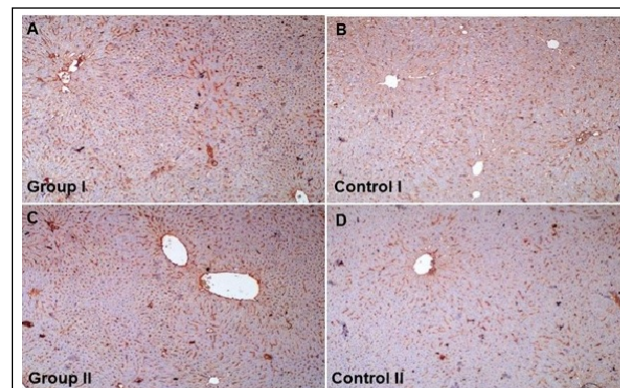


Figure 2. The binding sites for α -2,3 bound sialic acid specific MAA. Reactions are observed in centrilobular vein and sinusoidal capillaries of liver tissues. No staining was detected in hepatocytes. Carbon tetrachloride increased the staining intensity (A), while relatively a slight staining was observed in controls (B,D). N-acetyl cysteine administration had no remarkable effect on staining intensity (C), 220X

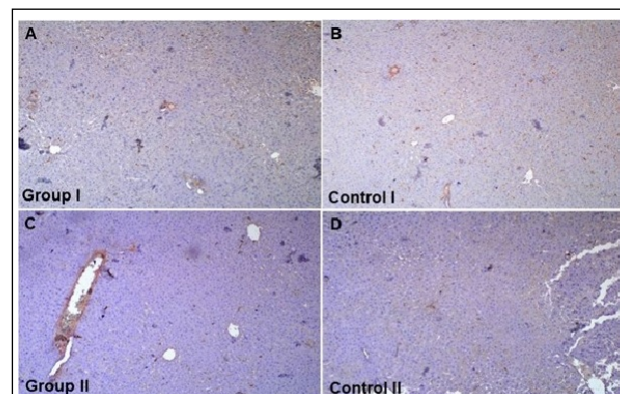


Figure 3. The binding sites for α -D-mannose specific PSA. Slight reactions are observed in centrilobular vein and sinusoidal capillaries of liver tissues. No staining was detected in hepatocytes. Carbon tetrachloride increased slightly the staining intensity (A), while relatively more slight stainings were observed in controls (B,D). N-acetyl cysteine administration had no remarkable effect on staining intensity (C), 220X

The alterations in total protein levels and ALT activities remained insignificant ($P > 0.05$).

Histochemically, reactions are observed in centrilobular vein and sinusoidal capillaries of liver tissues, while no staining was detected in hepatocytes. A slight staining for GSL-1 was visualized in centrilobular vein and sinusoidal capillaries of the liver. The staining pattern for GSL-1 was similar in all groups. However, the staining intensity in CCl₄-treated rats was stronger than the other groups

(Figure 1). A dense staining for MAA was observed in both experimental groups, while relatively moderate staining was detected in the liver tissue of controls (Figure 2). Compared to the GSL-1 and MAA a slighter staining was observed for PSA in all groups (Figure 3).

Discussion

Detoxification of all toxic substances takes place in liver. Therefore, liver is the central organ for removal of harmful chemical substances such as CCl₄. Histopathological studies revealed that CCl₄ causes acute and chronic liver damage^(16,17).

Measurements the activities of some liver specific enzymes (ALT, AST, ALP and GGT) can provide valuable information on the condition of the liver. Increased values in the activity of these enzymes may indicate an injury in liver⁽¹⁸⁾. In the case of cell membrane damage of liver cells activities of ALT and AST, cytoplasmic enzymes, in serum increased drastically⁽¹⁹⁾. A remarkable increase in serum activities of ALT and AST in CCl₄ given rats was reported by Ustundag et al.⁽²⁰⁾. It is revealed that within 12 hours ALT and AST activities start to increase in serum of rats exposed to 1 ml/kg CCl₄ and rises to the maximum activity⁽²¹⁻²³⁾.

Data obtained in this study is partly in line with the statements of Ustundag et al.⁽²⁰⁾. Increased AST activities obtained in this study from the rats subjected to CCl₄ were similar to the results published by Ustundag et al.⁽²⁰⁾. In spite of the elevations in ALT activities in rats given CCl₄ this increase was no statistically significant. Increased levels of AST, ALP and GGT obtained in the present study may not only indicate liver injury but also heart and renal tissues may be affected negatively.

NAC can enter to the cells easily and it is used in vivo and in vitro studies as an antioxidant. It protects the liver cells by increasing GSH levels in cells⁽²⁴⁾. Previous studies revealed that NAC protects the liver cells from the damage caused by CCl₄^(24,25). Similarly, results of the present study exhibited that NAC protect the liver cell from damage caused by CCl₄.

Protein and lipids in tissues are glycosylated and these sugar units attached to these molecules via glycosidic bond with tissue specificity. In the expression and localization of oligosaccharide units there are remarkable diversities based on the physi-

ological or pathological condition the cells. There are few studies on the alteration of oligosaccharide units in liver injury^(26,27).

However, to our knowledge there is no data published yet revealing the effects of CCl₄ induced liver injury on the expression and localization of certain oligosaccharide units such as N-acetylgalactosamine, α -D-mannose and α -2,3 bound sialic acid residues. The most intensive staining in oligosaccharide units visualized in this study was for MAA lectin specific for α -2,3 bound sialic acid residues. Especially, in liver tissue exposed to CCl₄ showed the strongest reaction with the biotin labeled MAA. This finding is in line with findings of previous researchers reported that damaged tissues as well as tissues suffering from a disease with poor prognosis expresses elevated levels of sialic acid^(28,29).

The intensity of the reaction for GSL-1, MAA and PSA obtained using Image J software program proved that NAC administration the CCl₄ exposed rats was stronger than that of CCl₄ group alone. In the light of this findings it could be speculated that to protect themselves cells exposed to a toxic substance increase the expression of N-acetylgalactosamine, α -D-mannose and α -2,3 bound sialic acid. In addition, NAC may protect cells from the damaging effects of free radicals not only by scavenging free oxygen radicals but also by increasing oligosaccharide residues.

Conclusion

Cells may increase their oligosaccharide units to protect themselves from the CCl₄ induced liver damage and NAC may have beneficial, protective and curative effects on hepatic cells from the toxic radicals induced by CCl₄ in rats.

References

- 1) Robbins SL, Cotran RS, Kumar V. *Basic Pathology*. Sixth Edition. Philadelphia: WB Saunders Company 2000.
- 2) Recknagel R, Glende EA, Dolak JA, Waller RL. *Mechanisms of carbon tetrachloride toxicity*. *Pharma Ther* 1989; 43: 139-54.
- 3) Cheshchevik VT, Lapshina EA, Dremza IK, Zabrodskaya SV, Reiter RJ, et al. *Rat liver mitochondrial damage under acute or chronic carbon tetrachloride-induced intoxication: protection by melatonin and cranberry flavonoids*. *Toxicol Appl Pharmacol* 2012; 261: 271-9.

- 4) Salam OM, Sleem AA, Omara EA, Hassan NS. *Hepatoprotective effects of misoprostol and silymarin on carbon tetrachloride-induced hepatic damage in rats*. *Fundam Clin Pharmacol* 2009; 23: 179-88.
- 5) Al-Assaf AH. *Preventive effect of corosolic acid on lipid profile against carbon tetrachloride-induced hepatotoxic rats*. *Pakistan Journal of Nutrition* 2013; 12: 748-52.
- 6) Bilgin HM, Atmaca M, Deniz Obay B, Ozekinci S, Taşdemir E, et al. *Protective effects of coumarin and coumarin derivatives against carbon tetrachloride-induced acute hepatotoxicity in rats*. *Exp Toxicol Pathol* 2011; 63: 325-30.
- 7) Kortsalioudaki C, Taylor RM, Cheeseman P, Bansal S, MieliVergani G, et al. *Safety and efficacy of n-acetylcysteine in children with non-acetaminophen-induced acute liver failure*. *Liver Transpl* 2008; 14: 25-30.
- 8) Kumar BA, Reddy AG, Kumar PR, Reddy YR, Rao TM, et al. *Protective role of n-acetyl l-cysteine against reproductive toxicity due to interaction of lead and cadmium in male wistar rats*. *J Nat Sci Biol Med* 2013; 4: 414-9.
- 9) Atkuri KR, Mantovani JJ, Herzenberg LA, Herzenberg LA. *N-acetylcysteine-a safe antidote for cysteine/glutathione deficiency*. *Curr Opin Pharmacol* 2007; 7: 355-9.
- 10) Zafarullah M, Li WQ, Sylvester J, Ahmad M. *Molecular mechanisms of n acetyl cysteine actions*. *Cell Mol Life Sci* 2003; 60: 6-20.
- 11) Bernardi RM, Constantino L, Machado RA, Vuolo F, Budni P, et al. *N-acetylcysteine and deferoxamine protect against acute renal failure induced by ischemia/reperfusion in rats*. *Rev Bras Ter Intensiva* 2012; 24: 219-23.
- 12) Foresti R, Sarathchandra P, Clark JE, Green CJ, Motterlini R. *Peroxynitrite induces heme oxygenase-1 in vascular endothelial cells: a link to apoptosis*. *Biochem J* 1999; 339: 729-36.
- 13) Costa FH, Valença NS, Silva AR, Bezerra GA, Cavada BS, et al. *Cloning and molecular modeling of Litopenaeus vannamei (Penaeidae) C-type lectin homologs with mutated mannose binding domain-2*. *Genet Mol Res* 2011; 10: 650-64.
- 14) Bourrillon R, Aubery M. *Cell surface glycoproteins in embryonic development*. *Int Rev Cytol* 1989; 116: 257-338.
- 15) Gabius HJ. *Animal lectins*. *Eur J Biochem* 1997; 243: 543-76.
- 16) Handa SS, Sharma A. *Hepatoprotective activity of andrographolide from Andrographis paniculata against carbon tetrachlorid*. *Indian J Med Res B* 1990; 92: 276-83.
- 17) Rojkind M. *Inhibition of liver fibrosis by-L Azetidine-2-carboxylic acid in rats treated with carbon tetrachloride*. *J Clin Invest* 1973; 52: 2451-6.
- 18) Roderick P. *Liver function tests: defining what's normal*. *Brit Med J* 2004; 328: 987.
- 19) Lu KL, Tsai CC, Ho LK, Lin CC, Chang YS. *Preventive effect of the Taiwan folk medicine Ixeris laevigata var. Oldhami on a-nophthyl-isothiocyarate and carbon tetrachloride-induced acute liver injury in rats*. *Phytother Res* 2002; 16: 45-50.
- 20) Üstündağ B, Bahçecioglu İH, Şahin K, Gülcü F, Düzgün S, et al. *Soy izoflavonların karbon tetraklorüre (CCl4) bağlı karaciğer hasarı ve plazma paraoksonaz ile arilesteraz aktivite düzeylerine olan etkileri*. *FÜ Sağlık Bil Dergisi* 2005; 19(4): 263-71.
- 21) Ariosto F, Riggio O, Cantafora A, Colucci S, Gaudio E, et al. *Carbon tetrachloride - induced experimental cirrhosis in the rat: A reappraisal of the model*. *Eur Surg Res* 1989; 21: 280-6.
- 22) Dashti H, Jeppson B, Hagerstrand I, Hultberg B, Srinivas U, et al. *Thioacetamide and carbontetrachloride-induced liver cirrhosis*. *Eur Surg Res* 1989; 21: 833-91.
- 23) Lida C, Fujii K, Koga E, Washino Y, Kitamura Y, et al. *Effect of alpha-tocopherol on carbon tetrachloride intoxication in the rat liver*. *Arch Toxicol* 2009; 83(5): 477-83.
- 24) Howard RJMW, Blake DR, Pall H, Williams A. *Green ID. Allopurinol/Nacetylcysteine for carbon monoxide poisoning*. *Lancet* 1987; 2: 628-9.
- 25) Kelly GS. *Clinical applications of n-acetylcysteine*. *Altern Med Rev* 1998; 3(2): 114-27.
- 26) Blomme B, Steenkiste CV, Vanhuysse J, Colle I, Callewaert N, et al. *Impact of elevation of total bilirubin level and etiology of the liver disease on serum n-glycosylation patterns in mice and humans*. *Am J Physiol Gastrointest Liver Physiol* 2010; 298: G615-24.
- 27) Pepard CD, Ponard D, Colonb MG. *Analysis of low molecular weight intracellular association of a human mannan binding lectin (MBL)*. *Mol Immunol* 2004; 40: 795-801.
- 28) Kamigaito T, Okaneya T, Kawakubo M, Shimojo H, Nishizawa O, et al. *Overexpression of O-GlcNAc by prostate cancer cells is significantly associated with poor prognosis of patients*. *Prostate Cancer PD* 2014; 17: 18-22.
- 29) Pan X, Wilson M, Mirbahai L, McConville C, Arvanitis TN, et al. *In vitro metabonomic study detects increases in UDP-GlcNAc and UDP-GalNAc, as early phase markers of cisplatin treatment response in brain tumor cells*. *J Proteome Res* 2011; 10: 3493-500.

Corresponding author

DILEK AKSIT, Assistant Professor
 Faculty of Veterinary, Pharmacology and Toxicology
 Department, Balikesir University
 Balikesir, 10145
 (Turkey)