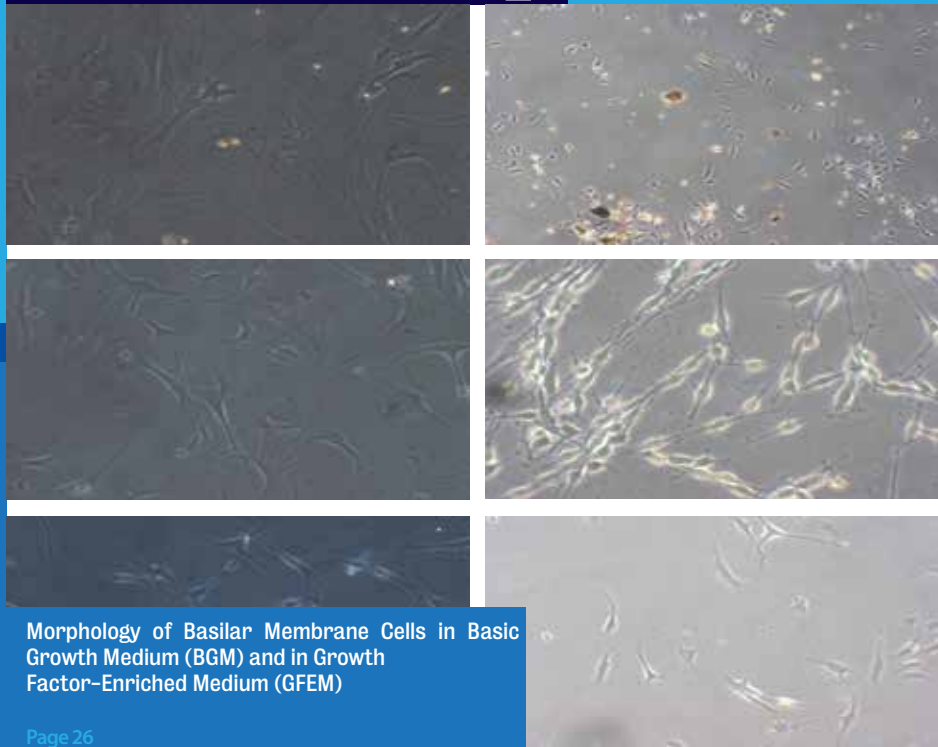


# IAO The Journal of International Advanced Otology



Morphology of Basilar Membrane Cells in Basic Growth Medium (BGM) and in Growth Factor-Enriched Medium (GFEM)

Page 26

Supported by



Member of



Covered by

**SCI EXPANDED**

Beginning with Vol 3 Issue 1





Original Article

# The Potential Protective Effects of 2-aminoethyl Diphenylborinate against Inner Ear Acoustic Trauma: Experimental Study Using Transmission and Scanning Electron Microscopy

Mustafa Kaymakçı, Mustafa Acar, Dilek Burukoglu, Hatice Mehtap Kutlu, Paria Shojaolsadati, Cemal Cingi, Nuray Bayar Muluk

Department of Ear, Nose and Throat, Balıkesir University Faculty of Medicine, Balıkesir, Turkey (MK)

Department of Ear, Nose and Throat, Yunus Emre State Hospital, Eskişehir, Turkey (MA)

Department of Histology, Eskişehir Osmangazi University Faculty of Medicine, Eskişehir, Turkey (DB)

Department of Biology, Anadolu University Faculty of Science, Eskişehir, Turkey (HMK)

Department of Anatomy, Eskişehir Osmangazi University Faculty of Medicine, Eskişehir, Turkey (PS)

Department of Ear, Nose and Throat, Eskişehir Osmangazi University Faculty of Medicine, Eskişehir, Turkey (CC)

Department of Ear, Nose and Throat, Kırıkkale University Faculty of Medicine, Kırıkkale, Turkey (NBM)

**OBJECTIVE:** In this prospective experimental study, we investigated the preventive effects of 2-aminoethyl diphenylborinate (2-APB) in rats exposed to acoustic trauma (AT). Light microscopic, transmission electron microscopic (TEM), and scanning electron microscopic (SEM) examinations were performed.

**MATERIALS and METHODS:** Eighteen healthy Wistar albino rats were divided into the following three groups: groups 1 (control), 2 (AT), and 3 (AT+APB). The rats in groups 2 and 3 were exposed to AT; in group 3 rats, 2-APB at 2 mg/kg was also administered, initially transperitoneally, after 10 min.

**RESULTS:** During the light microscopic, TEM, and SEM examinations, the structures of the cochlear hair cells, stereocilia, and Deiter's cells were normal in the control group. In the AT group, the organ of Corti and proximate structures were damaged according to the light microscopic examination. During the TEM examination, intense cellular damage and stereocilia loss were detected, while during the SEM examination, extensive damage and stereocilia loss were observed. Decreased damage with preserved cochlear structure was detected during the light microscopic examination in the AT+APB group than in the AT group. During the TEM and SEM examinations, although stereocilia loss occurred in the AT+APB group, near-normal cell, cilia, and tectorial membrane structures were also observed in the AT+APB group compared with the AT group.

**CONCLUSION:** 2-APB may have protective effects against AT damage of the cochlea. The main mechanism underlying this effect is the inhibition of the vasoconstriction of the cochlear spiral modiolar artery, thereby improving cochlear blood flow. We conclude that 2-APB may also be effective if used immediately following AT.

**KEYWORDS:** 2-Aminoethyl diphenylborinate (2-APB), acoustic trauma (AT), electron microscopy

## INTRODUCTION

Acoustic noise trauma can be caused by abrupt explosive sounds inducing mechanical injury to the structures of the middle and inner ears. It is widely accepted that biochemical changes or changes in the functional unity of the outer hair cells and auditory nerve fibers can precipitate cell destruction and hearing loss<sup>[1-3]</sup>. After noise exposure, outer hair cells are impaired<sup>[4]</sup>, and reactive oxygen levels increase in the cochlea<sup>[5]</sup>. Exposure to loud noise can impair cochlear microcirculation and cause noise-induced hearing loss (NIHL). Agents that control or inhibit spiral modiolar artery vasoconstriction may also regulate cochlear microcirculation<sup>[6]</sup>. 2-Aminoethyl diphenylborinate (2-APB) inhibits inositol 1,4,5-trisphosphate<sup>[7]</sup> and the vasoconstriction of the spiral modiolar artery in the cochlea. 2-APB also blocks mitochondrial permeability<sup>[8]</sup> and is also reported to be a Ca<sup>2+</sup> release modulator<sup>[9]</sup>. Because of the ability of 2-APB to prevent cochlear vasoconstriction, we investigated its potential utility for ameliorating acoustic trauma (AT) in rats. Transmission electron microscopic (TEM) and scanning electron microscopic (SEM) examinations were performed.

## MATERIALS and METHODS

The study was performed in the Medical Faculty of Eskişehir Osmangazi University and Experimental Animal Breeding and Experimental Studies Center of the University. The study was conducted in accordance with the Helsinki Declaration<sup>[10]</sup>. Ethics committee approval was received from the university.

### Corresponding Address:

Nuray Bayar Muluk, Department of Ear, Nose and Throat, Kırıkkale University Faculty of Medicine, Kırıkkale, Turkey

Phone: +90 312 496 40 73; E-mail: nbayarmuluk@yahoo.com

Submitted: 29.12.2014

Revision received: 20.04.2015

Accepted: 21.04.2015

Copyright 2015 © The Mediterranean Society of Otology and Audiology

## Subjects

The study was performed using 18 healthy Wistar albino rats weighing between 190 and 220 g. In each group, the rats were placed in separate cages and were acclimated to a room maintained at 20°C. Care and feeding of the rats were provided at regular intervals throughout the study.

Groups were randomly created as below:

- Group 1 (control;  $n=6$ ): No AT exposure in this group.
- Group 2 ( $n=6$ ): In this group, AT exposure was performed, but no drugs were given.
- Group 3 ( $n=6$ ): In this group, the rats were administered 2-APB, which was dissolved in 2 ml of 95% ethanol at 2mg/kg, initially transperitoneally; after 10 min, they were exposed to AT.

**Preparation of 2-APB:** 2-APB was initially dissolved in 95% ethanol to allow administration at 50 mg/kg. Eau distilled water was then added such that the ethanol was at 4%; i.e., 1-mL mixture+24 ml Eau distilled water was used and administered at 2 mg/kg.

## Anesthesia Procedure

In total, 40 mg/kg ketamine hydrochloride (Ketalar, Parke-Davis, USA) and 5 mg/kg xylazine hydrochloride (Rompun, Bayer, Germany) were intramuscularly administered.

## AT

To expose the rats to AT using 1–12-kHz band white noise, the MATLAB software (MathWorks, Inc.; Natick, Massachusetts, United States) was used to produce various single-unit sounds. The sounds were then band-pass filtered from 1 to 12 kHz using an FIR-type digital filter and an additional filter with a frequency of 200. The filtered noise was then recorded as .wav files. Using a decibel meter, 110 dB of noise of approximately 6 h duration was continuously applied to expose the rats to AT.

## Electron Microscopic Examination

Following the experimental phase, the rats were sacrificed using 80 mg/kg pentothal 30 min following AT. Temporal bones were immediately removed, and the otic bullas were excised [11].

After the removal of the cochlea, hair cells were examined at the middle and basal turns of the cochlea.

## TEM Examination

For the TEM examination, the samples were fixed in glutaraldehyde (2.5 %) and paraformaldehyde (0.1 %) in phosphate buffer (0.1M; pH=7.4) and were then post-fixed in 2% OsO<sub>4</sub>. Following post-fixation, the samples were applied to an ethanol series for dehydration and an epoxy resin. Following polymerization, the samples were cut using a Leica EMU6 ultramicrotome. Semi-thin sections of 700–800 nm were stained with toluidine blue. Thin sections (70–80 nm) were double stained by uranyl acetate and lead citrate [12]. Images were obtained using an FEI (Biotwin, Netherlands) TEM.

## SEM Examination

The cochlea and organ of Corti were dissected and fixed prior to the SEM examination; all samples were fixed and post-fixed in an identical manner. The cochlea was applied to an ethanol series of 50%,

70%, 90%, and absolute ethanol for dehydration, and desiccation was then performed [13]. These samples were mounted on a specimen stub. Following critical point drying using CO<sub>2</sub> and gold sputter coating according to standard procedures, the specimens were assessed with a Zeiss Ultra 50 SEM having an accelerating tension of 5 kV [13].

## RESULTS

The TEM and SEM examinations revealed no cochlear damage in the group 1 rats (control group). In the group 2 rats (AT-exposed, no 2-APB), cochlear damage was detected. In the AT group, the inner and outer hair cells were absent or severely damaged. The damage was serious in the cochlear basal turns. However, in the group 3 rats (2-APB+AT), there was minimal cochlear damage, with only a small number of missing inner and outer hair cells. Light damage to the outer hair cell stereocilia was observed.

### Light Microscopic Examination Results (Figure 1):

- Control group: An apparently normal cochlear structure was detected (Figure 1A).
- AT group: The organ of Corti and other members of the turn were damaged in the cochlea (Figure 1B).
- AT+2-APB group: Decreased damage to the outer and inner hair cells was detected (compared with the AT group) with preserved cochlear structures (Figure 1C).

### TEM Examination Results (Figure 2):

- Control group: Normal hair cell and stereocilia structures were detected (Figure 2A).
- AT group: Intense cellular damage and stereocilia loss were observed (Figure 2B).
- AT+2-APB group: Although stereocilia loss was detected, near-normal cell, cilia, and tectorial membrane structures were detected (compared with the AT group; Figure 2C).

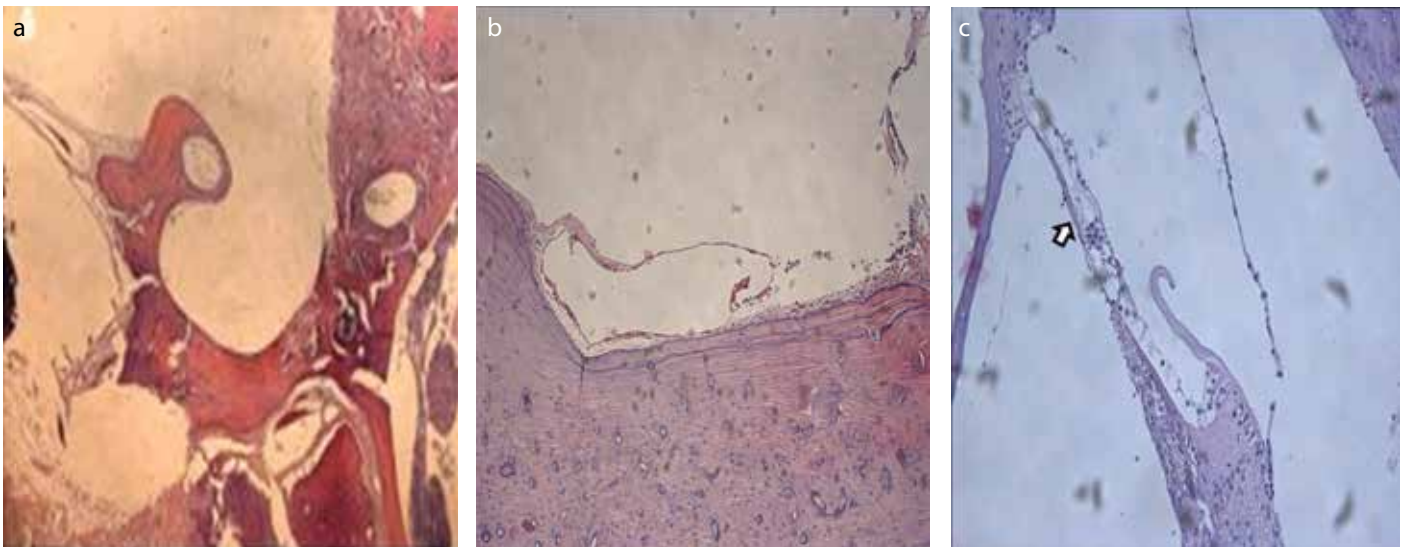
### SEM Examination Results (Figure 3):

- Control group: Normal structures of the hair cells, stereocilia, and Deiter's cells were detected (Figure 3A).
- AT group: Extensive damage and loss of stereocilia were detected (Figure 3B).
- AT+2-APB group: Although missing stereocilia was detected in this group, near-normal cell and stereocilia structures were observed (compared with the AT group; Figure 3C).

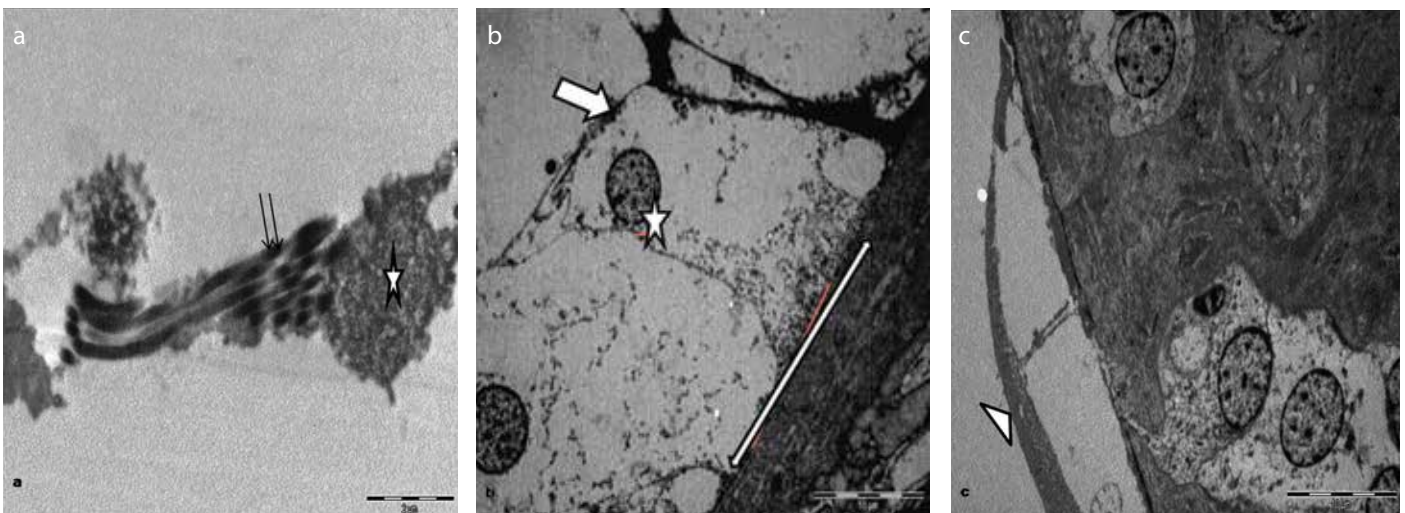
## DISCUSSION

Acute AT can occur following exposure to a loud noise over a short period of time and can present as sensorineural hearing loss and tinnitus. High-frequency sounds created by noise, such as rifle fire, that cause shock are typical of noise patterns that can induce AT; permanent hearing loss can occur following a single exposure without a temporary threshold shift [1, 14, 15].

SMA supports the inner ear's circulation. Decrease in the blood supply causes sensorineural hearing loss. Increase in intracellular Ca<sup>2+</sup> levels causes increased resistance in the vascular smooth muscle cells [16, 17]. The activation of Rho-kinase also causes vasospasms in SMA [17-20]. 2-APB inhibits Ca<sup>2+</sup> level increase, thereby precipitating vasodilatation, which prevents cochlear damage due to the vasoconstriction of SMA.



**Figure 1. a-c.** Light microscopic view of the cochlea in the control group rats: an apparently normal cochlear structure [scale bar for hematoxylin eosin (HE): 200  $\mu\text{m}$  (a); 100  $\mu\text{m}$  (b); and 100  $\mu\text{m}$  (c)]. Light microscopic view of the cochlea in the AT group rats: light microscopic micrograph of paraffin-embedded and HE-stained cochlear turns. The organ of Corti and other structures of the turn are damaged [scale bar for HE: 200  $\mu\text{m}$  (a); 100  $\mu\text{m}$  (b); and 100  $\mu\text{m}$  (c)]. Light microscopic view of the cochlea in the AT+APB group rats: although damaged structures in the outer and inner hair cells were detected ( $\rightarrow$ ), decreased damage and preserved cochlear structures were observed compared with the AT group [scale bar for HE: 200  $\mu\text{m}$  (a); 100  $\mu\text{m}$  (b); and 100  $\mu\text{m}$  (c)]



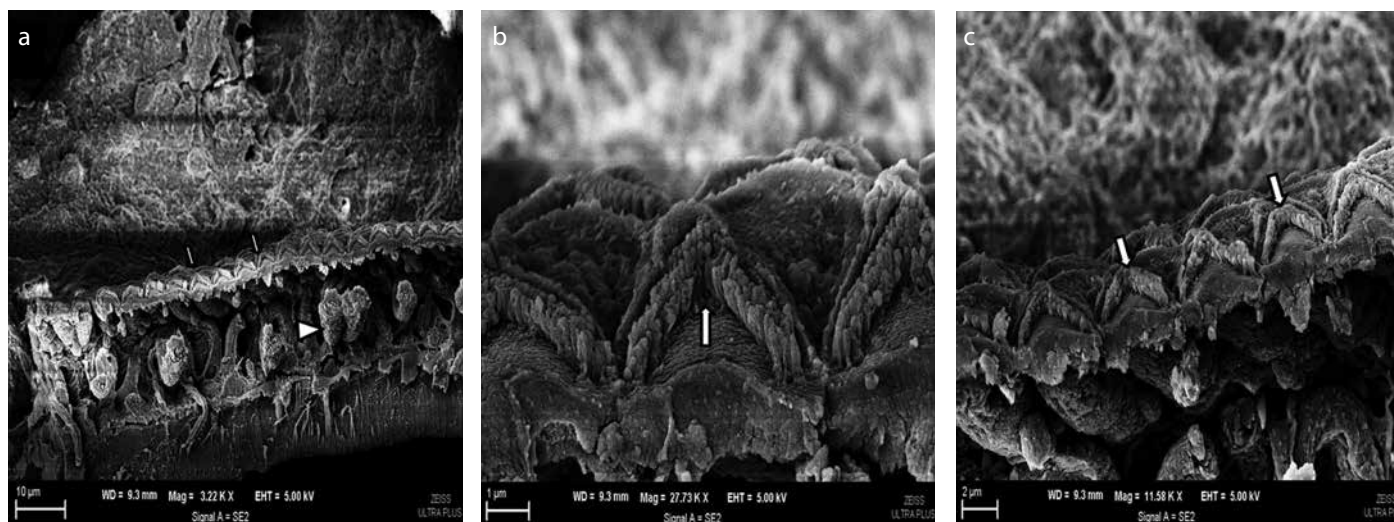
**Figure 2. a-c.** Transmission electron microscopic (TEM) view of the cochlea in the control group rats with normal structure of hair cells (\*) and stereocilia (double arrow) (TEM-uranyl acetate+lead citrate) (a). TEM view of the cochlea in the AT group rats with intense cellular damage (\*) and stereocilia loss ( $\rightarrow$ ) (TEM-uranyl acetate+lead citrate) (b). TEM view of the cochlea in the AT+APB group rats: Although stereocilia loss was detected, near-normal cell, cilia, and tectorial membrane structures (▶) were observed compared with the AT group rats. The double arrow indicates the basilar membrane structure (TEM-uranyl acetate+lead citrate) (c)

In this study, the preventive effects of 2-APB in rats exposed to AT were examined using TEM and SEM. We found no studies similar to our own within the pre-existing literature. No cochlear damage was detected in the control group rats. In contrast, in the group 2 rats (AT-exposed, no 2-APB), stereocilia were damaged in the inner and outer hair cells. In the basal cochlear turn, there was evident damage. In the group 3 rats (2-APB+AT group), there was minimal cochlear damage, with only a small number of missing cells in the inner and outer hair cells. Light damage to the outer hair cell stereocilia was observed.

In the light microscopic, TEM, and SEM examinations, the structures of the cochlear hair cells, stereocilia, and Deiter's cells were normal in the control group rats. In the AT-exposed group rats, the organ of Corti and other structures of the turn in the cochlea were damaged ac-

ording to the light microscopic examination. During the TEM examination, intense cellular damage and stereocilia loss were observed. During the SEM examination, extensive damage and loss of stereocilia were also detected. In the AT+APB group rats, decreased damage with preserved cochlear structures was observed according to the light microscopic examination. During the TEM and SEM examinations, stereocilia loss was detected but with near-normal cell, cilia, and tectorial membrane structures (compared with the AT group rats).

In the inner ear, spasms of SMA can lead to ischemia [21]. 2-APB causes a decrease in  $\text{Ca}^{2+}$  uptake in the mitochondria [7]. Spasms in SMA may occur in tinnitus and hearing loss. 2-APB inhibits vasoconstriction [22]. This indicates that 2-APB has an impact on the spiral modiolar artery, thereby inhibiting vasoconstriction and precipitating vasodilatation.



**Figure 3.** a-c. Scanning electron microscopic (SEM) view of the cochlea in the control group rats: SEM revealed the structures of normal hair cells, stereocilia, and Deiter's cells (▶) (a). SEM view of the cochlea in the AT group rats: extensive damage and loss of stereocilia (→) (b). SEM views of the cochlea in the AT+APB group rats: although missing stereocilia were detected, near-normal cell and stereocilia structures (→) were observed (compared with the AT group) (c)

Another mechanism for explaining NIHL is oxidative stress. Kopke et al. [23] reported that in noise-induced cochlear damage, oxidative stress may play a role. In this process, mitochondrial biogenesis is also important. It may be reduced with the help of acetyl-L-carnitine, which reduces hair cell loss in the inner ear. Carbamathione is another treatment modality in animal studies, and it decreases outer hair cell loss compared with that in a control group [23]. In the presence of AT, N-acetylcysteine reduces hearing loss [24], and this protection is present in high-kurtosis noise [25].

Our study is different from the studies by Kopke et al. [23, 24]. 2-APB does not have impact on the cochlea as an oxidative stress mechanism. Our study demonstrated that 2-APB may have protective effects against AT damage in the cochlea. The main mechanism underpinning this effect appears to be the inhibition of vasoconstriction of SMA of the cochlea. In patients exposed to AT, vasoconstriction secondary to AT may be responsible for cochlear damage and NIHL.

Therefore, our results could be useful for research concerned with AT and NIHL in humans. The toxicological effects of it have not been thoroughly studied [26]. For its use in humans, detailed research should be performed.

In the present study, we administered 2-APB prior to the onset of AT. In future investigations, the effects of 2-APB applied in the period immediately following AT should also be investigated. Because of its effect on cochlear blood flow, we suspect that 2-APB was also effective when used in this capacity.

In workplaces associated with high levels of noise and/or in the armed forces, 2-APB may be particularly useful. 2-APB could also be used to improve cochlear blood flow in individuals experiencing sudden hearing loss. Future research should aim to determine the optimum 2-APB dose for humans.

**Ethics Committee Approval:** Ethics committee approval was received for this study from Eskişehir Osmangazi University.

**Peer-review:** Externally peer-reviewed.

**Author Contributions:** Concept - C.C., N.B.M.; Design - M.K., M.A., D.B., H.M.K., P.S., C.C.; Supervision - N.B.M., C.C.; Funding - M.K., C.C.; Materials - M.K., M.A., C.C.; Data Collection and/or Processing - M.K., M.A. D.B., H.M.K., P.S., C.C., N.B.M.; Analysis and/or Interpretation - D.B., H.M.K., C.C., N.B.M.; Literature Review - N.B.M., M.K.; Writing - N.B.M.; Critical Review - N.B.M.

**Acknowledgement:** With the exception of data collection, the preparation of this paper, including design and planning, was supported by the Continuous Education and Scientific Research Association. Only scientific support was provided; no grant or funding was received.

**Conflict of Interest:** No conflict of interest was declared by the authors.

**Financial Disclosure:** The authors declared that this study has received no financial support.

## REFERENCES

- Dinh CT, Goncalves S, Bas E, Van De Water TR, Zine A. Molecular regulation of auditory hair cell death and approaches to protect sensory receptor cells and/or stimulate repair following acoustic trauma. *Front Cell Neurosci* 2015; 9: 96.
- Turcot A, Girard SA, Courteau M, Baril J, Larocque R. Noise-induced hearing loss and combined noise and vibration exposure. *Occup Med (Lond)* 2015; 65: 238-44.
- Lim DJ. Functional structure of the organ of corti: a review. *Hear Res* 1986; 22: 117-46.
- Maulucci G, Troiani D, Eramo SL, Paciello F, Podda MV, Paludetti G, et al. Time evolution of noise induced oxidation in outer hair cells: role of NAD(P)H and plasma membrane fluidity. *Biochim Biophys Acta* 2014; 1840: 2192-202.
- Bielefeld EC. Reduction in impulse noise-induced permanent threshold shift with intracochlear application of an NADPH oxidase inhibitor. *J Am Acad Audiol* 2013; 24: 461-73.
- Arpornchayanon W, Canis M, Ihler F, Settevendemie C, Strieth S. TNF- $\alpha$  inhibition using etanercept prevents noise-induced hearing loss by improvement of cochlear blood flow in vivo. *Int J Audiol* 2013; 52: 545-52.
- Peppiatt CM, Collins TJ, Mackenzie L, Conway SJ, Holmes AB, Bootman MD, et al. 2-Aminoethoxydiphenyl borate (2-APB) antagonises inositol 1,4,5-trisphosphate-induced calcium release, inhibits calcium pumps and has a use-dependent and slowly reversible action on store-operated calcium entry channels. *Cell Calcium* 2003; 34: 97-108.
- Product block. 2-APB (CAS 524-95-8). <http://www.scbt.com/datasheet-201487-2-apb.html> (Received: 20 April 2015).
- Peppiatt CM, Collins TJ, Mackenzie L, Conway SJ, Holmes AB, Bootman MD, et al. 2-Aminoethoxydiphenyl borate (2-APB) antagonises inositol 1,4,5-tri-

- sphosphate-induced calcium release, inhibits calcium pumps and has a use-dependent and slowly reversible action on store-operated calcium entry channels. *Cell Calcium* 2003; 34: 97-108.
10. 52nd WMA General Assembly. World Medical Association Declaration of Helsinki: ethical principles for medical research involving human subjects. *JAMA* 2000; 284: 3043-9.
  11. Chole RA, Quick CA. Experimental temporal bone histopathology in rats deprived of dietary retinol and maintained with supplemental retinoic acid. *J Nutr* 1978; 108: 1008-16.
  12. Öz Gergin Ö, Yıldız K, Bayram A, Sencar L, Coşkun G, Yay A, et al. Comparison of the myotoxic effects of levobupivacaine, bupivacaine, and ropivacaine: an electron microscopic study. *Ultrastruct Pathol* 2015; 39: 169-76.
  13. Lovell BM, Harper GM. The morphology of the inner ear from the domestic pig (*sus scrofa*). *J Microsc* 2007; 228: 345-57.
  14. Moon IS, Park SY, Park HJ, Yang HS, Hong SJ, Lee WS. Clinical characteristics of acoustic trauma caused by gunshot noise in mass rifle drills without ear protection. *J Occup Environ Hyg* 2011; 8: 618-23.
  15. Mrena R, Savolainen S, Pirvola U, Ylikoski J. Characteristics of acute acoustical trauma in the Finnish Defense Forces. *Int J Audiol* 2004; 43: 177-81.
  16. Reimann K, Krishnamoorthy G, Wangemann P. NOS inhibition enhances myogenic tone by increasing rho-kinase mediated Ca<sup>2+</sup> sensitivity in the male but not the female gerbil spiral modiolar artery. *PLoS One* 2013; 8: e53655.
  17. Somlyo AP, Somlyo AV. Ca<sup>2+</sup> sensitivity of smooth muscle and nonmuscle myosin II: modulated by g proteins, kinases, and myosin phosphatase. *Physiol Rev* 2003; 83: 1325-58.
  18. Kimura K, Ito M, Amano M, Chihara K, Fukata Y, Nakafuku M, et al. Regulation of myosin phosphatase by Rho and Rho-associated kinase (Rho-kinase). *Science* 1996; 273: 245-8.
  19. Sato M, Tani E, Fujikawa H, Kaibuchi K. Involvement of Rho-kinase-mediated phosphorylation of myosin light chain in enhancement of cerebral vasospasm. *Circ Res* 2000; 87: 195-200.
  20. Scherer EQ, Herzog M, Wangemann P. Endothelin-1-induced vasospasms of spiral modiolar artery are mediated by rho-kinase-induced Ca<sup>2+</sup> sensitization of contractile apparatus and reversed by calcitonin gene-related peptide. *Stroke* 2002; 33: 2965-71.
  21. Scherer EQ, Arnold W, Wangemann P. Pharmacological reversal of endothelin-1 mediated constriction of the spiral modiolar artery: a potential new treatment for sudden sensorineural hearing loss. *BMC Ear Nose Throat Disord* 2005; 5: 10.
  22. Scherer EQ, Wonneberger K, Wangemann P. Differential desensitization of Ca<sup>2+</sup> mobilization and vasoconstriction by ET(A) receptors in the gerbil spiral modiolar artery. *J Membr Biol* 2001; 182: 183-91.
  23. Kopke RD, Coleman JK, Liu J, Campbell KC, Riffenburgh RH. Candidate's thesis: enhancing intrinsic cochlear stress defenses to reduce noise-induced hearing loss. *Laryngoscope* 2002; 112: 1515-32.
  24. Kopke RD, Jackson RL, Coleman JK, Liu J, Bielefeld EC, Balough BJ. NAC for noise: from the bench top to the clinic. *Hear Res* 2007; 226: 114-25.
  25. Bielefeld EC, Kopke RD, Jackson RL, Coleman JK, Liu J, Henderson D. Noise protection with N-acetyl-L-cysteine (NAC) using a variety of noise exposures, NAC doses, and routes of administration. *Acta Otolaryngol* 2007; 127: 914-9.
  26. Safety data sheet. 2-APB. <https://www.caymanchem.com/msdss/64970m.pdf> (Received: 20 April 2015).