

See discussions, stats, and author profiles for this publication at: <https://www.researchgate.net/publication/286106159>

The protective effect of curcumin on carbon tetrachloride induced liver damage

Article in *Revue de médecine vétérinaire* · July 2014

CITATIONS

13

READS

193

8 authors, including:



Sahver Ege Hismiogullari
Balikesir University

28 PUBLICATIONS 198 CITATIONS

[SEE PROFILE](#)



Adnan Adil Hismiogullari
Balikesir University

27 PUBLICATIONS 123 CITATIONS

[SEE PROFILE](#)



Bahar Sunay
Balikesir University

13 PUBLICATIONS 126 CITATIONS

[SEE PROFILE](#)



Mehmet Can
Balikesir University

3 PUBLICATIONS 33 CITATIONS

[SEE PROFILE](#)

Some of the authors of this publication are also working on these related projects:



Both of them blong to me [View project](#)



biochemistry [View project](#)

The protective effect of curcumin on carbon tetrachloride induced liver damage

S.E. HISMIOGULLARI^{1*}, A.A. HISMIOGULLARI², F.B.SUNAY³, S. PAKSOY⁴, M. CAN⁵, H. AKSIT⁶, O. KARACA⁷, O. YAVUZ²

¹Department of Pharmacology and Toxicology, Faculty of Veterinary Medicine, Balikesir University, Balikesir, Turkey.

²Department of Medical Biochemistry, Faculty of Medicine, Balikesir University, Balikesir, Turkey.

³Department of Histology and Embryology, Faculty of Medicine, Balikesir University, Balikesir, Turkey.

⁴Department of Pathology, Faculty of Medicine, Balikesir University, Balikesir, Turkey.

⁵Department of Anatomy, Faculty of Veterinary Medicine, Balikesir University, Balikesir, Turkey.

⁶Department of Biochemistry, Faculty of Veterinary Medicine, Balikesir University, Turkey.

⁷Department of Anatomy, Faculty of Medicine, Balikesir University, Balikesir, Turkey.

*Corresponding author: sahverege@yahoo.com

SUMMARY

Curcumin, a polyphenolic compound of turmeric has been reported to reduce non-alcoholic steatohepatitis (NASH) and oxidative stress in rats. The aim of the present study was to examine the protective effect of curcumin (CUR) on carbon tetrachloride (CCl₄) – induced NASH and to evaluate the detailed mechanisms by which CUR exerts its protective action. Thirty male Wistar-Albino rats weighing 250-300 g were randomly divided into three groups: Administrations of oral olive oil (control), CCl₄ (0.5 mg/kg in olive oil s.c.) every other day for 3 weeks, and CCl₄ (0.5 mg/kg in olive oil s.c. every other day) plus CUR (200 mg/kg/d, orally in olive oil) every day for 3 weeks. The administration of CCl₄ resulted in steatohepatitis and increased malondialdehyde (MDA) content of the liver. The administration of CUR decreased lipid deposition during histopathological examination and decreased MDA accumulation. These findings indicate that CUR may have a protective role during liver injury occurring with oxidative damages.

Keywords: Liver fibrosis, steatohepatitis, curcumin, carbon tetrachloride, antioxidant, hepatoprotection

RÉSUMÉ

Effet protecteur de la curcumine sur les dommages hépatiques induits par le tétrachlorure de carbone

La curcumine, est un composé polyphénolique du curcuma précédemment signalé comme réduisant la stéatose hépatique non alcoolique (NASH) et le stress oxydatif chez les rats. Le but de la présente étude était d'examiner l'effet protecteur de la curcumine (CUR) sur une hépatite induite par le tétrachlorure de carbone (CCl₄) et d'évaluer les mécanismes par lesquels le CUR exerce son action protectrice. Trente rats albinos Wistar pesant 250-300g ont été répartis au hasard en trois groupes recevant: de l'huile d'olive seule (contrôle), du CCl₄ (0,5 mg/kg dans l'huile d'olive sc) tous les deux jours pendant 3 semaines, et du CCl₄ (0,5 mg/kg dans l'huile d'olive sc tous les deux jours) plus du CUR (200mg/kg/j dans l'huile d'olive oralement) tous les jours pendant 3 semaines. L'administration de CCl₄ a entraîné une stéatose hépatique et augmenté la teneur en malondialdéhyde (MDA). L'administration de la CUR a diminué les dépôts de lipides lors de l'examen histopathologique et diminué l'accumulation de MDA. Ces résultats indiquent que CUR peut avoir un rôle protecteur lors de lésions hépatiques dues à des dommages oxydatifs.

Mots-clés: Fibrose hépatique, stéatose hépatique, curcumine, tétrachlorure de carbone, antioxydant, hépatoprotection

Introduction

The molecular mechanism of CCl₄-induced hepatotoxicity has been well documented. The trichloromethyl free radical (CCl₃·), which is formed in the metabolism of CCl₄ through the cytochrome P450 enzyme system, reacts rapidly with molecular oxygen to produce the trichloromethyl peroxy radical (CCl₃O₂·). This highly toxic radical is responsible for attacks on unsaturated fatty acids of phospholipids present in the cell membrane, leading to lipid peroxidation in the liver cells [45]. Apoptosis also known as programmed cell death, removes the injured cells in the organism without causing any risks to the tissues and organs [37] and during recovery from experimental liver injury, the amounts of activated stellate cells decreases and tissue damage is ameliorated. It has been reported that induction of activated hepatic stellate cells (HSC) apoptosis may cause the elimination of activated HSC for the prevention and treatment of hepatic fibrosis.

Over the years many studies have been conducted investigating the role of antioxidants in experimentally reduced liver damage. We have used the antioxidant curcumin (CUR) which is derived from the plant *Curcuma longa* (turmeric) and is commonly used in food preparation and is reported to display biological activities such as antioxidant [3], anticarcinogenic [3], anti-inflammatory [13] and immunomodulatory activities [29]. Curcumin has been studied in different models of acute and chronic liver injuries, some of which are alcohol-related or carbon tetrachloride-induced liver injuries associated with high levels of oxidative stress and inflammation. However, only limited knowledge is available on the possible effects of curcumin on the development and progression of non-alcoholic steatohepatitis (NASH) and is similar to alcoholic steatohepatitis in term of histopathology and characterized by the presence of signs of hepatocellular damage and inflammation, as well as ballooning degeneration and hepatocyte death, formation of Mallory-Denk bodies, and infiltration with inflammatory

cells [47]. These changes are associated with different degrees of fibrosis or with the presence of cirrhosis. Although some aspects of the pathogenesis of NASH have not been elucidated in detail, others are now well established such as the accumulation of excess lipids particularly in the form of free fatty acids, causes toxic damage to the hepatocytes, which in turn initiates inflammation and tissue repair in the form of fibrosis [9, 25].

The concentration of oxidant and antioxidant components can be measured separately, but the measurement is time-consuming, labor-intensive, costly and requires sophisticated techniques. Due to antioxidant and oxidants molecules have opposite effects, the total antioxidant status [11] (TAS) and the total oxidant status [12] (TOS) can be analyzed by two methods. The present study was conducted to elucidate antioxidative effects of CUR in protecting the hepatotoxic injury caused by CCl_4 in rats.

Materials and Methods

EXPERIMENTAL GROUPS AND MANAGEMENT

Upon the approval of the experimental protocol by the Animal Ethics Committee of the Balikesir University (Protocol #: 09.11.2010-2010/6-9), animals, obtained from Experimental Animals Breeding and Research Center, Ege University, Turkey, were cared in accordance with National Institutes of Health Guide for the Care and Use of Laboratory Animals. Thirty male Wistar-Albino rats age five months and weighing 250-300 g were housed in separate cages at 25°C and subjected to a 12:12-h light:dark cycle. The rats were randomly divided into three groups: Control group (Group 1), subjected to 1ml olive oil administration by gavage for 3 weeks; CCl_4 group (Group 2), subjected to subcutaneous (sc) CCl_4 (Sigma, St. Louis, MO, USA) injection, 0.5 ml/kg of body weight in olive oil on every other day for 3 weeks, and CCl_4 + CUR group (Group 3), subjected to sc CCl_4 injection, 0.5 ml/kg in olive oil every other day for 3 weeks plus 200 mg/kg of body weight curcumin (Sigma, St. Louis, MO, USA) dissolved in olive oil and given by gavage every day for 3 weeks.

All animals were allowed food *ad libitum* and consumption a standard laboratory diet and had free access to water throughout the experimental period. The rats in all groups were anesthetized on day 21 of the CCl_4 administration with sodium pentobarbitone (6mg/100 gr of body weight, intraperitoneal). Blood samples, approximately 3 ml from each animal, were collected from abdominal aorta into routine biochemical tubes for biochemical, total antioxidant status and total oxidant status analyses. Then animals were hepatectomized and the liver was separated for further biochemical analysis and histopathological examination.

BIOCHEMICAL ANALYSES

Serum was separated by centrifuging at 825x g for 10 min and stored at -80°C for analyses of total protein, total antioxidant status (TAS), total oxidant status (TOS) and as well as alanine aminotransferase (ALT, EC 2.6.1.2), aspartate aminotransferase (AST, EC 2.6.1.1) and alkaline phosphatase (ALP, EC 3.1.3.1) activities using commercially available kits in an auto-analyzer (Cobas Integra 800; Roche Diagnostics GmbH; Mannheim, Germany). Serum and liver protein was measured by Lowry method [22]. The liver tissue measurements were expressed as per gram protein for standardization and accuracy.

PREPARATION OF THE LIVER EXTRACT

After weighing, the liver samples (1 g) were transferred to 9% (w/v) of ice-cold buffered sucrose (0.25 M containing 1 mM HEPES pH 7.4.). The liver was cut into several large pieces and swirled around in the buffer to remove blood as much as possible. The liver was minced finely with a sharp scissors and transferred to ice-cold homogenizing vessel and was finally homogenized with about six strokes of the pestle at full speed and the homogenate was made up to 10% (w/v) with sucrose buffer solution. A sample of homogenate (3-4 ml) was centrifuged in a fixed angle rotor at 4°C for 10 min at 6000 xg to obtain supernatant for analyses of enzyme, MDA, TAS and TOS. Liver homogenate was stored at -80°C.

DETERMINATION OF TAS AND TOS LEVELS IN SERUM AND LIVER

Serum and liver TAS and TOS levels were measured spectrophotometrically (PerkinElmer's Lambda 35 UV/Vis, USA) using commercially available kit (Rel Assay Diagnostic, Turkey). The novel automated method is based on antioxidants in the sample reducing dark blue-green colored 2, 2'-Azino-bis (3-ethylbenzothiazoline-6-sulfonic acid) (ABTS) radical to colorless reduced ABTS form [11]. The change of absorbance at 660 nm is related to total antioxidant level of the sample. The assay is calibrated with a stable antioxidant standard solution which is called as Trolox Equivalent that is a vitamin E analog.

The TOS assay is based on oxidants that are present in the sample and oxidize the ferrous ion chelator complex to ferric ion. The oxidation reaction was prolonged by glycerol molecules abundantly present in the reaction medium. The ferric ion produces a colored complex with chromogen in an acidic medium and the colour intensity, which was measured spectrophotometrically, is related to the total amount of oxidant molecules present in the samples [12]. The assay was calibrated with hydrogen peroxide and the results were expressed in term of micromolar hydrogen peroxide equivalent per liter ($\mu\text{mol H}_2\text{O}_2$ Equiv./L) for serum and hydrogen peroxide equivalent per gram protein ($\mu\text{mol H}_2\text{O}_2$ Equiv./g protein) for liver extracts.

CALCULATION OF OXIDATIVE STRESS INDEX (OSI)

The ratio of TOS to TAS was accepted as the OSI. In order to calculate this, the resulting unit of TAS was converted to $\mu\text{mol/L}$, and the OSI value was calculated regarding to the following formula:

$$\text{OSI (arbitrary unit)} = \text{TOS } (\mu\text{mol H}_2\text{O}_2 \text{ Equiv./L}) / \text{TAS } (\mu\text{mol Trolox equivalent/L}) [48].$$

DETERMINATION OF SERUM AND LIVER MALONDIALDEHYDE (MDA) LEVELS

Serum MDA levels were determined based on the spectrophotometric measurement of the product generated upon the reaction of MDA with thiobarbituric acid [37]. The results were expressed as $\mu\text{mol/ml}$. The MDA content of the homogenates was determined according to the method described by Mihara and Uchiyama [26] and the results were expressed as $\mu\text{mol/g protein}$.

HISTOPATHOLOGICAL EXAMINATION

The liver specimens were fixed in a 10% neutral buffered formaldehyde solution. After routine processing the tissue specimens were embedded in paraffin wax and sectioned (thickness, $5 \mu\text{m}$). The sections were stained with hematoxylin and eosine (H&E). Histopathological assessment of the H&E- stained section was examined with Olympus BX-51 light microscope.

TUNEL STAINING FOR DETECTION OF APOPTOSIS

Apoptotic cells in the liver sections were detected with the TUNEL staining using a TUNEL assay kit (Millipore, USA) following the manufacturer's instructions.

SCORING AND STATISTICAL ANALYSIS

The sections were scored as described by Noyan et al. as follows; 0: intact liver; 1: centrilobular necrosis, fatty degeneration; 2: centrilobular and midlobular fatty degeneration, perivenular fibrosis; 3: septal fibrosis, pseudolobule formation; and 4: regenerative nodule formation, cirrhosis [32]. Statistical evaluations were made by using the Mann-Whitney U test and one-way ANOVA after necessary transformation for those data that were not normally distributed (SPSS, version 11.0, Chicago, IL). Group mean differences were attained by the Bonferroni-post hoc test and the effect was considered significant when the p value was < 0.05 .

Results

BIOCHEMICAL FINDINGS

Serum and hepatic biochemical parameters of rats in control, carbon tetrachloride (CCl_4) and curcumin (CUR) + CCl_4 groups are shown in Table-1.

Administration of CCl_4 increased serum activities of ALT and AST, and serum MDA levels as compared to the control group. Concomitant administration of CUR with CCl_4 suppressed the increase in serum ALT, AST, and MDA levels. Serum TAS decreased while TOS increased in rats administered with CCl_4 as compared to rats in the control group. Serum TAS increased and serum TOS decreased to the control levels when CUR was administered concomitantly with CCl_4 . CCl_4 induced elevations in hepatic MDA level and TOS and depression in TAS, which were ameliorated by the CUR treatment (Table-1). CCl_4 increased OSI values both in serum and liver, and CUR when used together with CCl_4 , caused a decrease to the control levels (Table-2).

Parameters	Control Group	CCl_4 Group	CUR + CCl_4 Group
Serum ALT (IU/L)	120.8±4.4	398.6±12.21 ^{a,*}	128.7±3.7 ^{a,**}
Serum AST (IU/L)	60.7±5.7	190.6±14.2 ^{a,*}	70.2±5.9 ^{a,**}
Serum MDA ($\mu\text{mol/L}$)	18.3±3.2	53.4±6.4 ^{b,*}	27.2±3.1 ^{b,**}
Serum TAS (mmol Trolox equiv./L)	15.2±0.2	14.1±0.2 ^{b,*}	17.3±0.3 ^{b,**}
Serum TOS ($\mu\text{mol H}_2\text{O}_2$ Equiv./L)	32.5±8.2	45.05±6.9 ^{b,*}	30.2±5.4 ^{b,**}
Hepatic MDA ($\mu\text{mol/g protein}$)	8.7±1.4	19.9±2.4 ^{a,*}	11.6±1.03 ^{a,**}
Hepatic TAS (mmol Trolox equiv./g protein)	0.226±0.03	0.14±0.01 ^{a,*}	0.212±0.02 ^{a,**}
Hepatic TOS ($\mu\text{mol H}_2\text{O}_2$ Equiv./g protein)	8.7±0.4	12.6±0.8 ^{a,*}	9.1±0.5 ^{a,**}

The data are expressed as mean \pm S.D., (a: $P < 0.01$; b: $P < 0.001$; * compared with control, ** compared with CCl_4), serum aspartate aminotransferase (AST) level, alanine aminotransferase (ALT) level, malondialdehyde (MDA) level, total antioxidant status (TAS) and total oxidant status (TOS) as well as hepatic MDA level, TAS and TOS of rats. Control group received 1 ml olive oil administration by gavage for 3 weeks; CCl_4 group subjected to subcutaneous (sc) CCl_4 injection, 0,5 ml/kg of body weight in olive oil on every other day for 3 weeks, and Cur + CCl_4 group subjected to sc CCl_4 injection, 0,5 ml/kg in olive oil every other day for 3 weeks plus 200 mg/kg of body weight curcumin dissolved in olive oil and given by gavage in every day for 3 weeks.

TABLE I: Serum and hepatic biochemical parameters of rats in control, carbon tetrachloride (CCl_4) and curcumin (CUR) + CCl_4 groups (n=10 per group).

Groups	Control	CCl_4	CCl_4 +CUR
Serum TOS/Serum TAS (arbitrary unit)	19.71	34.65	17.76
Liver TOS/Liver TAS (arbitrary unit)	290	1260	75.83

TABLE II: Oxidative stress index (OSI) of the serum and the livers.

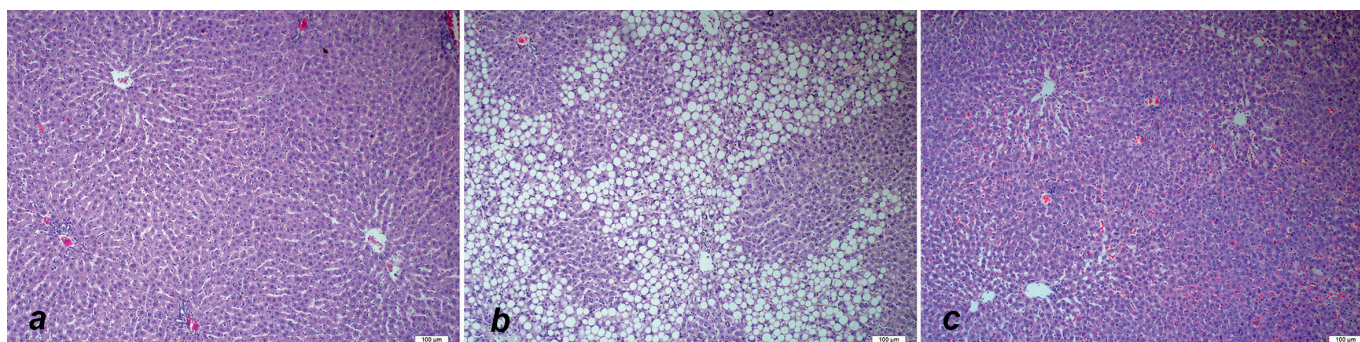


FIGURE 1: Effect of curcumin treatment on rat liver, hematoxylin and eosine. Staining. Representative pictures from the control group (a), CCl_4 group (b) and CCl_4 + Curcumin group (c).

HISTOPATHOLOGICAL FINDINGS

Representative views of liver sections upon CCl_4 induced liver injury and its treatment with CUR is shown in Figure 1. Liver section from the control group showed a normal histological appearance (Figure 1a), whereas livers of rats treated with CCl_4 demonstrated fatty degeneration (Figure 1b). Administration of CUR attenuated fatty degeneration (Figure 1c).

In this study, the severity of fatty degeneration in liver was determined by using a scoring system from 0 to 4. Hepatic damage in CCl_4 + CUR group was reduced to a median histological score of 0 compared with a median score of 1 in CCl_4 group. In Group 2, CCl_4 caused a significant increase in fatty degeneration scores of animals when compared to control animals, and administration of CUR in CCl_4 + CUR group caused a significant decrease in this score. There was no significant difference between control group and CCl_4 + CUR group (Table-3)

DETECTION OF APOPTOTIC CELLS

In this study, TUNEL staining is primarily done for the detection of apoptosis in hepatic satellite cells, owing to the documented apoptotic effect of CUR in these cells [41]. However, there was no difference between study groups neither in apoptosis of hepatic satellite cells, nor hepatocytes (Figure 2).

Discussion

The present study investigated the effect of CUR on oxidative stress markers, TAS, TOS and OSI in conjunction with histopathological and apoptotic analyses of liver in rats treated with CCl_4 . The number of ten rats in each group was designed as the sample size in this study.

The previous experimental studies have shown that treatment with CCl_4 leads to an increase in serum levels of AST, ALT and ALP [2, 24, 31, 40, 43]. The hepatotoxicity of CCl_4 was confirmed in our study by significant increases of

Groups (n=10)	Morphological scores			p values
	Grade 0	Grade 1	Grade 2	
Control	10	-	-	
CCl_4	-	7	3	$p < 0,0001^*$
CCl_4 + CUR	7	3	-	$p < 0,001^\#$ $p = 0,067^\circ$

CCl_4 = carbon tetrachloride; CUR = curcumin; * compared with control; # compared with CCl_4 ; ° compared with control

TABLE 3: Morphological scores in all groups.

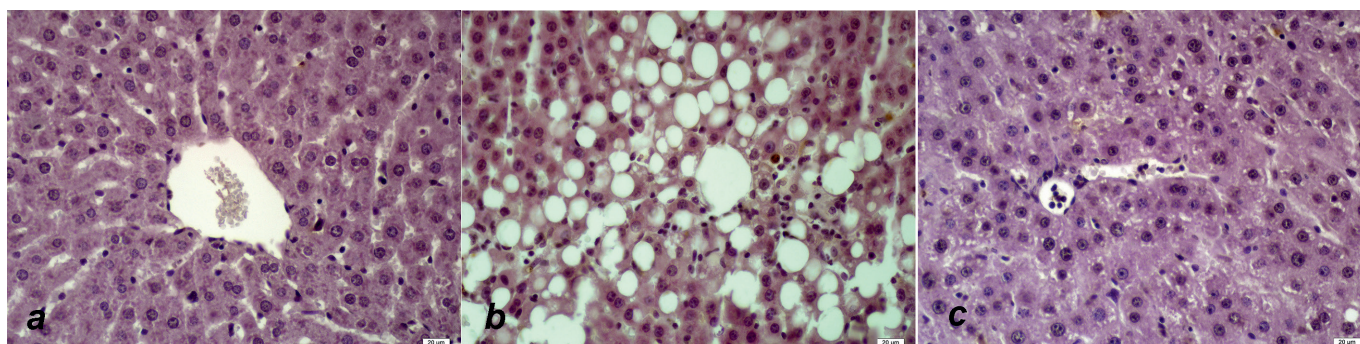


FIGURE 2: Effect of curcumin treatment on the apoptosis of rat liver, TUNEL staining. Representative pictures from the control group (a), CCl_4 group (b) and CCl_4 + Curcumin group (c).

serum levels of AST and ALT. Administration of CUR in rats with hepatic injury, induced by CCl_4 caused a recovery from injury, as evidenced by decrease in the activities of ALT and AST in serum within 3 weeks of treatment. To our knowledge, this study is the first one to determine TAS, TOS and OSI on the protective effects of CUR on CCl_4 -induced NASH. The major advantage of TAS test is to determine the antioxidant capacity of all antioxidants in a biological sample and not just the antioxidant capacity of a single compound [20]. However, the antioxidant property of curcumin has also been reported by hepatic reduced glutathione (GSH) and the ratio of reduced GSH versus oxidized glutathione (GSSG) parameters. GSH has a low molecular weight molecule with thiol group and is the most important non-enzyme antioxidant in mammalian cells [13, 45]. Some studies have reported that it inhibits formation and scavenging of reactive oxygen species (ROS) [1, 10] and reactive nitrogen species [7, 18]. Furthermore, it has been reported that curcumin induces some anti-oxidant enzymes such as glutathione transferase [14], haeme-oxygenase-1 [27] and catalase [14]. Taken these observations together, the antioxidant effects curcumin have been studied partly by different researchers but no studies have reported TAS, TOS and ISO.

The findings in the present study consistently support the notion that administration of CUR protects the liver from CCl_4 -induced steatohepatitis and injury by attenuating hepatic oxidative stress. These results confirmed that CUR significantly elevated the levels of TAS and OSI in serum and liver extract whilst decreasing levels of TOS and MDA in serum and liver extracts in CCl_4 -induced liver injury when compared to CCl_4 group only (Table 1). The results of this study have also demonstrated that CUR significantly reduced pathological changes. Moreover, CUR also significantly decreased the deposition of lipids and normalized the liver changes. HSC presents in the space of Disse and is maintained in a quiescent, non-fibrogenic phenotype in normal liver. It has been reported that curcumin-induced recovery from hepatic injury involves induction of apoptosis of activated the cells [35]. However, there were no significant changes among groups during this duration in apoptosis activities in this rat model (Figure 3). The findings in our study are due to the fact that liver fibrosis did not occur due to the short exposure of the liver to CCl_4 . Priya and Sudhakaran reported that curcumin induced apoptosis only in activated HSCs and not in unactivated HSCs or hepatocytes [35]. In our study, hepatic fibrosis did not occur due to short period of administration CCl_4 to the rats. Therefore, curcumin does not seem to exert apoptosis in CCl_4 -induced-NASH for 21 days.

The mechanism of liver steatohepatitis induced by CCl_4 involves peroxidation of the hepatocyte membrane fatty acids which causes destruction of the cell and their intracellular organelles [6]. CCl_4 is activated by liver cytochrome P450 enzymes to form reactive toxic metabolites which can lead to liver injury *in vivo* which is associated with membrane lipid peroxidation and cell necrosis. MDA which

is a stable metabolite of the free radical associated with lipid peroxidation cascade is commonly used as marker of lipid peroxidation. Our results showed that administration of CCl_4 resulted in a significant increase in MDA production in liver and in serum. The treatment with CUR normalized the increased MDA levels in serum and liver in rats (Figure 1), suggesting that CUR reduced lipid peroxidation in hepatotoxicity, this is in agreements with the results of Basu et al [4]. The study of Park et al [32] also reported similar results that daily administration of 100 mg/kg of curcumin normalized MDA level in acute and subacute rat liver injury induced by CCl_4 .

It has been established that CCl_4 causes necrosis [8, 48], fibrosis [23, 28, 30], mononuclear cell infiltration [37], steatosis and foamy degeneration of hepatocytes, increase in mitotic activity [34] and cirrhosis [31, 43] in liver. Histopathological data also demonstrated alleviation of inflammation and steatosis upon treatment with CUR (Figure 2). Similar results have been reported by Fu et al [13] that curcumin significantly reduces the pathological indexes for hepatocytic death and hepatic injury caused by CCl_4 in the rat model.

Oxidative stress is associated with steatohepatitis [37] and lipid peroxidation and steatohepatitis are significantly attenuated by anti-oxidants such as resveratrol, flavonoid, silymarin or vitamin E. Kowluru et al. [19] reported that the protective effects of curcumin are mediated, in part, by its anti-oxidant defence ability and the scavenging of free radicals; in addition, curcumin is 10 times more active as an anti-oxidant than vitamin E. It has been also shown that CUR decreased the levels of hepatic lipoperoxide formation in both acute and chronic CCl_4 injuries [17, 33]. This alleviation was attributed to CUR's depressive effect on formation of ROS and stimulatory effect on endogenous anti-oxidant activity by its free radical scavenging property [16, 18, 39]. Since ROS and MDA are regarded as inducers of HSC activation [5] the antioxidative properties of CUR may have decreased steatohepatitis in our study (Figure 1). Similarly antioxidant effect of CUR was also shown in rats which developed oxidative stress by thioacetamide administration [38].

In conclusion, the anti-steatohepatitis effect of CUR could be related to its hepatoprotective effects as reflected by reduced MDA and increased TAS through being an antioxidant and exerting anti-inflammatory and free radical scavenger roles, moreover, CUR protects structural and functional integrity of the liver.

References

1. - AK T., GÜLÇİN I.: Antioxidant and radical scavenging properties of curcumin. *Chem. Biol. Interact.*, 2008, **174**, 27-37.
2. - AL-SHABANAH O.A., ALAM K., NAGI M.N., AL-RIKABI A.C., AL-BEKAIRI A.M.: Protective effect of aminoguanidine, a nitric oxide synthase inhibitor,

- against carbon tetrachloride induced hepatotoxicity in mice. *Life Sci.*, 2000, **66**, 265-270.
3. - ANAND P., THOMAS S.G., KUNNUMAKKARA A.B., SUNDARAM C., HARIKUMAR K.B., SUNG B., THARAKAN S.T., MISRA K., PRIYADARSINI I.K., RAJASEKHARAN K.N., AGGARWAL B.B. : Biological activities of curcumin and its analogues (Congeners) made by man and Mother Nature. *Biochem. Pharmacol.*, 2008, **76**, 1590-1611.
 4. - BASU S.: Carbon tetrachloride-induced lipid peroxidation: Eicosanoid formation and their regulation by antioxidant nutrients. *Toxicology*, 2003, **189**, 113-127.
 5. - BATALLER R., BRENNER D.A.: Liver fibrosis. *J. Clin. Invest.*, 2005, **115**, 209-218.
 6. - BOLL M., WEBER L.W., BECKER, E., STAMPFL A.: Mechanism of carbon tetrachloride-induced hepatotoxicity. Hepatocellular damage by reactive carbon tetrachloride metabolites. *Z. Naturforsch. C*, 2001, **56**, 649-659.
 7. - BROUET I., OHSHIMA H.: Curcumin, an anti-tumor promoter and anti-inflammatory agent, inhibits induction of nitric oxide synthase in activated macrophages. *Biochem. Biophys. Res. Comm.*, 1995, **206**, 533-540.
 8. - BURR A.W., CARPENTER M.R., HINES J.E., GULLICK W.J., BURT A.D.: Intrahepatic distribution of transforming growth factor- α (TGF- α) during liver regeneration following carbon tetrachloride-induced necrosis. *J. Pathol.*, 1993, **170**, 95-100.
 9. - CHOI C.S., SAVAGE D.B., KULKARNI A., YU X.X., LIU Z.X., MORINO K., KIM S., DISTEFANO A., SAMUEL V.T., NESCHEN S., ZHANG D., WANG A., ZHANG X., KAHN M., CLINE G.W., PANDEY S.K., GEISLER J.G., BHANOT S., MONIA B.P., SHULMAN G.I. : Suppression of diacylglycerol acyltransferase-2 (DGAT), but not DGAT1, with antisense oligonucleotides reverses diet-induced hepatic steatosis and insulin resistance. *J. Biol. Chem.*, 2007, **282**, 22678-22688.
 10. - DAS K.C., DAS C.K.: Curcumin (diferuloylmethane), a singlet oxygen (1O_2) quencher. *Biochem. Biophys. Res. Commun.*, 2002, **295**, 62-66.
 11. - EREL O.: A novel automated direct measurement method for total antioxidant capacity using a new generation, more stable ABTS radical cation. *Clin. Biochem.*, 2004, **37**, 277-285.
 12. - EREL O.: A novel automated colorimetric method for measuring total oxidant status. *Clin. Biochem.*, 2005, **38**, 1103-1111.
 13. - FU Y., ZHENG S., LIN J., RYERSE J., CHEN A. : Curcumin protects the rat liver from CCl₄-caused injury and fibrogenesis by attenuating oxidative stress and suppressing inflammation. *Mol. Pharmacol.*, 2008; **73**, 399-409.
 14. - IQBAL M., SHARMA S.D., OKAZAKI Y., FUJISAWA M., OKADA S.: Dietary supplementation of curcumin enhances antioxidant and phase II metabolizing enzymes in ddY male mice: Possible role in protection against chemical carcinogenesis and toxicity. *Pharmacol. Toxicol.*, 2003, **92**, 33-38.
 15. - JAESCHKE H.: Cellular adhesion molecules: Regulation and functional significance in the pathogenesis of liver diseases. *Am. J. Physiol. Gastrointest. Liver Physiol.*, 1997, **273**, G602-G611.
 16. - JOE B., VIJAYKUMARA M., LOKESH B.R.: Biological properties of curcumin-cellular and molecular mechanisms of action. *Crit. Rev. Food Sci. Nutr.*, 2004, **44**, 97-111.
 17. - KAMALAKKANNAN N., RUKKUMANI R., VARMA P.S., VISWANATHAN P., RAJASEKHARAN K.N., MENON V.P.: Comparative effects of curcumin and an analogue of curcumin in carbontetrachloride-induced hepatotoxicity in rats. *Basic Clin. Pharmacol. Toxicol.*, 2005, **97**, 15-21.
 18. - KIM J.E., KIM A.R., CHUNG H.Y., HAN S.Y., KIM B.S., CHOI J.S.: In vitro peroxynitrite scavenging activity of diarylheptanoids from *Curcuma longa*. *Phytother. Res.*, 2003, **17**, 481-484.
 19. - KOWLURU R.A., KANWAR M.: Effects of curcumin on retinal oxidative stress and inflammation in diabetes. *Nutr. Metab. (Lond)*, 2007, **4**, 1-8.
 20. - KUSANO C., FERRARI B.: Total antioxidant capacity: a biomarker in biomedical and nutritional studies. *J. Cell. Mol. Biol.*, 2008, **7**, 1-15.
 21. - LAZO M., CLARK J.M.: The epidemiology of nonalcoholic fatty liver disease: A global perspective. *Semin. Liver Dis.*, 2008, **28**, 339-350.
 22. - LOWRY O.H., ROSEBROUGH N.J., FARR A.L., RANDALL R.J.: Protein measurement with the folin phenol reagent. *J. Biol. Chem.*, 1951: **193**, 265-275.
 23. - MACKINNON M., CLAYTON C., PLUMMER J., AHERN M., CMIELEWSKI P., ILSLEY A., HALL, P.: Iron overload facilitates hepatic fibrosis in the rat alcohol/low-dose carbon tetrachloride model. *Hepatology*, 1995, **21**, 1083-1088.
 24. - MANSOUR M.A.: Protective effects of thymoquinone and desferrioxamine against hepatotoxicity of carbon tetrachloride in mice. *Life Sci.*, 2000, **66**, 2583-2591.
 25. - MARRA F., GASTALDELLI A., SVEGLIATI BARONI G., TELL G., TIRIBELLI C.: Molecular basis and mechanisms of progression of non-alcoholic steatohepatitis. *Trends Mol. Med.*, 2008, **14**, 72-81.
 26. - MIHARA M., UCHIYAMA M.: Determination of malonaldehyde precursor in tissues by thiobarbituric acid test. *Anal. Biochem.*, 1978, **86**, 271-278.
 27. - MOTTERLINI R., FORESTI R., BASSI R., GREEN C.J.: Curcumin, an antioxidant and anti-inflammatory agent, induces heme stress. *Free Rad. Biol. Med.*, 2000, **28**, 1303-1312.
 28. - NAKATSUKASA H., NAGY P., EVARTS R.P., HSIA C.C., MARSDEN E., THORGEIRSSON S.S.: Cellular distribution of transforming growth factor- β 1 and procollagen types I, III, IV transcripts in carbon tetrachloride-induced rat liver fibrosis. *J. Clin. Invest.*, 1990, **85**, 1833-1843.

29. - NANJI A.A., JOKELAINEN K., TIPOE G.L., RAHEMTULLA A., THOMAS P., DANNENBERG A.J.: Curcumin prevents alcohol-induced liver disease in rats by inhibiting the expression of NF-kappa B-dependent genes. *Am. J. Physiol. Gastrointest. Liver Physiol.*, 2003, **284**, G321-G327.
30. - NATSUME M., TSUJI H., HARADA A., AKIYAMA M., YANO T., ISHIKURA H., NAKANISHI I., MATSUSHIMA K., KANEKO S., MUKAIDA N.: Attenuated liver fibrosis and depressed serum albumin levels in carbon tetrachloride-treated IL-6-deficient Mice. *J. Leukoc. Biol.*, 1999, **66**, 601-608.
31. - NAZIROGLU M., CAY M., USTUNDAG B., AKSAKAL M. and YEKELER H.: Protective effects of vitamin E on carbon tetrachloride-induced liver damage in rats. *Cell Biochem. Funct.*, 1999, **17**, 253-259.
32. - NOYAN S., CAVUSOGLU I., MINBAY F.Z.: The effect of vitamin A on CCl4-induced hepatic injuries in rats: a histochemical, immunohistochemical and ultrastructural study. *Acta histochemica*, 2006, **107**, 421-434.
33. - PARK E.J., JEON C.H., KO G., KIM J., SOHN D.H. : Protective effect of curcumin in rat liver injury induced by carbon tetrachloride. *J. Pharm. Pharmacol.*, 2000, **52**, 437-440.
34. - PAROLA M., ROBINO G.: Oxidative stress-related molecules and liver fibrosis. *J. Hepatol.*, 2001, **35**, 297-306.
35. - POLI G., PAROLA M. Oxidative damage and fibrogenesis. *Free Radic. Biol. Med.*, 1997, **22**, 287-305.
36. - PRIYA S., SUDHAKARAN P.R.: Curcumin-induced recovery from hepatic injury involves induction of apoptosis of activated hepatic stellate cells. *Indian J. Biochem. Biophys.*, 2008, **45**, 317-325.
37. - SCHULTZ D.R., HARRINGTON W.J.: Apoptosis: Programmed cell death at a molecular level duane. *Semin. Arthritis Rheum.*, 2003, **32**, 345-369.
38. - SERBETCI K., UYSAL O., ERKASAP N., KOKEN T., BAYDEMIR C., ERKASAP S.: Anti-apoptotic and antioxidant effect of leptin on CCl4-induced acute liver injury in rats. *Mol. Biol. Rep.*, 2012, **39**, 1173-1180.
39. - SHAPIRO H., ASHKENAZI M., WEIZMANN N., SHAHMUROV M., AEED H., BRUCK R.: Curcumin ameliorates acute thioacetamide-induced hepatotoxicity. *J. Gastroenterol. Hepatol.*, 2006, **21**, 358-366.
40. - SHARMA R.A., IRESON C.R., VERSCHOYLE R.D., HILL K.A., WILLIAMS M.L., LEURATTI C., MANSON M.M., MARNETT L.J., STEWARD W.P., GESCHER A.: Effects of dietary curcumin on glutathione S-transferase and malondialdehyde-DNA adduct in rat liver and colon mucosa: Relationship with drug levels. *Clin. Cancer Res.*, 2001, **7**, 1452-1458.
41. - SHU J.C., HE Y.-J., LV X., YE G-R, WANG L-X: Curcumin prevents liver fibrosis by inducing apoptosis and suppressing activation of hepatic stellate cells. *J. Nat. Med.*, 2009, **63**, 415-420.
42. - TEOCHARIS S.E., MARGELI A.P., SKALTSAS S.D., SPILIOPOULOU C.A., KOUTSELINIS A.S.: Induction of methallothionein in the liver of carbon tetrachloride intoxicated rats: an immunohistochemical study. *Toxicology*, 2001, **161**, 129-138.
43. - VIZZUTTI F., PROVENZANO A., GALASTRI S., MILANI S., DELOGU W., NOVO E., CALIGIURI A., ZAMARA E., ARE U., LAFFI G., PAROLA M., PINZANI M., MARR F.: Curcumin limits the fibrogenic evolution of experimental steatohepatitis. *Lab. Invest.*, 2010, **90**, 104-115.
44. - WANG G.S., ERIKSSON L.C., XIA L., OLSSON J., STAL P.: Dietary iron overload inhibits carbon tetrachloride-induced promotion in chemical hepatocarcinogenesis: Effects on cell proliferation, apoptosis and antioxidation. *J. Hepatol.*, 1999, **30**, 689-698.
45. - WEBER L.W., BOLL M., STAMPFL A.: Hepatotoxicity and mechanism of action of haloalkanes: Carbon tetrachloride as a toxicological model. *Crit. Rev. Toxicol.*, 2003, **33**, 105-136.
46. - WU G., FANG Y.Z., YANG S., LUPTON J.R., TURNER N.D.: Glutathione metabolism and its implication for health. *J. Nutr.*, 2004, **134**, 489-492.
47. - YEH M.M., BRUNT E.M.: Pathology of non-alcoholic fatty liver disease. *Am. J. Clin. Pathol.*, 2007, **128**, 837-847.
48. - YUMRU M., SAVAS H.A., KALENDEROGLU A., BULUT M., CELIK H., EREL O.: Oxidative imbalance in bipolar disorder subtypes: a comparative study. *Prog. Neuropsychopharmacol. Biol. Psychiatry*, 2009, **33**, 1070-1074.
49. - ZALATNAI A., SAROSI I., ROT A., LAPIS K.: Inhibitory and promoting effects of carbon tetrachloride-induced liver cirrhosis on the diethylnitrosamine hepatocarcinogenesis in rats. *Cancer Lett.*, 1991, **57**, 67-73.