

Traumatic laceration of the portal vein

Ahmet Kama, MD*[‡]; Savas Coskun, MD[†]; Melih Yuksel, MD[§]; Ali Cihat Yildirim, MD[‡]; Elnare Gunal, MD[¶]; Gulsen Cigsar, MD[¶]

ABSTRACT

Despite its relatively protected position, the liver is the most frequently injured solid intra-abdominal organ.¹ Most liver injuries can be managed conservatively, but about 5% to 10% require urgent laparotomy, usually when the mechanism of injury involves a vehicle accident and hemodynamic instability persists, in spite of 40 mL/kg of blood transfusion.^{2,3} In particular, grades IV and V liver injuries may pose a challenge to the surgeon trying to control hemorrhage, the leading cause of mortality.⁴ Traumatic injuries to the portal vein are rare but devastating. The mortality rate for portal vein injury ranges from 50% to 70%. A recent study of portal triad injuries has highlighted the higher mortality rates associated with combination injuries involving multiple portal triad components, especially those that include portal vein injury.⁵ This case study describes a unique case of relatively minor trauma in a child resulting in portal triad injury, sudden demise, and surgical repair.

RÉSUMÉ

Malgré sa position relativement bien protégée, le foie est l'organe solide, intra-abdominal le plus souvent lésé (1). Dans la plupart des cas de lésion traumatique du foie, un traitement conservateur suffit, mais, dans environ 5 à 10 % des cas, il faut procéder à une laparotomie d'urgence, généralement lorsque ces lésions résultent d'un accident de véhicule et qu'elles entraînent une instabilité hémodynamique persistante, malgré des transfusions de sang à raison de 40 ml/kg (2,3). Les lésions hépatiques du 4^e ou 5^e degré en particulier peuvent compliquer la tâche du chirurgien, qui tente de réprimer l'hémorragie, cause principale de mortalité (4).

Les lésions traumatiques de la veine porte sont rares, mais elles peuvent être mortelles. Le taux de mortalité lié aux lésions de la veine porte varie de 50 à 70 %. D'après une étude récente sur les lésions des espaces portes, les taux de mortalité les plus élevés sont associés à la concomitance de blessures touchant plusieurs constituants des espaces portes, notamment la veine porte (5). Sera exposé ici le cas plutôt exceptionnel d'un enfant ayant subi un trauma relativement peu important, qui a causé une lésion des espaces portes, s'est soldé par un effondrement soudain et a nécessité une réparation chirurgicale.

CASE REPORT

A 9-year-old boy was admitted to our hospital with abdominal pain after falling from his bike. His medical history revealed that he fell from his bike facedown 15 minutes before admission. His Glasgow Coma Scale (GCS) was normal at 15. Abdominal examination revealed tenderness on all abdominal quadrants by palpation. Initial vital signs were normal; however, focused assessment with sonography for trauma (FAST) showed common free fluid in the abdomen mainly on perihepatic, Morrison's pouch. His general condition was stable, so abdominal computed tomography (CT) was ordered. The CT scan showed a grade IV liver laceration on the falciform ligament enhancing left portal vein 6 cm in diameter, leading to free fluid (Figures 1, 2, and 3). Laboratory test results revealed that his blood group was O Rh(-) and other parameters were Hb: 10.6 g/dl, Hct: 31.1%, AST: 397 U/L, ALT: 280 U/L. Urgent pediatric surgery consultation was requested. His vital signs declined, and

From the *Emergency Medicine Department, †Department of Pediatric Surgery, and ‡Department of General Surgery, Kars State Hospital, Kars, Turkey; §Emergency Medicine Department, Balikesir School of Medicine, Balikesir, Turkey; and ¶Emergency Medicine Department, Kafkas University School of Medicine, Kars, Turkey.

Correspondence to: Ahmet Kama, Emergency Medicine Department, Kars State Hospital, Kars 36000 Turkey; Email: kama7676@hotmail.com

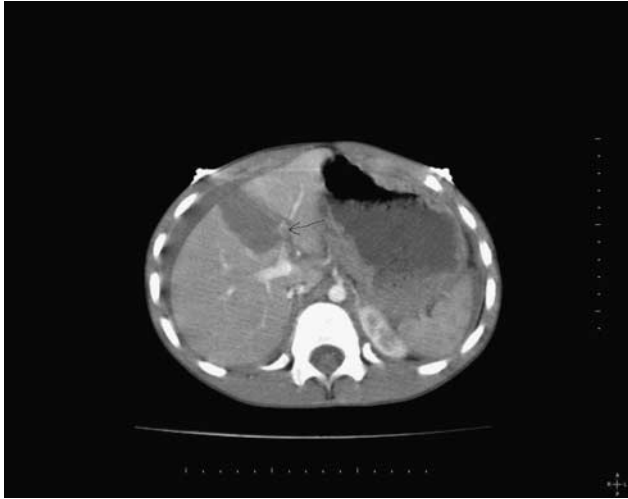


Figure 1. Grade 4 laceration and free fluid.

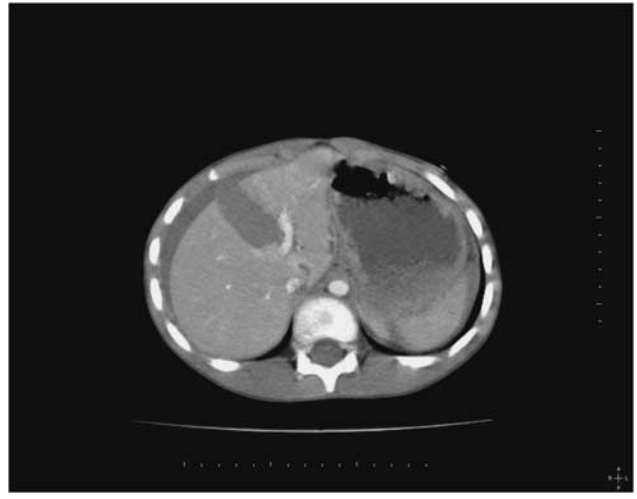


Figure 3. Portal vein laceration.

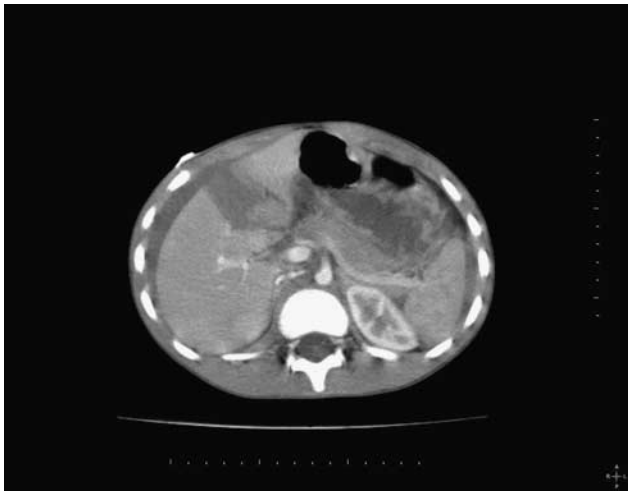

Figure 2. Common free fluid.

hypotension and tachycardia ensued. One unit of O Rh (-) erythrocyte suspension was administered. He became confused and vital signs were as follows: Blood Pressure 60/40 mm/Hg and pulse rate was 136/minute. Perioperative haemoglobin was Hb: 2.75 g/dl and Hct was 13%. On laparotomy one liter of free blood was suctioned by surgeon. Examination revealed total laceration of extrahepatic bile ducts and right lobe, as well as 60% laceration of left lobe. Portal vein sustained a 70% laceration. The portal vein was clamped first, and then repaired by cardiovascular surgeon. Then lacerated liver segments and extrahepatic bile ducts were repaired. Abdomen was closed following placement

of a drain. A total of 12 liters of blood were transfused. He was discharged after full recovery.

DISCUSSION

The portal vein forms as the superior and inferior mesenteric veins join with the splenic vein behind the pancreas. The average portal vein diameter is 2 cm, and this vein has a blood pressure of 10 mm Hg. The injury to the portal vein can be devastating because of the high flow rate, which averages one litre per minute.⁶ Grade I or II injuries are generally considered minor and usually do not require operative treatment, whereas grades III to V injuries are severe and often require operative management. Significant vascular (portal vein or hepatic artery) injuries can be associated with a hematoma or parenchymal laceration (grade III) but usually occur with major parenchymal disruption (grades IV and V).⁷ In their 1995 multi-institutional review of injuries to the portal triad, Jurkovich et al. reported 46 patients with penetrating injuries to the portal triad, including injuries to the portal vein. They reported a 38% survival rate when only the portal vein was injured and an 8% survival rate when other structures in the portal triad were injured. This included a 100% mortality rate for six patients with portal vein and hepatic artery injury. All three of the patients with injuries to the portal vein, extrahepatic bile duct, and hepatic artery died.⁵ Traumatic portal vein injuries are rare and devastating. For 18,900 trauma patients evaluated during a 10-year period, 15 (0.08%) were identified as

having injury to the portal vein. Pearl et al. reported on a case of a 22-year-old male with injuries to the portal vein, hepatic artery, common bile duct, hepatic vein, and pancreas from a gunshot wound. The portal triad injuries, in this case, were managed by primary repair of both the portal vein and hepatic artery with ligation of the right hepatic duct.⁸

Herein, we report the case of traumatic injury of portal vein and extrahepatic bile ducts besides liver laceration in a pediatric patient after a relatively minor trauma and initially presenting with stable vital signs and abdominal pain. As a rare and highly mortal traumatic complication, portal vein injury must be diagnosed and treated urgently; however, the initial presentation in a child may be misleading. It is prudent to consider this injury with abdominal pain after blunt trauma, even when it is considered relatively minor, and pursue appropriate monitoring and evaluation to facilitate urgent intervention, particularly in children.

REFERENCES

1. Coughlin PA, Stringer MD, Lodge JPA, et al. Management of blunt liver trauma in a tertiary referral centre. *Br J Surg* 2004;91(3):317-21.
2. Salat JA, Grisoni ER, Gauderer MWL. Pediatric blunt liver injury: establishment of criteria for appropriate management. *J Pediatr Surg* 1990;25(11):1162-5.
3. Gross M, Linch F, Canty T, et al. Management of pediatric liver injuries: a 13 years experience at a pediatric trauma center. *J Pediatr Surg* 1999;34(5):811-7.
4. Moore EE, Shackford SR, Pachter HL, et al. Organ injury scaling. *J Trauma* 1989;29(7):1664-6.
5. Jurkovich GJ, Hoyt DB, Moore FA, et al. Portal triad injuries. *J Trauma* 1995;39(3):426-34.
6. Dawson DL, Johansen KH, Jurkovich GJ. Injuries to the portal triad. *Am J Surg* 1991;161(5):545-51.
7. Badger SA, Barclay R, Campbell P, et al. Management of liver trauma. *World S Surg* 2009;33(12):2522-37.
8. Pearl J, Chao A, Kennedy S, et al. Traumatic injuries to the portal vein: case study. *J Trauma Inj Infect Crit Care* 2004; 56(4):779-82.