

Basic Study

Impact of sorafenib on epidural fibrosis: An immunohistochemical study

Osman Tanriverdi, Uzay Erdogan, Canan Tanik, Ilhan Yilmaz, Omur Gunaldi, Huseyin Utku Adilay, Ayca Arslanhan, Metehan Eseoğlu

Osman Tanriverdi, Uzay Erdogan, Omur Gunaldi, Department of Neurosurgery and Psychiatry, University of Health Sciences, Bakırköy Prof. Dr. Mazhar Osman Training and Research Hospital for Neurology, İstanbul 34303, Turkey

Canan Tanik, Department of Pathology, University of Health Sciences, Şişli Hamidiye Etfal Training and Research Hospital, İstanbul 34303, Turkey

Ilhan Yilmaz, Department of Neurosurgery, University of Health Sciences, Şişli Hamidiye Etfal Training and Research Hospital, İstanbul 34303, Turkey

Huseyin Utku Adilay, Department of Neurosurgery, Medical Faculty, Balıkesir University, Balıkesir 31300, Turkey

Ayca Arslanhan, Institute of Neurological Science, Marmara University, İstanbul 34303, Turkey

Metehan Eseoğlu, Department of Neurosurgery, Medical Faculty, Medipol University, İstanbul 34303, Turkey

ORCID number: Osman Tanriverdi (0000-0002-4846-4213); Uzay Erdogan (0000-0001-8268-6306); Canan Tanik (0000-0003-2435-7533); Ilhan Yilmaz (0000-0001-5548-2228); Omur Gunaldi (0000-0001-5071-1319); Huseyin Utku Adilay (0000-0003-4867-244X); Ayca Arslanhan (0000-0002-3980-0609); Metehan Eseoğlu (0000-0003-0260-1988).

Author contributions: Tanriverdi O contributed to the conception, design, supervision and writing; Erdogan U contributed to the literature review and data collection; Tanik C contributed to the design, data collection, analysis and processing; Yilmaz I contributed to the writing and literature review; Gunaldi O contributed to the critical review and supervision; Adilay HU contributed to the data collection and materials; Arslanhan A contributed to the materials and data collection; Eseoğlu M contributed to the literature review, materials and data collection.

Institutional animal care and use committee statement: Marmara University Local Ethics Committee for Animal Studies.

Conflict-of-interest statement: The authors declare that they have no conflict of interest.

Open-Access: This article is an open-access article which was selected by an in-house editor and fully peer-reviewed by external reviewers. It is distributed in accordance with the Creative Commons Attribution Non Commercial (CC BY-NC 4.0) license, which permits others to distribute, remix, adapt, build upon this work non-commercially, and license their derivative works on different terms, provided the original work is properly cited and the use is non-commercial. See: <http://creativecommons.org/licenses/by-nc/4.0/>

Manuscript source: Unsolicited manuscript

Correspondence to: Osman Tanriverdi, MD, Doctor, Department of Neurosurgery and Psychiatry, University of Health Sciences, Bakırköy Prof. Dr. Mazhar Osman Training and Research Hospital for Neurology, Tevfik sağlam cad, No. 1, İstanbul 34303, Turkey. osmantanriverdi74@gmail.com
Telephone: +90-505-2964052

Received: April 27, 2018

Peer-review started: April 27, 2018

First decision: June 15, 2018

Revised: June 23, 2018

Accepted: July 31, 2018

Article in press: August 1, 2018

Published online: September 6, 2018

Abstract

AIM

To determine if sorafenib, an antineoplastic agent, could prevent the development of spinal epidural fibrosis (EF).

METHODS

The study used CD105 and osteopontin antibodies

in an immunohistochemical approach to quantify EF that occurred as a consequence of laminectomy in rats. Wistar albino rats ($n = 16$) were divided into two groups: control (L1-2 level laminectomy only) and sorafenib treatment (L1-2 level laminectomy + topical sorafenib). The animals were euthanized after 6 wk, and the EF tissues were examined for histopathological changes after immunohistochemical staining. The EF grades were assigned to the tissues, and the treatment and control groups were compared.

RESULTS

The EF thickness, inflammatory cell density, and arachnoid adhesions determined by light microscopy were significantly higher in the control group compared to the sorafenib-treated group. Based on fibrosis scores, the extent of EF in the treatment group was significantly lower than in the controls. Immunohistochemical staining for CD105 to identify microvessels revealed that the EF grades based on vessel count were significantly lower in the treatment group. Staining for osteopontin did not show any significant differences between the groups in terms of the extent of EF. The staging of EF based on vascular counts observed after immunohistochemical staining for CD105, but not for osteopontin, was compatible with conventional staging methods. Neither toxic effects on tissues nor systemic side effects were observed with the use of sorafenib.

CONCLUSION

Local administration of sorafenib significantly reduced post-laminectomy EF. Decreased neovascularization in spinal tissue may be due to the sorafenib-induced inhibition of vascular endothelial growth factor.

Key words: Vascular endothelial growth factor; CD105; Osteopontin; Sorafenib; Spinal epidural fibrosis

© **The Author(s) 2018.** Published by Baishideng Publishing Group Inc. All rights reserved.

Core tip: This study addressed the prevention of spinal epidural fibrosis (EF) by sorafenib, an antineoplastic agent, though immunohistochemical analyses of EF as a consequence of laminectomy in rats. The study demonstrated for the first time that the fibrosis thickness, inflammatory cell density, arachnoid adhesions, fibrosis scores, and vessel count were significantly lower in the treatment group. These findings indicate that locally administered sorafenib may help reduce spinal EF after laminectomy without any significant complications or side effects.

Tanriverdi O, Erdogan U, Tanik C, Yilmaz I, Gunaldi O, Adilay HU, Arslanhan A, Esegolu M. Impact of sorafenib on epidural fibrosis: An immunohistochemical study. *World J Clin Cases* 2018; 6(9): 249-258 Available from: URL: <http://www.wjgnet.com/2307-8960/full/v6/i9/249.htm> DOI: <http://dx.doi.org/10.12998/wjcc.v6.i9.249>

INTRODUCTION

One of the complications that occurs most frequently after laminectomy is epidural fibrosis (EF)^[1]. EF causes reoccurrence of symptoms because of post-operation nerve root tensioning or compression^[2]. A second operation is often required to remove scar tissue, and it is both difficult and has a high rate of complications^[1,3,4]. A majority of authors believe that to avoid surgical treatment, EF should be prevented before it occurs^[5,6]. Several studies have previously addressed the effects of various compounds on EF after laminectomy in rat^[2,7-10] and rabbit^[11] models, on renal fibrosis^[12], and on liver fibrosis^[13]. Many of these drugs are still in the development stage, and some of them are intended to inhibit the mechanism underlying fibrosis development. The multi-kinase inhibitor sorafenib is an antineoplastic drug with secondary antifibrotic and antiangiogenic activity *via* inhibition of vascular endothelial growth factor (VEGF)^[13]. Although the antifibrotic effectiveness of sorafenib is well known, there is no literature to our knowledge of its utilization in spinal surgery^[12,13].

Chemotactic factors arising from the disintegration of erythrocytes and thrombocytes following bleeding in the epidural region after laminectomy, as well as fibroblast migration arising from paraspinal muscles, are the main causes of EF. Adhesions can also form due to fibrous connective tissue hyperplasia when fibroblasts are activated by inflammatory cytokines and growth factors, primarily transforming growth factor- β (TGF- β) and basic fibroblast growth factor, to repair the local defect in the vertebral lamina. With collagen fibril production, fibrous connective tissue is transformed into scar tissue, leading to the development of fibrositis^[14].

Tyrosine kinase (TK) inhibitors are a group of small molecules that have gained considerable importance in recent years for the prevention of angiogenesis. Sorafenib is one such antineoplastic drug, and it reduces the proliferation of tumor cells through its antiangiogenic effect *via* multi-kinase inhibition^[15]. Its principal targets are the Raf/ERK, VEGFR and PDGFR- β pathways^[13]. It has been shown that sorafenib can inhibit a great number of intracellular (c-CRAF, BRAF and mutant BRAF) and cell surface kinases (KIT, FLT-3, RET, VEGFR-1, VEGFR-2, VEGFR-3 and PDGFR-B) (Figure 1). It is therefore thought that some of these kinases may take part in tumor cell signal transmission, angiogenesis and apoptosis. Sorafenib selectively inhibits the VEGF receptor tyrosine kinase (TK). Due to this antiangiogenic effect, it has become one of the most effective drugs in cancer treatment^[16]. Moreover, in recent years, sorafenib has conspicuously improved liver transplantation and conventional treatment methods of all other non-malignant fibrotic diseases like fibrosis caused by end-stage liver cirrhosis^[13,17,18]. In the current study, we have investigated whether the antiangiogenic effect of sorafenib *via* VEGF receptor blockade could also prevent

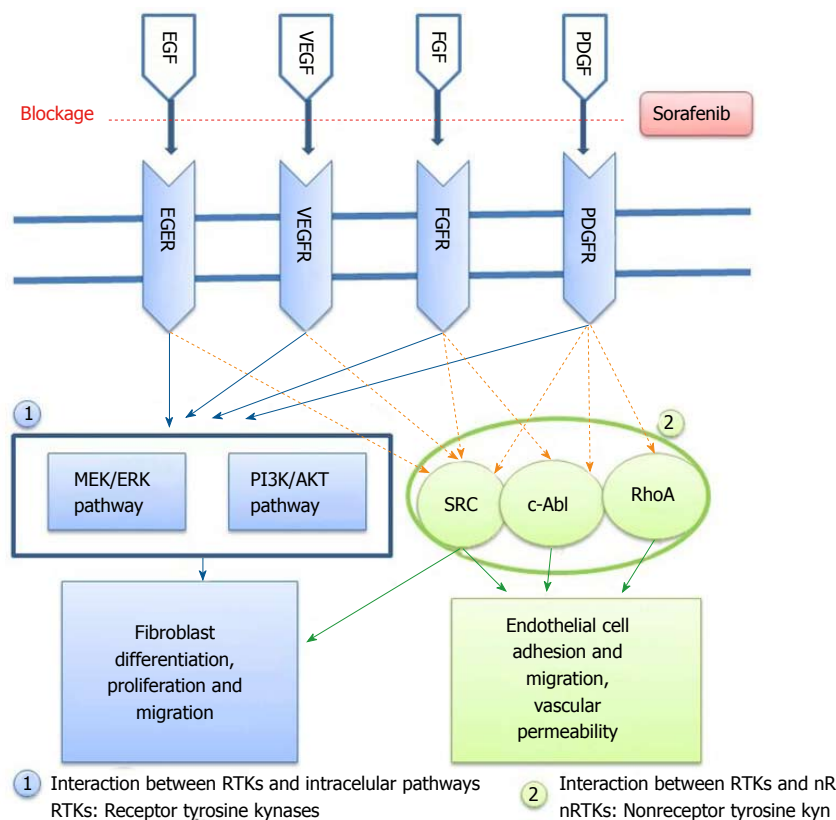


Figure 1 Fibrosis development mechanism and the stage at which sorafenib prevents fibrosis is indicated. VEGF: Vascular endothelial growth factor.

the development of experimental EF without toxic effects when applied locally to peripheral tissues.

CD105, also known as endoglin, is a membrane glycoprotein that regulates the signaling of TGF- β 1^[19]. It was first defined as a human endothelial cell marker produced by pre-B cell leukemia cell lines^[20]. Further studies have indicated that this cell surface antigen is also expressed by macrophages, erythroid precursors, syncytiotrophoblasts of terminal placenta and stromal cells^[20-23]. Previous studies have revealed that in various models of EF, CD105 expression could prevent the fibrogenic impact of TGF- β 1^[19,24]. In biopsies of patients with kidney and liver fibrosis, an excessive amount of CD105 expression was seen, and its role in regulating fibrogenesis was thus realized^[20,25]. In the light of the above information, CD105 levels may be useful in determining the density of microvessels and the extent of angiogenesis in fibrosis. Unfortunately, there is no literature available to our knowledge on the use of CD105 immunostaining for the examination of EF after laminectomy. Given the role of CD105 in angiogenesis and its expression in fibrosis and in macrophages, we examined its use as a marker of EF post-laminectomy at different stages in the development of EF.

Osteopontin is a glycoposphoprotein that was first isolated from bone tissue and possesses a number of functions affecting various cells including macrophages, epithelial cells, smooth muscle cells and endothelial

cells. High levels of osteopontin have been found in bone tissue, blood, milk, urine and seminal fluid^[26]. It is secreted from embryonic stroma and from fibroblasts during wound healing^[27]. Since osteopontin is secreted from inflammatory cells, fibroblasts and endothelial cells, it may be helpful in determining the presence of fibrosis^[28]. We therefore analyzed whether osteopontin expression post-laminectomy could be used for the immunohistochemical detection of EF and if its use was compatible with conventional methods of EF assessment.

In the present study, we have investigated the preventive effect of sorafenib on the development of EF after laminectomy. In addition to conventional methods showing the number of fibroblasts and the prevalence of fibrosis, we employed immunohistochemical staining for CD105 and osteopontin to analyze the extent of EF and assessed whether these methods were compatible with conventional EF staging methods.

MATERIALS AND METHODS

The study was performed at the Marmara University Experimental Animals Laboratory (İstanbul, Turkey) and was approved by the Marmara University Animal Experiments Research Ethics Committee (04.01.2016/001). All necessary precautions were taken to minimize pain and discomfort in animals throughout the procedures of the study. Male Wistar albino rats ($n = 16$, weight 250

Table 1 Grading criteria for histopathological assessment of scar tissue by He *et al.*^[29]

Grade	Width of the scar tissue
0	No scar tissue in dura mater
1	Thin fibrosis bands present between scar tissue and dura mater
2	Adhesions holding 2/3 of the laminectomy defect present
3	Widespread scar. More than 2/3 of the laminectomy defect affected

g ± 30 g, 10-12 mo) were housed in an air-conditioned room with an average temperature of 23 ± 2°C and an average humidity of 65%-70%, under a 12-h light-dark cycle. Each animal was kept in a separate cage throughout the study with food provided *ad libitum* and without any medical treatment after the initial operation. Surgical intervention was performed using standard microsurgical instruments.

Surgical procedure

A prophylactic dose of 50 mg/kg ceftriaxone (Rocephine; Roche, İstanbul, Turkey) was intraperitoneally injected 30 min before surgery. General anesthesia was applied by intraperitoneal administration of 100 mg/kg ketamine hydrochloride (Ketalar, 50 mg/mL; Parke-Davis, Eczacıbaşı, İstanbul, Turkey) + 10 mg/kg xylazine hydrochloride (2% Rompun; Sigma-Aldrich, Merck, İstanbul). After fastening the rat to the operating table, the operating area was disinfected with povidone iodine (Poviod, 10% polyvinyl pyrrolidone-iodine complex; Saba, İstanbul, Turkey). The operating area was covered with sterile cloths. Upon determining the L1-2 level, an approximately 2-2.5 cm central line skin incision was made. Para-spinal muscles were stripped by blunt dissection. Under a surgical microscope, total laminectomy was performed within an approximately 4 mm² area between L1 and L2, and the dural sac was revealed. Throughout the operation, the wound was irrigated with saline and hemostasis was ensured. Bipolar cautery, bone wax, surgical or other hemostasis materials were not used. Experimental animals were divided equally (*n* = 8 per group) between the control group (Group I) with laminectomy performed at the L1-2 level and physiologic saline applied, and the treatment group (Group II) with laminectomy performed at the L1-2 level and topical sorafenib (Nexavar; Bayer and Onyx Pharmaceutical, Berlin, Germany) applied. Because sorafenib is produced in the form of 200 mg tablets and its injectable type was not available, we administered sorafenib in the form of a diluted topical treatment. Following the advice of the manufacturer, a 200 mg tablet was dissolved in 5 cc saline and applied *via* impregnated cotton sponge to the laminectomy area for 5 min. The incision area was then sutured with 3/0 silk in conformity with its anatomy. Experimental and control animals were euthanatized by cervical disloca-

tion 6 wk later. The motor functions of all animals was normal at the time of euthanasia, and no postoperative infection or other systematic pathology was evident. The relevant vertebral columns were removed as a block together with the paraspinal muscles. The tissue was fixed in 10% formalin (4% formaldehyde) solution.

Histopathological examination was performed by a qualified pathologist. The amount of fibrosis in the laminectomy area in relation to dura mater was assessed in conformity with standard immunohistochemical criteria and classifications in the literature. Comparisons were made within groups and between control and treatment groups, and results were compiled and statistically interpreted.

Histopathological assessment

After fixation for 24 h in 10% buffered formalin, the vertebral column was removed as a block and decalcified in 10% formic acid for 2 d. Three specimens were taken from the area in which laminectomy was performed, and these specimens were subjected to Leica 300S "autotechnikon" routine tissue monitoring after washing for 6 h under running water. Paraffin blocks were sectioned at a thickness of 3 mm, and sections were stained with hematoxylin-eosin (HE) for inspection under a light microscope with respect to the prevalence of fibrosis, cellular density and arachnoid fibrosis. Fibrosis staging at the dura was performed according to He *et al.*^[29] (Table 1). Fibroblasts at 100 X magnification were counted by pathologists in three fields per specimen, one in the middle and two at the edge of the laminectomy (Figure 2A). The average number of fibroblasts and inflammatory cells in the three fields were graded as follows: Grade 1, less than 100 fibroblasts/inflammatory cells per field; Grade 2, 100-150 fibroblasts/inflammatory cells per field; Grade 3, more than 150 fibroblasts/inflammatory cells per field. To verify the quantification of fibroblast numbers, immunohistochemistry was performed using monoclonal anti-vimentin antibody 1:100 (Vimentin clone: V9, LEICA Biosystems Newcastle Upon Tyne, United Kingdom), and the density of vimentin was evaluated^[6]. Similarly, inflammatory cell density was assessed at 40 X (Figure 2B and C). Furthermore, we evaluated the sections for bone renewal, winding of the nerve root and adhesions between dura and arachnoid.

Immunohistochemical assessment

Microvessel density in the specimens was determined based on immunostaining with anti-osteopontin and anti-CD105 monoclonal antibodies. Paraffin-embedded tissues fixed in 10% formalin were sectioned at 3-5 mm and mounted onto poly-L-lysine-coated slides. The immunohistochemical study was done in the Leica Bond III. The slides were kept at 80°C in the incubator for 3 h and installed in the Bond III device. For the primary antibodies, 1/400 dilution was prepared from CD105

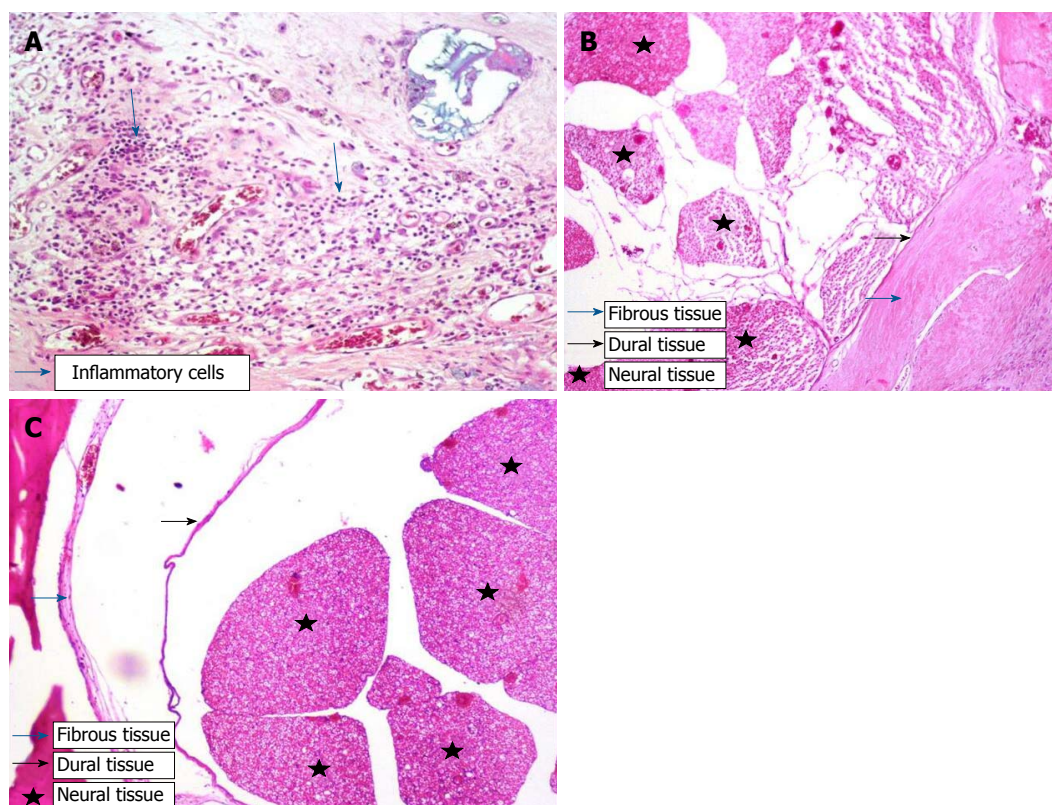


Figure 2 Histopathological tissue section stained by HE. A: Grade-3 fibrosis and inflammatory cells in Group I; B: Grade-3 fibrosis and fibrous tissue in Group I; C: Grade 1 fibrosis in Group II. Star: Neural tissues; black arrow: Dura; blue arrow: Fibrosis tissue.

(Clone EP274, catalog number AC-0243A, Epitomics, Burlingame, CA, United States) and 1/100 dilution was prepared for osteopontin (Clone EP106, catalog number AC-0102RUO; Epitomics, Burlingame, CA, United States). After automatized coloring, the slides were kept in xylene for 3 min and sealed.

Assessment of microvessel density

Using an Olympus (Shinjuku, Japan) CX41 light microscope, tissue sections immunostained with anti-CD105 and anti-osteopontin were scanned at 40X and 100X in three different areas where the density of neovascularization was the highest (hot spot). A single brown-stained endothelial cell or interconnected endothelial cell cluster separate from fibrosis and other connective tissue components at 400 X magnification, irrespective of lumens, was considered a countable microvessel (Figures 3A and B; 4A and B). Every experimental animal was classified in accordance with the number of stained vessels (Table 2) observed at 400 X magnification as follows: Grade 1, ≤ 3 vessels; grade 2, 4-6 vessels; and grade 3, ≥ 7 vessels. Vessels in the muscle layer were not included in the counts. The average number of vessels in three areas was calculated as the vessel density.

Statistical analysis

SPSS 15.0 for Windows (IBM, Armonk, NY, United

States) was used for statistical analysis. Descriptive statistics were given as percentages for categorical variables. Differences in the proportional rates of categorical variables between groups were tested by chi-square analysis. In cases where the conditions could not be ensured, Monte Carlo simulation was implemented. Statistical significance was accepted as $P < 0.05$. All statistical procedures were carried out by an experienced biostatistician at Arat Biostatistics LLC (Istanbul, Turkey) through outsourcing.

RESULTS

Significant differences ($P < 0.001$) in fibrosis score, fibroblast density, inflammatory cell density and CD105 immunostaining were observed between the sorafenib and control groups (Table 3). All control animals (Group I) received fibrosis scores of grade 3, while scores for sorafenib-treated animals (Group II) did not exceed grade 1 ($P < 0.001$) (Figure 2A and B, Table 3). Fibroblast density was graded the highest in 100% of Group 1 animals but remained at grade 1 in Group II. Scores for inflammatory cell density were lowest in Group II but highest in Group I, as were scores for microvessel density assessed by CD105 immunostaining ($P < 0.001$) (Figure 3A and B, Table 3). There was no significant difference in microvessel density scores between groups after osteopontin staining ($P = 0.355$)

Table 2 Microvessels visualized by CD105 immunostaining

Grade	Average number of microvessels (400 x)
1	≤ 3
2	4-6
3	≥ 7

(Figure 4A and B, Table 3). By light microscopy, it could be seen that EF thickness, inflammatory cell density and arachnoidal adhesions were greater in control animals compared to Group II (Table 3).

DISCUSSION

EF is a major cause of failed back/lumbar surgery syndrome, which is often witnessed post-laminectomy^[1,2]. Because treatment of EF is difficult and complication rates are high, ongoing studies have examined how to prevent its development. The role of angiogenesis in the development of fibrosis is known, with VEGF acting as a potent angiogenic agent^[30]. Sorafenib inhibits VEGF in neoplastic cells and blocks angiogenesis, causing the death of tumor cells. The same mechanism is also applicable in the development of EF, and it has been shown that sorafenib prevents or inhibits the development of fibrosis in the liver and the kidney^[13,19,31].

In the present study, the level/degree of EF was classified separately based on fibrosis scores, the density of fibroblasts and inflammatory cells, and counts of microvessels immunostained for either CD105 or osteopontin. Our results showed that EF developed to various extents in all control animals, indicating that experimental EF was successfully produced. The local application of sorafenib reduced the level and degree of EF compared to the control animals. We also found that the scoring of EF based on counts of osteopontin-stained microvessels did not agree with other measures used.

EF is a normal process with respect to the local repair of surgical laminectomy, but its role in the production of epidural scar tissue has been controversial^[2,10,14]. Clinical studies and results from the animal experiments have shown that many factors are related to the development of post-operative peridural scar tissue including postoperative hematoma, laminectomy technique, amount of bone removed and the relation of lamina to other anatomic structures^[2,32]. However, the main factor in the creation of peridural scar tissue is fibroblast migration to the surgical area^[32]. Theoretically, the augmentation of vascular permeability in the early phase of wound repair allows for the accumulation of fibrin-rich matrix required for cellular migration and proliferation^[2,33]. The angiogenic response is characteristic of the early wound-repair phase and ensures vascularity, which nourishes newly formed granulation tissue. The most potent stimulant of angiogenesis is VEGF. In addition, other growth factors including FGF, PDGF,

angiopoietin 1 and 2 and hepatocyte growth factor stimulate angiogenesis through TK receptors^[30]. Furthermore, it is known that VEGF is helpful for vascularization in the postoperative damaged area and plays a key role in adhesion formation^[8,10].

Sorafenib, a TK inhibitor, has been certified by the FDA for use as an antineoplastic agent demonstrating VEGF inhibitory and antiangiogenic effects. In work carried out by Ma *et al.*^[12], it was reported that sorafenib exerted an antifibrotic effect on the kidney and that this effect occurred as the result of its prevention of macrophage migration. In the present study, we showed through immunohistochemical staining that sorafenib applied locally to the surgical area prevented neovascularization in damaged postoperative tissue, thereby inhibiting or preventing EF. Furthermore, sorafenib did not produce any toxic effects on the dura, paraspinal muscles or other tissues.

One method to determine the level of angiogenesis in a tumor and/or fibrotic lesion is to directly measure the density of microvessels and veins in the tissue. An increase in the number of microvessels indicates that angiogenesis is strong^[34]. Detection of microvessels in fibrotic tissue is possible by making the vessels visible after staining for proteins in the membranes of endothelial cells using immunohistochemical methods. CD105 is a potential immunohistochemical marker for the detection of microvessel density, which is associated with endothelial cells in angiogenic tissues and usually produces little or only weak color when used for immunohistochemical staining in normal tissue. It is this fact that makes anti-CD105 a useful antibody for the evaluation of angiogenesis or angiogenic potential^[35,36]. In our study, we showed that the staging of EF using fibroblast counts and fibrosis density produced similar results as counting CD105-stained microvessels. Thus, CD105 is a suitable marker for immunohistochemical detection of EF.

Another potential immunohistochemical marker for the detection of fibrosis is osteopontin. While osteopontin is expressed by epithelium, endothelium and smooth muscle cells, it is also expressed by macrophages and T cells with infiltration features^[26]. Osteopontin plays a significant role during acute and chronic inflammation when its anti-inflammatory effect can prevent inflammation or alleviate its severity^[26]. Osteopontin is essential for cell viability and protects against apoptosis^[26]. There are reports of excessive expression of osteopontin in human idiopathic pulmonary fibrosis, interstitial fibrosis in the diabetic kidney and alcoholic liver illness even though full deterioration did not occur in the healing wound and the number of irregular collagen fibrils was less than normal^[27,28,31,37,38]; however, other reports claimed that the elimination of tissue debris was a slower than normal process^[27]. Pereira *et al.*^[28] reported that osteopontin did not show equal distribution in all tissues and that its presence might be directly related

Table 3 Grading of fibrosis and statistical results based on various criteria

Assessment measure	Grade	Control (Group 1)		Sorafenib (Group 2)		P
		n	%	n	%	
Fibrosis score	0	0	0	4	50	< 0.001
	1	0	0	4	50	
	3	8	100	0	0	
Fibroblast density	1	0	0	8	100	< 0.001
	3	8	100	0	0	
	1	0	0	6	75	
Inflammatory cell density	2	2	25	2	25	< 0.001
	3	6	75	0	0	
	1	0	0	6	75	
CD105-stained microvessels	2	2	25	2	25	< 0.001
	3	6	75	0	0	
	1	4	50	7	87.5	
Osteopontin-stained microvessels	2	2	25	1	12.5	0.355
	3	2	25	0	0	

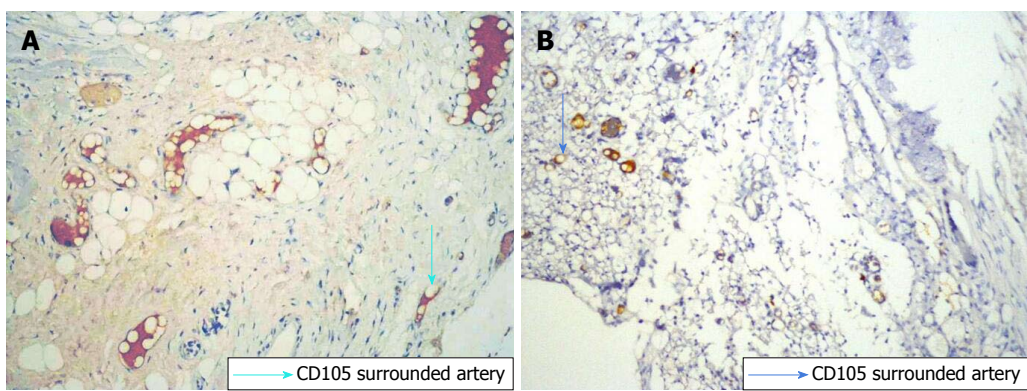


Figure 3 Immunohistochemical tissue section stained with anti-CD105 antibody. A: Grade-3 fibrosis in Group I ; B: Grade-1 fibrosis in Group II . blue arrow: Fibrosis.

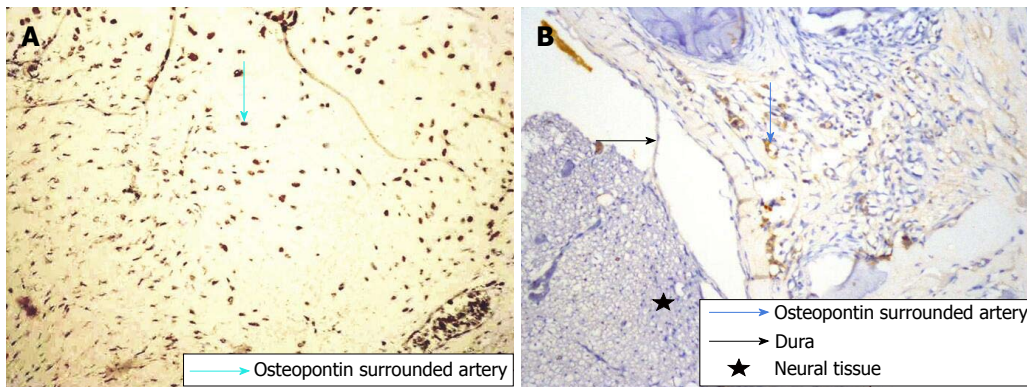


Figure 4 Immunohistochemical tissue section stained with anti-osteopontin antibody. A: Grade-3 fibrosis in Group I ; B: Grade-1 fibrosis in Group II . Star: Neural tissues; black arrow: Dura; blue arrow: Fibrosis tissue.

to pathophysiology during wound healing and formation of scar tissue. Another study suggested that inhibition of osteopontin synthesis, oscillation or local activity after spinal surgery diminished EF and the frequency of symptoms^[28]. In our study, osteopontin levels did not significantly correlate with histopathological EF evaluation methods or immunohistochemically determined CD105 levels. Consequently, osteopontin cannot be considered

a reliable marker for the immunohistochemical detection of EF.

To the best of our knowledge, there have not been any studies that investigate the impact of sorafenib on spinal EF. Nevertheless, other research on tumors has shown that the anti-angiogenic effect of VEGF inhibition can reduce neovascularization and make an affirmative contribution to life span^[39]. We have reached

a similar conclusion in our study. Sorafenib decreased neovascularization in damaged tissue and thus significantly reduced the development of EF as shown using the CD105 antibody, although osteopontin was not a reliable marker.

Secondary operations required because of EF are both challenging and have a high complication rate^[1,3,4]. Braverman *et al.*^[40] reported a success rate of only 30%-35% in operations performed by them to correct EF and observed adverse results in 10%-20% of cases. Rather than removing or relieving the pressure created by EF, it would be a far better approach to prevent EF from the start^[5].

In conclusion, the data obtained from our study showed that when sorafenib was locally applied post-laminectomy, EF was significantly reduced. The staging of fibrosis evaluated by immunohistochemical staining for CD105 was compatible with conventional methods, but staging using osteopontin was not reliable. Neither toxic effects on tissues nor systematic side effects were observed with the use of sorafenib. Therefore, there should be no hindrance to the application of sorafenib for clinical purposes.

ARTICLE HIGHLIGHTS

Research background

Spinal epidural fibrosis (EF) is a natural consequence of surgical trauma arising after laminectomy. In this study, we asked whether sorafenib can prevent the development of EF post-laminectomy using an immunohistochemical approach to quantify EF with CD105 and osteopontin antibodies.

Research motivation

EF is one of most common causes of failed back surgery syndrome, which occurs after laminectomy. Numerous causes and mechanisms have been proposed to explain its development after laminectomy. As treatment approaches for EF are associated with high rates of complications and failed surgery, the main goal is the prevention of EF. Many methods and medicines have been tried in order to prevent the development of EF. Sorafenib is an antineoplastic medicine that has demonstrated preventive effects against fibrosis due to an antiangiogenic mechanism involving inhibition of vascular endothelial growth factor (VEGF).

Research objectives

The goal of this study was to assess VEGF inhibition for the postoperative treatment of fibrosis.

Research methods

Wistar albino rats ($n = 16$) were divided into two groups: control (laminectomy only) and sorafenib treatment (laminectomy + topical sorafenib). The animals were euthanized after six weeks, and EF tissue was examined for histopathological changes after immunohistochemical staining and an EF grade was assigned. SPSS 15.0 for Windows (IBM, Armonk, NY, United States) was used for statistical analysis. Statistical significance was accepted as $P < 0.05$.

Research results

By light microscopy, EF thickness, inflammatory cell density and arachnoid adhesions were higher in the control group compared to sorafenib-treated animals. Immunohistochemical staining for CD105 to identify microvessels revealed that EF grade was lower in the treatment group based on vessel count. Staining for osteopontin did not show any statistically significant

differences in the extent of EF between groups. Significant differences in fibrosis score, fibroblast density, inflammatory cell density and CD105 immunostaining were observed between the sorafenib and control groups ($P < 0.001$). All control animals (Group I) received fibrosis scores of grade 3, while scores for sorafenib-treated animals (Group II) did not exceed grade 1 ($P < 0.001$). Fibroblast density was graded the highest in 100% of Group 1 animals but remained at grade 1 in Group II. Scores for inflammatory cell density were lowest in Group II but highest in Group I, as were scores for microvessel density assessed by CD105 immunostaining ($P < 0.001$). There was no significant difference in microvessel density scores between groups after osteopontin staining ($P = 0.355$). By light microscope, it could be seen that EF thickness, inflammatory cell density and arachnoid adhesions were greater in control animals compared to Group II.

Research conclusions

In this study, we examined the efficacy of topical treatment with sorafenib for the prevention of EF in an animal laminectomy model and analyzed immunohistochemical methods for the assessment of microvessel density in fibrotic lesions compared to conventional measures of fibrosis staging. Our results demonstrated that topical sorafenib was effective in reducing EF after laminectomy, likely due to decreased neovascularization resulting from the antiangiogenic effect of sorafenib on VEGF activity. We further show that immunohistochemical assessment of microvessel density using anti-CD105 antibodies provided a new measure of fibrotic development that was compatible with conventional methods of fibrosis staging.

Research perspectives

In our study, the local application of sorafenib after laminectomy prevents EF. CD105 is a suitable marker for fibrosis, whereas osteopontin was not found to be reliable. Sorafenib was not observed to have any toxic effects or systemic side effects on normal tissues. Therefore, this application could be tested in clinical trials.

REFERENCES

- 1 **Gunaldi O**, Erdogan S, Guclu DG, Tugcu B, Ofluoglu E, Baydin S, Emel E. "Honey" can prevent epidural fibrosis development after laminectomy: an experimental study. *Turk Neurosurg* 2014; **24**: 849-854 [PMID: 25448199 DOI: 10.5137/1019-5149.JTN.8783-13.0]
- 2 **Ozkan U**, Osun A, Samancioglu A, Ercan S, Firat U, Kemaloglu S. The effect of bevacizumab and 5-Fluorouracil combination on epidural fibrosis in a rat laminectomy model. *Eur Rev Med Pharmacol Sci* 2014; **18**: 95-100 [PMID: 24452949]
- 3 **Altun I**. An Experimental Study of Histopathologic Effects of Hemostatic Agents Used in Spinal Surgery. *World Neurosurg* 2016; **90**: 147-153 [PMID: 26898493 DOI: 10.1016/j.wneu.2016.02.052]
- 4 **Larionov SN**, Sorokovikov VA, Erdyneyev KC, Lepekhova SA, Goldberg OA. Experimental Model of Intervertebral Disk Mediated Postoperative Epidural Fibrosis. *Ann Neurosci* 2016; **23**: 76-80 [PMID: 27647957 DOI: 10.1159/000443564]
- 5 **Henderson R**, Weir B, Davis L, Mielke B, Grace M. Attempted experimental modification of the postlaminectomy membrane by local instillation of recombinant tissue-plasminogen activator gel. *Spine (Phila Pa 1976)* 1993; **18**: 1268-1272 [PMID: 8211357 DOI: 10.1097/00007632-199308000-00004]
- 6 **Zhang C**, Kong X, Zhou H, Liu C, Zhao X, Zhou X, Su Y, Sharma HS, Feng S. An Experimental Novel Study: Angelica sinensis Prevents Epidural Fibrosis in Laminectomy Rats via Downregulation of Hydroxyproline, IL-6, and TGF- β 1. *Evid Based Complement Alternat Med* 2013; **2013**: 291814 [PMID: 24069047 DOI: 10.1155/2013/291814]
- 7 **Farrokhi MR**, Vasei M, Fareghbal S, Farrokhi N. The effect of methylene blue on peridural fibrosis formation after laminectomy in rats: an experimental novel study. *Spine J* 2011; **11**: 147-152 [PMID: 21296299 DOI: 10.1016/j.spinee.2011.01.014]
- 8 **Karatay M**, Erdem Y, Koktekir E, Erkoç YS, Caydere M, Bayar

- MA. The effect of bevacizumab on spinal epidural fibrosis in a postlaminectomy rat model. *Turk Neurosurg* 2012; **22**: 753-757 [PMID: 23208908 DOI: 10.5137/1019-5149.JTN.6155-12.1]
- 9 **Wang S**, Li X, Yan L, Nie Q, Dai J, Chen H, Wang J, Sun Y. Tamoxifen inhibits fibroblast proliferation and prevents epidural fibrosis by regulating the AKT pathway in rats. *Biochem Biophys Res Commun* 2018; **497**: 937-942 [PMID: 29309792 DOI: 10.1016/j.bbrc.2018.01.032]
 - 10 **Yilmaz A**, Karatay M, Yildirim T, Celik H, Sertbas I, Erdem Y, Caydere M, Isik HS, Bayar MA. Prevention of Epidural Fibrosis Using Ranibizumab in a Postlaminectomy Rat Model. *Turk Neurosurg* 2017; **27**: 119-123 [PMID: 27593757 DOI: 10.5137/1019-5149.JTN.14882-15.1]
 - 11 **Kaya M**, Yildirim CH, Kosemehmetoglu K, Huseyinoglu U, Erdogan H, Akbasak A, Tasdemiroglu E. Alpha-lipoic acid reduces peridural fibrosis after laminectomy of lumbar vertebrae in rabbits. *Acta Neurochir (Wien)* 2012; **154**: 1241-1245 [PMID: 22610532 DOI: 10.1007/s00701-012-1382-5]
 - 12 **Ma W**, Tao L, Wang X, Liu Q, Zhang W, Li Q, He C, Xue D, Zhang J, Liu C. Sorafenib Inhibits Renal Fibrosis Induced by Unilateral Ureteral Obstruction via Inhibition of Macrophage Infiltration. *Cell Physiol Biochem* 2016; **39**: 1837-1849 [PMID: 27744426 DOI: 10.1159/000447883]
 - 13 **Qu K**, Huang Z, Lin T, Liu S, Chang H, Yan Z, Zhang H, Liu C. New Insight into the Anti-liver Fibrosis Effect of Multitargeted Tyrosine Kinase Inhibitors: From Molecular Target to Clinical Trials. *Front Pharmacol* 2016; **6**: 300 [PMID: 26834633 DOI: 10.3389/fphar.2015.00300]
 - 14 **Geisler FH**. Prevention of peridural fibrosis: current methodologies. *Neurol Res* 1999; **21** Suppl 1: S9-S22 [PMID: 10214566 DOI: 10.1080/01616412.1999.11741021]
 - 15 **Hamby JM**, Showalter HD. Small molecule inhibitors of tumor-promoted angiogenesis, including protein tyrosine kinase inhibitors. *Pharmacol Ther* 1999; **82**: 169-193 [PMID: 10454196 DOI: 10.1016/S0163-7258(98)00053-9]
 - 16 **Fong TA**, Shawver LK, Sun L, Tang C, App H, Powell TJ, Kim YH, Schreck R, Wang X, Risau W, Ullrich A, Hirth KP, McMahon G. SU5416 is a potent and selective inhibitor of the vascular endothelial growth factor receptor (Flk-1/KDR) that inhibits tyrosine kinase catalysis, tumor vascularization, and growth of multiple tumor types. *Cancer Res* 1999; **59**: 99-106 [PMID: 9892193]
 - 17 **Beyer C**, Distler JH. Tyrosine kinase signaling in fibrotic disorders: Translation of basic research to human disease. *Biochim Biophys Acta* 2013; **1832**: 897-904 [PMID: 22728287 DOI: 10.1016/j.bbdis.2012.06.008]
 - 18 **Heldin CH**. Targeting the PDGF signaling pathway in the treatment of non-malignant diseases. *J Neuroimmune Pharmacol* 2014; **9**: 69-79 [PMID: 23793451 DOI: 10.1007/s11481-013-9484-2]
 - 19 **Prieto M**, Rodríguez-Peña A, Arévalo M, Rivas JV, Düwel A, Eleno N, Sánchez RJ, Morales AI, López-Novoa JM, Pérez-Barriocanal F. Effect of the long-term treatment with trandolapril on endoglin expression in rats with experimental renal fibrosis induced by renal mass reduction. *Kidney Blood Press Res* 2005; **28**: 32-40 [PMID: 15475654 DOI: 10.1159/000081439]
 - 20 **García-Pozo L**, Miquilena-Colina ME, Lozano-Rodríguez T, García-Monzón C. Endoglin: structure, biological functions, and role in fibrogenesis. *Rev Esp Enferm Dig* 2008; **100**: 355-360 [PMID: 18752365 DOI: 10.4321/S1130-01082008000600008]
 - 21 **Gougos A**, St Jacques S, Greaves A, O'Connell PJ, d'Apice AJ, Bühring HJ, Bernabeu C, van Mourik JA, Letarte M. Identification of distinct epitopes of endoglin, an RGD-containing glycoprotein of endothelial cells, leukemic cells, and syncytiotrophoblasts. *Int Immunol* 1992; **4**: 83-92 [PMID: 1371694 DOI: 10.1093/intimm/4.1.83]
 - 22 **Lastres P**, Bellon T, Cabañas C, Sanchez-Madrid F, Acevedo A, Gougos A, Letarte M, Bernabeu C. Regulated expression on human macrophages of endoglin, an Arg-Gly-Asp-containing surface antigen. *Eur J Immunol* 1992; **22**: 393-397 [PMID: 1537377 DOI: 10.1002/eji.1830220216]
 - 23 **St-Jacques S**, Cymerman U, Pece N, Letarte M. Molecular characterization and in situ localization of murine endoglin reveal that it is a transforming growth factor-beta binding protein of endothelial and stromal cells. *Endocrinology* 1994; **134**: 2645-2657 [PMID: 8194490 DOI: 10.1210/endo.134.6.8194490]
 - 24 **Letamendía A**, Lastres P, Botella LM, Raab U, Langa C, Velasco B, Attisano L, Bernabeu C. Role of endoglin in cellular responses to transforming growth factor-beta. A comparative study with betaglycan. *J Biol Chem* 1998; **273**: 33011-33019 [PMID: 9830054 DOI: 10.1074/jbc.273.49.33011]
 - 25 **García-Monzón C**, Sánchez-Madrid F, García-Buey L, García-Arroyo A, García-Sánchez A, Moreno-Otero R. Vascular adhesion molecule expression in viral chronic hepatitis: evidence of neo-angiogenesis in portal tracts. *Gastroenterology* 1995; **108**: 231-241 [PMID: 7528697 DOI: 10.1016/0016-5085(95)90029-2]
 - 26 **Mazzali M**, Kipari T, Ophascharoensuk V, Wesson JA, Johnson R, Hughes J. Osteopontin--a molecule for all seasons. *QJM* 2002; **95**: 3-13 [PMID: 11834767 DOI: 10.1093/qjmed/95.1.3]
 - 27 **Sodek J**, Ganss B, McKee MD. Osteopontin. *Crit Rev Oral Biol Med* 2000; **11**: 279-303 [PMID: 11021631 DOI: 10.1177/10454411000110030101]
 - 28 **Pereira P**, Avelino A, Monteiro P, Vaz R, Castro-Lopes JM. New insights from immunohistochemistry for the characterization of epidural scar tissue. *Pain Physician* 2014; **17**: 465-474 [PMID: 25247903]
 - 29 **He Y**, Revel M, Loty B. A quantitative model of post-laminectomy scar formation. Effects of a nonsteroidal anti-inflammatory drug. *Spine (Phila Pa 1976)* 1995; **20**: 557-563; discussion 579-580 [PMID: 7604325 DOI: 10.1097/00007632-199503010-00010]
 - 30 **Fayette J**, Soria JC, Armand JP. Use of angiogenesis inhibitors in tumour treatment. *Eur J Cancer* 2005; **41**: 1109-1116 [PMID: 15911233 DOI: 10.1016/j.ejca.2005.02.017]
 - 31 **Junaid A**, Amara FM. Osteopontin: correlation with interstitial fibrosis in human diabetic kidney and PI3-kinase-mediated enhancement of expression by glucose in human proximal tubular epithelial cells. *Histopathology* 2004; **44**: 136-146 [PMID: 14764057 DOI: 10.1111/j.1365-2559.2004.01771.x]
 - 32 **Kasimcan MO**, Bakar B, Aktaş S, Alhan A, Yilmaz M. Effectiveness of the biophysical barriers on the peridural fibrosis of a postlaminectomy rat model: an experimental research. *Injury* 2011; **42**: 778-781 [PMID: 21392759 DOI: 10.1016/j.injury.2010.12.017]
 - 33 **Breuing K**, Eriksson E, Liu P, Miller DR. Healing of partial thickness porcine skin wounds in a liquid environment. *J Surg Res* 1992; **52**: 50-58 [PMID: 1548868 DOI: 10.1016/0022-4804(92)90278-8]
 - 34 **Koukourakis MI**, Giatromanolaki A, Thorpe PE, Brekken RA, Sivridis E, Kakolyris S, Georgoulas V, Gatter KC, Harris AL. Vascular endothelial growth factor/KDR activated microvessel density versus CD31 standard microvessel density in non-small cell lung cancer. *Cancer Res* 2000; **60**: 3088-3095 [PMID: 10850461]
 - 35 **Weidner N**. The importance of tumor angiogenesis: the evidence continues to grow. *Am J Clin Pathol* 2004; **122**: 675-677 [PMID: 15491962 DOI: 10.1309/KY6E-H0LG-Y6D6-PGP5]
 - 36 **Yao Y**, Kubota T, Takeuchi H, Sato K. Prognostic significance of microvessel density determined by an anti-CD105/endoglin monoclonal antibody in astrocytic tumors: comparison with an anti-CD31 monoclonal antibody. *Neuropathology* 2005; **25**: 201-206 [PMID: 16193836 DOI: 10.1111/j.1440-1789.2005.00632.x]
 - 37 **Pardo A**, Gibson K, Cisneros J, Richards TJ, Yang Y, Becerril C, Yousem S, Herrera I, Ruiz V, Selman M, Kaminski N. Up-regulation and profibrotic role of osteopontin in human idiopathic pulmonary fibrosis. *PLoS Med* 2005; **2**: e251 [PMID: 16128620 DOI: 10.1371/journal.pmed.0020251]
 - 38 **Xiao X**, Gang Y, Gu Y, Zhao L, Chu J, Zhou J, Cai X, Zhang H, Xu L, Nie Y, Wu K, Liu Z, Fan D. Osteopontin contributes to TGF- β 1 mediated hepatic stellate cell activation. *Dig Dis Sci* 2012; **57**: 2883-2891 [PMID: 22661273 DOI: 10.1007/s10620-012-2248-7]

- 39 **Plastaras JP**, Kim SH, Liu YY, Dicker DT, Dorsey JF, McDonough J, Cerniglia G, Rajendran RR, Gupta A, Rustgi AK, Diehl JA, Smith CD, Flaherty KT, El-Deiry WS. Cell cycle dependent and schedule-dependent antitumor effects of sorafenib combined with radiation. *Cancer Res* 2007; **67**: 9443-9454 [PMID: 17909054 DOI: 10.1158/0008-5472.CAN-07-1473]
- 40 **Braverman DL**, Slipman CW, Lenrow DA. Using gabapentin to treat failed back surgery syndrome caused by epidural fibrosis: A report of 2 cases. *Arch Phys Med Rehabil* 2001; **82**: 691-693 [PMID: 11346850 DOI: 10.1053/apmr.2001.21867]

P- Reviewer: Chui YL, Tajiri K, Wang Y **S- Editor:** Cui LJ
L- Editor: Filipodia **E- Editor:** Tan WW





Published by **Baishideng Publishing Group Inc**
7901 Stoneridge Drive, Suite 501, Pleasanton, CA 94588, USA
Telephone: +1-925-223-8242
Fax: +1-925-223-8243
E-mail: bpgoffice@wjgnet.com
Help Desk: <http://www.f6publishing.com/helpdesk>
<http://www.wjgnet.com>

