

See discussions, stats, and author profiles for this publication at: <https://www.researchgate.net/publication/327645303>

Gastrointestinal evaluation in colchicine-treated familial Mediterranean fever patients with chronic abdominal pain: Cases series

Article in *Archivos Argentinos de Pediatría* · September 2018

DOI: 10.5546/aap.2018.eng.e649

CITATIONS

0

READS

158

3 authors, including:



Selçuk Yazıcı

Balikesir University

26 PUBLICATIONS 22 CITATIONS

SEE PROFILE

Gastrointestinal evaluation in colchicine-treated familial Mediterranean fever patients with chronic abdominal pain: Cases series

Sezin Akman M.D.^a, Selcuk Yazici M.D.^b and Can Ozturk M.D.^c

ABSTRACT

The aim of the study to evaluate familial mediterranean fever (FMF) patients with chronic abdominal pain unresponsive to colchicine treatment.

Forty-eight patients who diagnosed in our Pediatric Rheumatology clinics and suffering from abdominal pain despite colchicine treatment were include. All patients were referred to a pediatric gastroenterologist. The pain characteristics such as onset, duration and frequency were recorded; gastrointestinal (GI) endoscopy was planned for differential diagnosis.

MEFV mutation was determined in 46 patients. The median duration of treatment was 2.8 years. Approximately 60% of the patients suffered from abdominal pain every day or 2-3 times a week, in 73% of the cases it lasted less than three hours. Forty-one patients underwent upper GI endoscopy.

Gastroduodenitis is a common finding in persisting abdominal pain despite therapy of FMF patients. The patients with the highest disease severity scores had severe inflammation within the entire GI system.

Key words: abdominal pain - gastroenterology, diagnostic - familial mediterranean fever.

<http://dx.doi.org/10.5546/aap.2018.eng.e649>

To cite: Akman S, Yazici S, Ozturk C. Gastrointestinal evaluation in colchicine-treated familial Mediterranean fever patients with chronic abdominal pain: Cases series. *Arch Argent Pediatr* 2018;116(5):e649-e654.

- Department of Pediatrics, Pediatric Gastroenterology Unit.
- Department of Pediatrics. Balikesir University Medical Faculty, Turkey.
- Ministry of Health Izmir Tepecik Training and Research. Hospital, Pediatric Immunology and Rheumatology Unit, Turkey.

E-mail address:

Sezin Akman, M.D., Assoc. Prof.: aa.sezin@gmail.com

Funding: None.

Conflict of interest: None.

Received: 10-1-2017

Accepted: 3-4-2018

INTRODUCTION

Familial mediterranean fever (FMF) is the most common auto-inflammatory disease among people of Mediterranean descent. The gene causing FMF (MEFV) is located on the chromosome 16; homozygous state for M694V mutation is associated with a more severe form of the disease. Typical symptoms are fever, accompanied by abdominal, chest or joint pains and scrotal involvement. Most symptoms resolve spontaneously within 12-24 hours. The most devastating complication is amyloidosis and finally leading to end stage renal disease.¹⁻³ Periton is the most commonly affected serosal involvement. Thus abdominal pain is the most common complaint in patients. Most of the time, FMF patients have been referred to a gastroenterologist before the diagnosis. Abdominal pain may be secondary to FMF-associated diseases such as inflammatory bowel disease or amyloidosis.^{1,4,5} Colchicine is highly effective in the treatment by preventing the development of attacks and amyloidosis. The symptoms usually disappear following treatment due to the control of inflammation. However, in some cases, symptoms may not respond to treatment although adequate control of inflammatory markers are attained. Therapeutic difficulties may occur in patients who have overlapping or associated GI diseases.^{1,3,4,6}

Our aim was to evaluate patients with chronic abdominal pain unresponsive to colchicine treatment.

METHODS

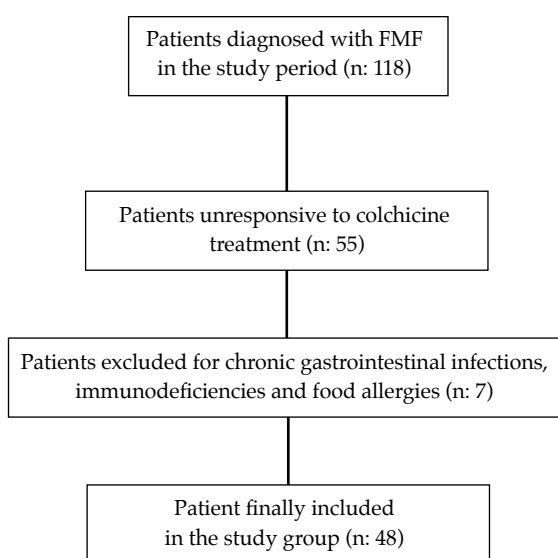
This study was conducted on 48 patients with FMF during the period January 2011 to June 2012. The diagnosis was determined according to Livneh criteria.² All patients were followed in Pediatric Rheumatology, and have been treated with colchicine for at least six months. Colchicine 0.5-1 mg/day was the initial dose. The dosage was gradually increased up to 2 mg/day for unresponsive patients. The study group involved patients with chronic abdominal pain who were consulted by Pediatric Gastroenterology. The

disease severity score (DSS) was calculated for all patients according to the Pras's study⁷ and Rome III criteria⁸ for the evaluation of abdominal pain.

The study has been approved by the Ethics Committee (Jan 14th, 2011), informed consent was obtained from all parents. Children with an accompanying illness suggestive of acute abdomen were excluded from the study. Infections, immunodeficiencies, food allergies were excluded by stool culture, immunologic analysis, skin prick test and elimination diets (Figure 1). Demographic characteristics of the patients, MEFV mutations, the onset, frequency and duration of pain, laboratory findings for *Helicobacter pylori* (*H. pylori*) infection and celiac disease were evaluated.

DNA was extracted from peripheral blood using standard protocols (Invisorb® Spin Blood Kit, STRATEC, Germany). Molecular analyses were performed within the framework of routine genetic testing. MEFV mutation was investigated by the PCR reverse hybridization method. *H. pylori* infection was diagnosed by methods such as endoscopy, urea breath test, and detection of antigen in stool. Endoscopic evaluation was planned to the FMF patients who did not respond to colchicine. Forty-one patients' families accepted endoscopic procedure. Upper and/or lower GI endoscopies were performed under sedation when indicated after informed consents were obtained. At least two biopsies were taken from duodenum to oesophagus and histological findings were evaluated.

FIGURE 1. Patient inclusion and exclusion criteria



As *H. pylori* eradication therapy, triple regimen with a proton pump inhibitor (PPI) plus amoxicillin and clarithromycin or metronidazole were administered for 7-14 days.⁹ PPI was given to patients with gastritis/oesophagitis; metronidazole was also added besides antacids for the treatment of duodenitis. Patients were called periodically for the evaluation of response to treatment, for 6 months.

SPSS (Chicago, USA, version 15.0) program was used for the identification of obtained demographic and clinical data. The numerical values in the study are shown as mean±standard deviation, percent (%) and number (n). Median and range values were used when data are not normally distributed.

RESULTS

The flowchart of patients is shown in the Figure 1. The mean age was 11.7 ± 3.2 years, 20/48 (41.7%) were male. The median duration of colchicine treatment was 2.8 years and the average onset of pain after the start of colchicine was 3.3 ± 1.8 months. The pain persisted in 75% of patients for at least three months, in 90%, the frequency was daily and/or at least 3 times per week, in approximately 75% it took less than three hours, and in 80% main localization was whole abdomen and/or epigastrium. The most common complaint accompanying pain was nausea (56.2%). The urea breath test and celiac serology were positive in nine (18.7%) and one (2.1%) patients, respectively (Table 1).

Twenty-one percent of patients had a history of FMF in the family, in 46 patients (95.8%) MEFV mutations were detected. Average DSS value was detected as 6.8 ± 2.1 . It was remarkable that all of the patients with the highest DSS had inflammation within the whole GI system (Table 2). Upper GI endoscopy was applied to forty-one patients (85.4%) and three patients underwent colonoscopy. Gastroduodenitis was the most prominent histologic finding (Figures 2 and 3). All findings were normal in patients who underwent colonoscopic intervention. Sixty-seven percent of patients responded to treatment.

DISCUSSION

In the present study, FMF patients receiving effective dosages of colchicine with persistent abdominal pain in the absence of other FMF-related findings during follow up were assessed. These patients were referred to the Pediatric Gastroenterology for evaluation of abdominal

pain. Approximately 4/5 of patients required endoscopic intervention. GI pathologies were found to be more common in children with a high DSS.

Characteristics of abdominal pain defined by our patients that were not accompanied by joint pain or fever, sometimes occurring every day, did not comply with the abdominal pain of FMF. It was differed from "typical" FMF attacks, which may include the findings of "true" peritonitis and/or increased acute phase parameters. In the majority of patients, the duration of pain was shorter than expecting in FMF. In previous studies, it is reported that it is difficult to distinguish abdominal pains in the epigastrium or the whole abdomen from typical attacks. Because episodic abdominal pain affects 95% of FMF patients, most of them are seen by gastroenterologists.^{1,4,10}

The number of studies that focus on the investigation of GI infection-inflammation in the differential diagnosis of abdominal pain, despite treatment in patients with FMF, is small. In addition to publications associated with inflammatory bowel diseases and MEFV mutation positivity, some patients that have presented

with inflammatory colitis clinic were reported to get FMF diagnosis ultimately.^{6,11} There is little knowledge on the evaluation of GI mucosa in children with FMF in the literature. Mucosal involvement of the GI tract without amyloidosis was established as an attack-related manifestation of the disease in the study conducted by Gurkan et al.¹² Their study showed that colonic and gastric inflammations were observed in the endoscopic evaluation. Gastrointestinal involvement has been explained by bacterial overgrowth related to dysmotility and malabsorption caused by amyloid deposition. However, mucosal inflammation was not related to amyloidosis in that study.

Colchicine improves disease symptoms, but in case of GI symptoms related FMF, unresponsiveness to colchicine should be a consideration.¹³ Typical gastric histological features of colchicine such as epithelial pseudoproliferation, mucin depletion, and apoptosis may be determined in FMF patients.¹⁴ In our study, all patients who underwent upper GI endoscopy, except for three who had normal findings; oesophagitis, gastritis, bulbitis, duodenitis were determined and, histological evaluation of biopsies did not display secondary

TABLE 1. Characteristics of patients and abdominal pain

Gender (M/F, n [%])	20 (41.7) / 28 (58.3)		
Age (mean \pm SD) (years)	11.7 \pm 3.2		
The onset of pain (months)	3.3 \pm 1.8		
Duration colchicine therapy (years)*	2.8 (1-4.9)		
Positive urea breath test (n [%])	9 (18.7)		
Positive celiac serology (n [%])	1 (2.1)		
Characteristics of the pain			
Frequency	n (%)	Localization	n (%)
Every day	13 (27)	Epigastric	18 (37.5)
Two or three per week	17 (35.4)	Whole abdomen	19 (39.6)
Once a week	13 (27)	Umbilical	9 (18.7)
Once or twice a month	5 (10.4)	Retrosternal	2 (4.2)
Duration		Accompanying signs	
Less than one hour	24 (50.0)	Nausea	27 (56.2)
One to three hours	11 (22.9)	Vomiting	3 (6.2)
Three to twelve hours	5 (10.4)	Nausea + vomiting	6 (12.5)
More than twelve hours	8 (16.6)	Diarrhea	5 (10.4)
		No	7 (14.5)

*median, range values

TABLE 2. MEFV mutations in relation to endoscopic findings and the disease severity scores

Patient	MEFV mutation exon 2	MEFV mutation exon 3	MEFV mutation exon 10	Endoscopic findings				DSS**
				O*	G*	B*	D*	
1	E148Q /-				+	+		5
2	E148Q /-				+		+	8
3	E148Q /-				+			6
4	E148Q /-			+	+			5
5	E148Q /-				+	+	+	6
6	E148Q /-		Missing endoscopy		7			
7	E148Q /-				+			6
8	E148Q /-			+	+			7
9	E148Q /-				+	+	+	8
10	E148Q /-				+			6
11			V726A /-	+	+			6
12			V726A /-		+			6
13			V726A /-	+		+		6
14			V726A /-	Missing endoscopy	5			
15	R202Q /-		V726A /-		+			7
16	R202Q /-				+			9
17	R202Q /-			+	+	+	+	8
18	R202Q /-			+	+			6
19	R202Q /-				+		+	7
20			M694V /-		+		+	8
21			M694V /-		+			5
22			M694V /-	Normal endoscopic findings	6			
23		P369S /-		Missing endoscopy	5			
24			K695R /-	Normal endoscopic findings	6			
25			R761H /-	Missing endoscopy	5			
26			R761H /-		+			6
27		R314R /-			+	+		7
28		R314R /-		+				6
29			P706P /-	+				5
30			P124P /-	+	+			7
31	R202Q /R202Q			Missing endoscopy	6			
32	R202Q /R202Q			Normal endoscopic findings	6			
33	R202Q /R202Q				+			5
34	R202Q /R202Q					+	+	6
35	R202Q /-		M694V /-	+	+	+	+	8
36	R202Q /-		M694V /-	+				5
37			M694V /M694V	+	+	+	+	12
38			M694V /M694V	+		+	+	8
39	R202Q /-		M680I /-		+			10
40	E148Q /-		M680I /-		+			5
41	R202Q /E148Q			Missing endoscopy	7			
42	L110P /E148Q						+	7
43	E148Q/E148Q		M694V /-	Missing endoscopy	6			
44	E148Q/E148Q		M694V /-	+	+	+	+	11
45	E148Q/E148Q		M694V /-	+	+	+	+	12
46	R202Q/R202Q		M694V /-	+	+	+	+	12
47	Mutation negative, FMF				+		+	8
48	Mutation negative, FMF			+	+			6

*O: Oesophagitis, G: Gastritis, B: Bulbitis, D: Duodenitis

**DSS: Disease severity score

changes to colchicine. In six patients with high DSS according to Pras,⁷ from severe to moderate inflammation continuing from oesophagus to duodenum was observed. On the other hand, the patients with homozygote mutations had showed higher levels of DSS. However, due to lack of a control group and the low number of the patients, this difference was not statistically significant and could not be interpreted. In the literature, there is an adult study which has evaluated GI symptoms in FMF by capsule endoscopy. Similar to our study, small bowel mucosal defects as erosions and edema had been determined.¹⁵

In the present study, *H. pylori* infection was histologically proven in all patients who had positive urea breath test. Clinical and histological findings in a patient with positive serology have not been verified in favor of celiac disease. A positive response to treatment was received in 67% of patients for GI inflammation. Relatively small number of patients and the lack of recorded the colchicine-side effects are major limitations of our study.

As a result, in patients receiving an effective dose of colchicine with normal laboratory markers of inflammation and who have abdominal pain with different clinical characteristics than typical FMF attacks, gastroenterologic evaluation should be performed. Endoscopic interventions have played an informative role in our patient group. The probable positive correlation of histologically

severe GI inflammation with higher DSS should be verified in more extensive series. ■

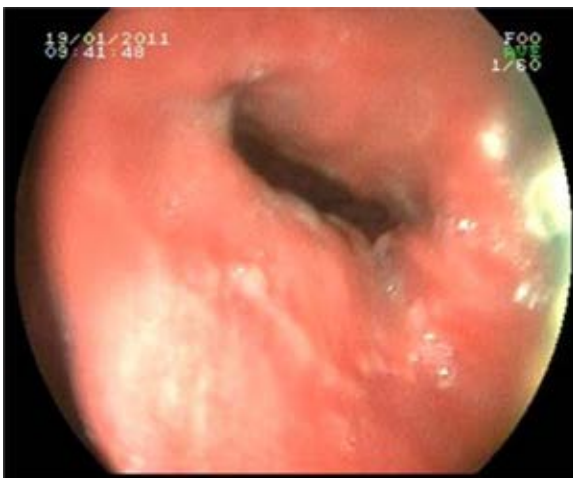Acknowledgments

We thank Guzide Aksu for support and encouragement

REFERENCES

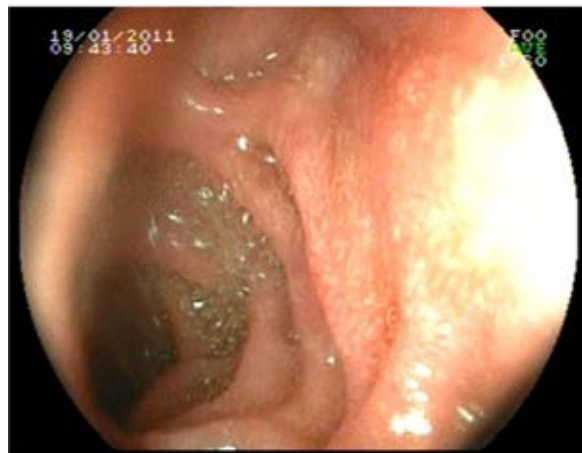1. Brydges S, Althreya B, Kastner DL. Periodic fever syndromes in children. In: Cassidy JT, Petty RE, Laxer RM, et al eds. Textbook of pediatric rheumatology. 5th ed. Philadelphia: Elsevier-Saunders; 2005. Págs.657-67.
2. Livneh A, Langevitz P, Zemer D, et al. Criteria for the diagnosis of familial Mediterranean fever. *Arthritis Rheum* 1997; 40(10):1879-85.
3. Ben-Chetrit E. Familial Mediterranean fever (FMF) and renal AA amyloidosis-phenotype-genotype correlation, treatment and prognosis. *J Nephrol* 2003; 16(3):431-4.
4. Mor A, Gal R, Livneh A. Abdominal and digestive system associations of familial Mediterranean fever. *Am J Gastroenterol* 2003; 98(12):2594-604.
5. Mor A, Shinar Y, Zaks N, et al. Evaluation of disease severity in familial Mediterranean fever. *Semin Arthritis Rheum* 2005; 35(1):57-64.
6. Sari S, Egritas O, Dalgic B. The familial Mediterranean fever (MEFV) gene may be a modifier factor of inflammatory bowel disease in infancy. *Eur J Pediatr* 2008; 167(4):391-3.
7. Pras E, Livneh A, Balow JE Jr, et al. Clinical differences between North African and Iraqi Jews with familial Mediterranean fever. *Am J Med Genet* 1998; 75(2):216-9.
8. Baber KF, Anderson J, Puzanovova M, et al. Rome II versus Rome III classification of functional gastrointestinal disorders in pediatric chronic abdominal pain. *J Pediatr Gastroenterol Nutr* 2008; 47(3):299-302.
9. Abuhammour A, Dajani A, Nounou M, et al. Standard triple therapy versus sequential therapy for eradication of

FIGURE 2. Endoscopic findings of oesophagitis (Patient No: 35)



Erosions involving the region from the distal oesophagus to the z-line with a streaky pattern.

FIGURE 3. Macroscopic alterations ranging from erythema to mucosal erosions in duodenum



- Helicobacter pylori in treatment naïve and retreat patients. *Arab J Gastroenterol* 2016; 17(3):131-6.
10. Ozturk C, Halicioglu O, Coker I, et al. Association of clinical and genetical features in FMF with focus on MEFV strip assay sensitivity in 452 children from western Anatolia, Turkey. *Clin Rheumatol* 2012; 31(3):493-501.
 11. Kiss MH, Magalhães CS. Autoinflammatory diseases: mimics of autoimmunity or part of its spectrum? Case presentation. *J Clin Immunol* 2008; 28 (Suppl 1):S84-9.
 12. Gurkan OE, Dalgic B. Gastrointestinal mucosal involvement without amyloidosis in children with familial Mediterranean fever. *J Pediatr Gastroenterol Nutr* 2013; 57(3):319-23.
 13. Kallinich T, Haffner D, Niehues T, et al. Colchicine use in children and adolescents with familial Mediterranean fever: literature review and consensus statement. *Pediatrics* 2007; 119(2):e474-83.
 14. Al-Daraji WI, Al-Mahmoud RM, Ilyas M. Gastric changes following colchicine therapy in patients with FMF. *Dig Dis Sci* 2008; 53(8):2079-82.
 15. Demir A, Akyüz F, Göktürk S, et al. Small bowel mucosal damage in familial Mediterranean fever: results of capsule endoscopy screening. *Scand J Gastroenterol* 2014; 49(12):1414-8.