

Effects of Caffeic Acid Phenethyl Ester, Ellagic Acid, Sulforaphane and Curcumin on Diazinon Induced Damage to the Lungs, Liver and Kidneys in An Acute Toxicity Rat Model

Harun ALP *✍️ İsmail AYTEKİN ** Hasan ESEN *** Kemal BASARALI **** Seval KUL *****

* Dicle University, Department of Pharmacology and Toxicology, Veterinary Faculty, TR-21103 Diyarbakir - TURKEY

** Balıkesir University, Department of Internal Medicine, Veterinary Faculty, TR-10100 Balıkesir - TURKEY

*** Selçuk University, Department of Pathology, Meram Medical Faculty, TR-42075 Konya - TURKEY

**** Dicle University, Department of Biochemistry, Meram Medical Faculty, TR-21103 Diyarbakir - TURKEY

***** Gaziantep University, Department of Statistics, TR-27970 Gaziantep - TURKEY

Makale Kodu (Article Code): KVFD-2011-4722

Summary

The aim of this study was to investigate the possible protective effects of caffeic acid phenethyl ester (CAPE), ellagic acid (EA), sulforaphane (SFN) and curcumin (CUR) against the toxic effects of diazinon (DI). Sixty Sprague Dawley rats were randomly divided into 10 groups. Five groups were allocated as control groups comprising unmedicated control, CAPE, EA, SFN and CUR control groups. The remaining five groups were the study groups comprising DI, DI + CAPE, DI + EA, DI + SFN, and DI + CUR groups. The animals were sacrificed 24 h after drug administrations. DI caused a decrease in acetyl cholinesterase (AChE) activity ($P<0.05$) and increases in γ -glutamyltransferase (GGT) and amylase activities. It also damaged the kidney, liver, and lung tissues. The negative effects of DI on these enzymes were confirmed histopathologically. Also, CAPE, EA, SFN and CUR reduced amylase and GGT activities and caused an increase in the AChE activities that were increased due to the toxic effects of DI. Thus, it was determined biochemically and histopathologically that these medication reduced the degenerative toxic effects created by DI in the lung, liver and kidney tissues. These findings led us to believe that CAPE, EA, SFN and CUR may be used as protective medicines in acute DI intoxication.

Keywords: Diazinon, Ellagic acid, Caffeic acid phenethyl ester, Sulforaphan, Curcumin

Akut Toksikite Sıçan Modelinde Diazinonun Neden Olduğu Akciğer, Karaciğer ve Böbrek Hasarı Üzerine Kafeik Asit Fenetil Ester, Elajik Asit, Sulforafan ve Kurkumin'in Etkileri

Özet

Bu çalışmanın amacı kafeik asit fenetil ester (CAPE), elajik asit (EA), Sulforafan (SFN) ve Kurkumin (CUR)'ün, diazinon (DI)'un toksik etkilerine karşı muhtemel koruyucu etkilerini araştırmaktır. Çalışmada 60 adet Sprague Dawley sıçan eşit şekilde ve rastgele 10 gruba ayrıldı. Kontrol grupları; kontrol, CAPE, EA, SFN ve CUR grupları olarak 5 gruba ayrıldı. Geri kalan 5 grup ise çalışma grupları olarak; DI, DI + CAPE, DI + EA, DI + SFN ve DI + CUR gruplarına ayrıldı. Hayvanlar ilaç uygulamalarından 24 saat sonra sakrifiye edildi. DI, asetil kolin esteraz (AChE) aktivitelerine azaltıcı ($P<0.05$) ve γ -glutamiltransferaz (GGT) ile amilaz aktivitelerine artırıcı şekilde etkiye neden oldu. Bu enzimler üzerine DI'un negatif etkileri, dokular üzerine histopatolojik olarak da doğrulandı. Ayrıca CAPE, EA, SFN ve CUR, DI'un toksik etkilerine karşı γ -glutamiltransferaz (GGT) ile amilaz aktivitelerine azaltıcı ve asetil kolin esteraz (AChE) aktivitelerine ise artırıcı şekilde etkiye neden oldu. Bu şekilde, biyokimyasal ve histopatolojik olarak ilaçların, DI'un neden olduğu dejeneratif ve toksik etkileri azalttığı belirlendi. Bu bulgular, akut DI toksikasyonunda CAPE, EA, SFN ve CUR'in koruyucu amaçla kullanılabileceği fikrini bize verdi.

Anahtar sözcükler: Diazinon, Elajik asit, Kafeik asit fenetil ester, Sulforafan, Kurkumin



İletişim (Correspondence)



+90 412 2488021



alpharun@gmail.com

INTRODUCTION

Pesticides are used mostly in agriculture and worldwide each year approximately 2.5 million tons of pesticides are used. World Health Organization reports have stated an annual rate of approximately 3 million cases of human poisoning by pesticide and of those 220,000 are fatal^{1,2}.

Diazinon (O,O-diethyl-O-(2-isopropyl-4-methyl-6-pyrimidinylphosphorothionate) is a commonly used organophosphate (OP) pesticide to control a variety of insects in agriculture and household environment. Despite its low persistence in the environment, it is a nonspecific insecticide and highly toxic to animals and humans. Moreover, the toxicity of OPs is increased by its break-down products, which may be bioactivated within an organism or through exposure to the sunlight^{3,4}. Therefore, diazinon (DI) was selected as the toxic material for this study.

Recent studies have revealed that CAPE⁵⁻⁹, SFN¹⁰⁻¹³, CUR¹⁴⁻¹⁶, and EA¹⁷⁻¹⁹ have anti-inflammatory, antioxidant, immunomodulator, antimycotic and anticarcinogenic characteristics. However, few studies about the eventual protective effects of antioxidant agents against the acute toxic effects induced by DI in lungs, liver and kidneys are available. For this purpose, the aims of the present study were to investigate the eventual protective effects of CAPE, EA, SFN and CUR on DI-induced tissue damage, and also to compare these effects by the histopathological analysis and the determination of serum AChE, amylase and γ -glutamyltransferase (GGT) activities in rats intoxicated by DI.

MATERIAL and METHODS

The present study was conducted on 60 mature, female, weighing approximately 200-250 g, Sprague Dawley rats. The animals were kept under laboratory conditions of 12 h light and dark at a room temperature (21°C±2°C). The study was approved by Experimental Animals Ethics Committee of Selcuk University (No: 2009/48).

The rats were randomly divided into 10 equal groups: whereas the 5 first groups [group C: not treated rats; in the 4 other groups, rats were treated with CAPE (10 μ mol/kg, intraperitoneally) (group CAPE), EA (85 mg/kg, *per os*) (group EA), SFN (0.5 mg/kg, *per os*) (group SFN) and CUR (*Curcuma longa*, 1 g/kg, *per os*) (group CUR), respectively] served as controls. Diazinon (DI) (200 mg/kg) was administered *per os* to the rodents in the 5 other groups simultaneously treated or not with the antioxidants (groups DI/CAPE, DI/EA, DI/SFN, DI/CUR and DI, respectively). All the antioxidants used were purchased from Sigma while DI was provided by Basudin; Syngenta laboratories. Twenty four hours after the drug administration, after anesthesia with ketamine (85 mg/kg, intraperitoneally, Ketalar, Pfizer), blood samples were collected by intracardiac puncture,

without anticoagulant. After clotting at room temperature for 1 h and centrifugation (1.500 g, 10 min, 4°C), sera were carefully harvested and stored at -20°C until analysis. After blood sampling, animals were sacrificed by decapitation.

Biochemical Parameters

The enzyme amylase, GGT and AChE activities in serum were determined with Roche Cobas Integra 800 autoanalyser by enzymatic colorimetric method using Roche brand commercial kits in 409/659 nm. The enzyme activities were expressed as U/L. Measurement range of the tests are 3-2.000 U/L (0.05-33.00 μ kat/L) for amylase, 200-14.000 U/L (3.34-234.00 μ kat/L) for AChE and 3-1.200 U/L (0.05-20.00 μ kat/L) for GGT.

Statistical Evaluation

The normality of the distribution of the enzyme activities was first investigated using the Kolmogorov-Smirnov test. Independent sample t test was used for parameters with a normal distribution, and Mann Whitney U tests were performed when the distribution was not normal to demonstrate the significance of the experimental treatments. A value of P<0.05 was accepted as statistically significant.

Histopathological Analysis

Immediately after death, the lung, liver and kidney tissues in a 10% formaldehyde solution were processed in cassette autotechnic tissue processing equipment (Leica ASP 300). When the processing was completed, the tissues were embedded in paraffin blocks and sections (5 mm in thickness) taken by microtome instrument onto lysine laminin. The preparations stained with haematoxylin and eosin staining, were evaluated by Olympus BX51 microscope.

The histopathological evaluation of tissue damage included the intensity of cellular hydropic degeneration, of neutrophil and mononuclear cell infiltration, degenerative lipoidosis, necrosis and fibrosis. For each considered organs, the following grades were created²⁰. Briefly, the liver damage was classified into 3 grades according to the cell degeneration and to the intensity of inflammatory infiltrates, necrosis and bleeding areas and fibrosis of the parenchyma. For the kidneys, the occurrence of tubular epithelium damage and accumulation of proteinous mass in the tubular lumen due to the filtration failure were examined and graded. In lungs, oedema, alveolar congestion, perivascular and peribronchial infiltration, parenchymal fibrosis and alveolar wall thickening were observed. Each parameter was scored between 0 and 3 (0: normal, 1: mild, 2: moderate and 3: severe) and according to the point total, lesions were classified into 3 grades (grade 1: 1-5 points, grade 2: 6-10 points and grade 3: 11-15 points). It was determined histopathologically that the tissues of liver, kidney and lung intoxicated by DI were significantly damaged (grade 3). However, it was

observed that these medication reduced the degenerative toxic effects created by DI in the lung, liver and kidney tissues (mostly grade 1, and rarely grade 2). As a result, histopathologic results indicated that these medication have not completely eliminated the toxic effects of DI, but partially prevented and reduced the degenerative toxic effects created by DI.

RESULTS

From a biochemical aspect, when the unmedicated control group was compared with the CAPE control, EA control, SFN control and CUR control, there was no statistically significant difference between the groups in terms of serum AChE, amylase and GGT activities (Table 1).

In a comparison of the unmedicated, CAPE, EA, SFN and CUR control groups with the DI control group, a significant decrease in AChE levels ($P<0.05$) and a statistically significant increase in amylase and GGT levels ($P<0.05$) was determined in the DI control group. That the negative toxic effects of DI on serum enzymes originated from the degenerative effect on the tissues was confirmed histopathologically. In a comparison of the DI control group with DI + CAPE, DI + EA, DI + SFN and DI + CUR groups, it was observed that while CAPE, EA, SFN and CUR were observed to cause a decrease in amylase and GGT activities, there was an increase in AChE activities. That the positive effects of the medications on the enzymes originated from the decrease of the toxic degenerative effects in the tissues created by DI was confirmed histopathologically (Table 2, Fig. 1, Fig. 2, Fig. 3).

DISCUSSION

Organophosphate poisoning leads to quite a serious clinical table with such as the sudden onset of respiratory failure which necessitates intensive care unit follow-up^{21,22}. Negative effects on several systems are seen in organophosphate poisoning, such as hepatotoxicity, neurotoxicity, genetic toxicity, embryotoxicity, immunotoxicity, pancreatitis and orchitis²³⁻²⁷.

DI is an AChE inhibitor and classified as an organophosphate insecticide (OPI) often causing human and animal poisoning²⁶. However, the effects of DI are not just limited to the nervous system but may also be the reason for defects in other tissues and systems under the control of the central nervous system.

Previous studies have reported the use of AChE activity as a marker in the definition of OPI poisoning. However, the rate of reduction of AChE activity is important. It has been accepted that at a rate of 20% AChE activity inhibition, the effect of organophosphate pesticides remains visible²⁸. If inhibition occurs at levels of 50% or higher, there is a life-threatening situation²⁹. In the present study, when the control group was compared with the DI control group, DI created AChE inhibition at the rate of 64.38%. At this rate, the animals to which DI had been administered were struggling to survive. To investigate the efficiency of the medications on this severe AChE inhibition created by DI, a comparison was made between the unmedicated control, CAPE control, SFN control, EA control, CUR control groups and the DI control, DI + CAPE, DI + SFN, DI + EA, and DI + CUR groups and it was determined that SFN, EA, CAPE and

Table 1. The effects of the medications on AChE, amylase and GGT enzymes in comparison with the control group

Tablo 1. Kontrol grubuna göre ilaçların, AChE, amilaz ve GGT enzimleri üzerine etkileri

Enzyme	Control (n=6)	CAPE Control (n=6)	EA Control (n=6)	SFN Control (n=6)	CUR Kontrol (n=6)
AChE	1.21±0.14	1.35±0.34	1.35±0.39	1.18±0.26	1.34±0.31
Amylase	523.83±116.89	504.83±49.10	524.83±57.91	456.20±102.97	468.60±97.31
GGT (U/L)	6.16±0.75	9.00±3.52	7.66±2.16	7.00±3.67	7.4±3.13

* No statistically significant difference was determined on comparison of the medication groups with the control group (Kontrol grubu ile ilaç grupları karşılaştırıldığında, istatistiksel olarak aralarında anlamlı fark yoktur)

Table 2. The effects of the medications on AChE, amylase and GGT enzymes compared to Diazinon (DI) control

Tablo 2. Diazinon kontrole göre ilaçların, AChE, amilaz ve GGT enzimleri üzerine etkileri

Enzyme	Control (n=6)	DI Control (n=6)	DI+CAPE (n=6)	DI+CUR (n=6)	DI+EA (n=6)	DI+SFN (n=6)
AChE	1.21±0.14*	0.43±0.05	0.75±0.07*	0.69±0.05	0.67±0.05	0.63±0.50
Amylase	523.83±116.89*	769.24±48.29*	576.4±112.18*	579.00±179.46*	512.16±153.80*	599.2±34.098*
GGT (U/L)	6.16±0.75	15.33±1.32	9.2±2.59*	10±6.20*	9.83±1.47	10.8±3.49*

* vs DI control $P<0.05$

* a statistically significant difference was observed ($P<0.05$) (İstatistiksel olarak önemli bir fark saptanmıştır [$P<0.05$])

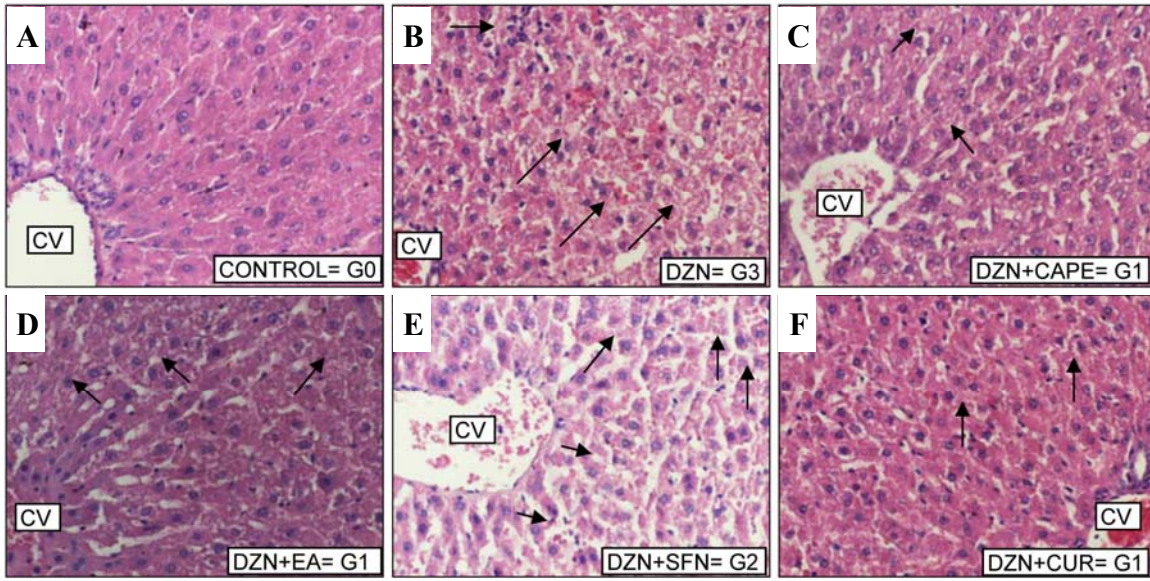


Fig 1. Liver histology in an unmedicated control rats (A), in only diazinon (DI)-intoxicated rats not treated with antioxidants (B) or simultaneously treated with caffeic acid phenethyl ester (DI + CAPE) (C), ellagic acid (DI + EA) (D), sulforaphan (DI + SFN) (E) or curcumin (DI + CUR) (F). The damage grade (G) is seen on the right of the image. Note the vacuolisation of hepatocytes in rats from the groups DI + CAPE, DI + EA and DI + CUR (G 1), the hyper-eosinophilic cytoplasm of hepatocytes in rats from the groups DI + SFN and DI (G 2 and 3) and the severe necrosis and inflammatory infiltration in the rat from the group DI (G 3). Haematoxylin and eosin staining, original magnification X 200. (CV: Central vein). The arrows indicate the damaged areas.

Şekil 1. Grupların karaciğer histolojisi. İlaçsız kontrol grubu sıçanların (A), antioksidanlar uygulanmamış ve yalnızca diazinon (DI) ile toksikasyona uğramış sıçanların (B), DI ile birlikte sırasıyla; kafeik asit fenetil ester (CAPE) uygulanmış sıçanların (DI + CAPE) (C), elajik asit (DI + EA) (D), sulforaphan (DI + SFN) (E) ve curcumin (DI + CUR) (F) olarak belirtilmiştir. Resimlerin sağ tarafında histopatolojik hasar derecesi (G) gösterilmiştir. DI + CAPE, DI + EA and DI + CUR gruplarındaki sıçanların hepatositlerinde vakualizasyon (G 1), DI + SFN ve DI gruplarında ki sıçanların hepatosit stoplazmalarının hiper eosinofilik görünümü (G 2 ve 3). DI gruplarında ki sıçanların hepatositlerinde ciddi nekroz, inflamasyon ve infiltrasyon (G 3) şeklinde belirtilmiştir. Hematoksilen ve eozin, orijinal büyüme X 200. Oklar hasarlı alanları göstermektedir

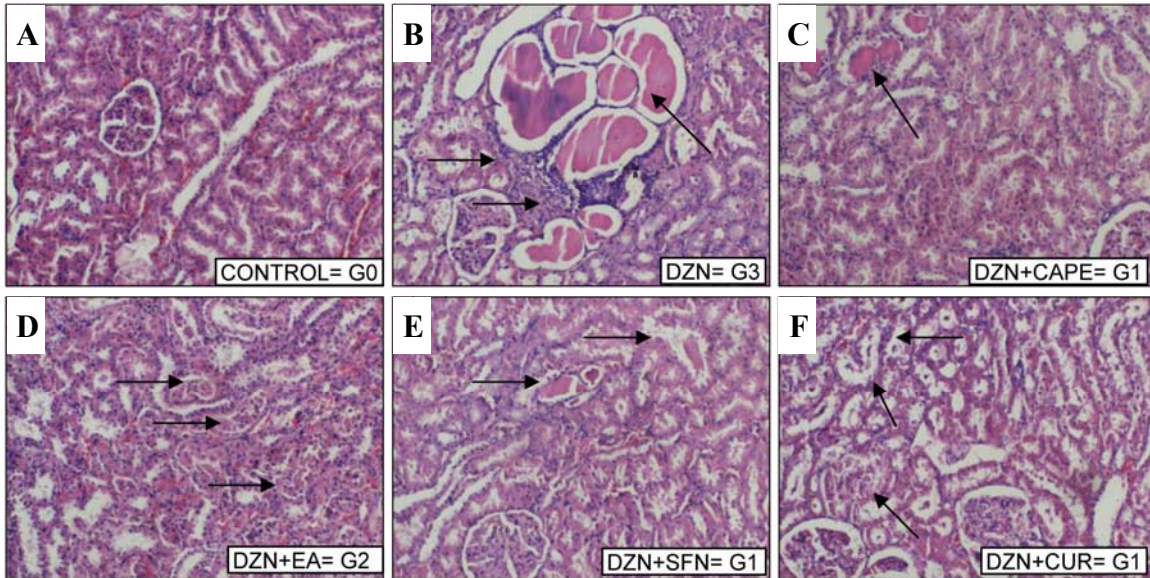


Fig 2. Kidney histology in an unmedicated control rats (A), in diazinon (DI)-intoxicated rats not treated with antioxidants (B) or simultaneously treated with caffeic acid phenethyl ester (DI+CAPE) (C), ellagic acid (DI+EA) (D), sulforaphan (DI+SFN) (E) or curcumin (DI+CUR) (F). The damage grade is seen on the right of the image. Note the swelling of tubular cells and the presence of some epithelial cells into the tubule lumens in rats from the groups DI + CAPE, DI + SFN and DI + CUR (G 1), the presence of proteinous masses in the lumens in rats from the groups DI + EA (G 2) and DI (G 3) and to the neutrophil and mononuclear cell infiltrates in the interstitium in the rat from the group DI (G 3). Haematoxylin and eosin staining, original magnification X 100. The arrows indicate the damaged areas

Şekil 2. Grupların böbrek histolojisi. İlaçsız kontrol grubu sıçanların (A), antioksidanlar uygulanmamış ve yalnızca diazinon (DI) ile toksikasyona uğramış sıçanların (B), DI ile birlikte sırasıyla; kafeik asit fenetil ester (CAPE) uygulanmış sıçanların (DI + CAPE) (C), elajik asit (DI + EA) (D), sulforaphan (DI + SFN) (E) ve curcumin (DI + CUR) (F) olarak belirtilmiştir. Resimlerin sağ tarafında histopatolojik hasar derecesi (G) gösterilmiştir. DI + CAPE, DI + SFN ve DI + CUR gruplarındaki sıçanların tubul lumenlerinde bazı epitelyal hücrelerin varlığı ve tubuler hücrelerin şişmesi (G 1), DI + EA (G 2) ve DI (G 3) gruplarındaki sıçanların lumenlerinde protein birikintilerinin varlığı (G 2 ve G 3). DI gruplarındaki sıçanların interstisyumlarında mononükleer ve nötrofil hücre infiltrasyonu (G 3) şeklinde belirtilmiştir. Hematoksilen ve eozin, orijinal büyüme X 100. Oklar hasarlı alanları göstermektedir

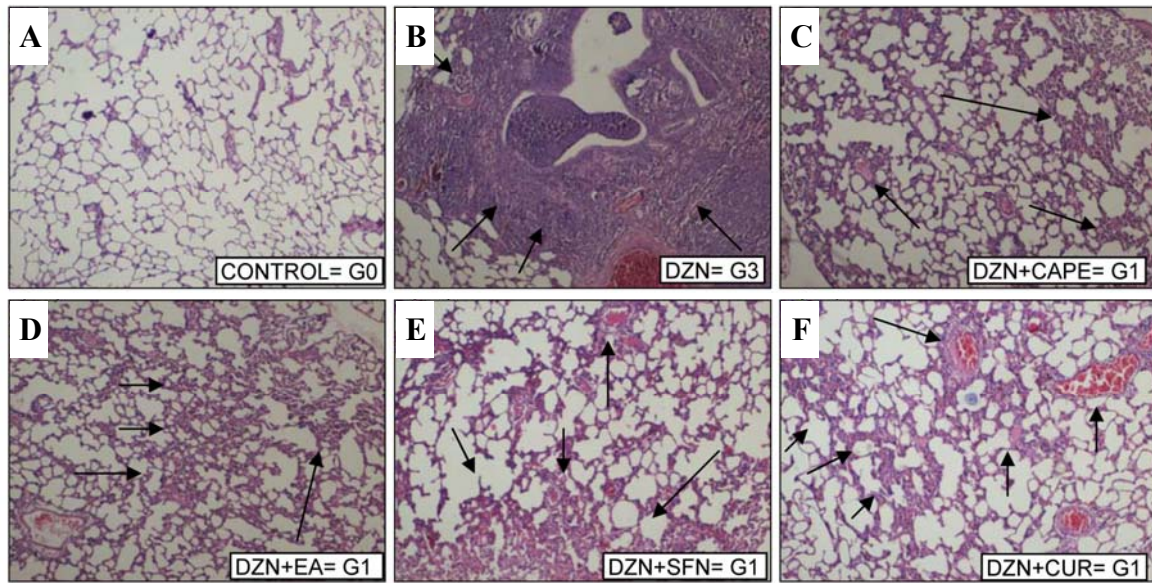


Fig 3. Lung histology in an unmedicated control rat (A), in diazinon (DI) - intoxicated rats not treated with antioxidants (B) or simultaneously treated with caffeic acid phenethyl ester (DI + CAPE) (C), ellagic acid (DI + EA) (D), sulforaphan (DI + SFN) (E) or curcumin (DI + CUR) (F). The damage grade (G) is seen on the right of the image. Note the mild oedema and hyperhaemia in alveoli associated to perivascular infiltration in rats from the groups DI + CAPE, DI + EA, DI + SFN and DI + CUR (G 1), and the severe oedema coupled to the alveolar wall thickening, strong peribronchial infiltrations and parenchymal fibrosis in the rat from the group DI (G 3). Haematoxylin and eosin staining, original magnification X 40. The arrows indicate the damaged areas

Şekil 3. Grupların akciğer histolojisi. İlaçsız kontrol grubu sıçanların (A), antioksidanlar uygulanmamış ve yalnızca diazinon (DI) ile toksikasyona uğramış sıçanların (B), DI ile birlikte sırasıyla; kafeik asit fenetil ester (CAPE) uygulanmış sıçanların (DI + CAPE) (C), elajik asit (DI + EA) (D), sulforaphan (DI + SFN) (E) ve curcumin (DI + CUR) (F) olarak belirtilmiştir. Resimlerin sağ tarafında histopatolojik hasar derecesi (G) gösterilmiştir. DI + CAPE, DI + EA, DI + SFN ve DI + CUR gruplarındaki sıçanların perivasküler infiltrasyonla ilgili alveollerde hiperemi ve orta derecede ödem varlığı (G 1) ve DI grubundaki sıçanlarda paransimal fibrozis ve güçlü peribronşiyal infiltrasyon ve ayrıca alveoler duvar kalınlaşması ile birlikte ciddi ödem varlığı (G 3) şeklinde belirtilmiştir. Hematoksilin ve eozin, orijinal büyütmeye X 40. Oklar hasarlı alanları göstermektedir

CUR had hindered the toxic effect of DI on AChE enzyme.

Another important enzyme in the diagnosis of liver, lung and kidney damage is GGT (γ -glutamyl transferase) enzyme. GGT is a membrane enzyme and is found in the liver ductal and canalicular cells, in the proximal renal tubular epithelia and in pancreatic ductal and acinar cells. Lee *et al.* reported that an increase in GGT concentration has been regarded as a marker of alcohol consumption or liver diseases such as viral hepatitis, liver cirrhosis, or liver cancer³⁰. Also, serum GGT activity has long been recognized as an effective tool for diagnosing human liver disorders, particularly intra and extra-hepatic biliary obstruction. Thomas *et al.* reported that α -naphthylisothiocyanate (ANIT) treatment increased serum GGT³¹. Paul has shown that increased urinary GGT activity was noted after treatment with aminoglycoside antibiotics, mercuric acetate and mercuric trifluoroacetate and interpreted that the measurement of urinary GGT can be used as an indicator of acute nephrotoxicity³².

In a comparison of the DI control group with the control group in the present study, there was observed to be a statistically significant increase in the levels of serum GGT. According to The histopathological examination the reason for this rise in GGT levels originated from the damage in the liver, lungs and kidneys caused by DI. Also, in the groups given SFN, CUR, CAPE and EA after DI, the decrease in DI damage to the liver, kidneys and lungs was

due to the decrease in GGT levels.

Another important enzyme in the diagnosis of OPI poisoning is amylase. In two studies on dogs by Dressel *et al.*³³ Group I (n:8) were given DI + secretin, Group II (n:8) secretin only and Group III (n:8) DI + secretin + atropine. A significant increase in serum amylase levels was reported in Group I, a non-significant increase in Group III and no change in Group II. However, Gökalp *et al.* reported that high doses of DI significantly inhibit and decrease serum amylase activity in rats³⁴. In the present study, a comparison of the control group and the DI control group showed that DI had caused an increase in serum amylase levels, contrary to the findings of Gokalp *et al.* In the present study, the results of the histopathological examination arrived at the conclusion that the reason for this was that the damage created in the liver, lungs and kidneys was dependent on the increase in serum amylase levels. A comparison of the histopathological results showed a decrease in the DI damage to lungs, liver and kidneys due to the the serum amylase levels when SFN, CUR, CAPE and EA were administered following DI, as they hindered the toxic effect of DI thus lowering the serum amylase levels.

OPI poisoning causes damage of various tissues. It has been reported that high dosage OPI poisoning causes pulmonary dysfunction, bronchioconstriction of the respiratory system, pulmonary oedema and paralysis of the respiratory muscles. It has also been reported to

destroy lung tissue epithelial cells and create widespread lymphocyte infiltration and thickening of subepithelial tissue. Similarly, in this study, while there was distinct damage to the lungs in the DI group, the damage was noticeably reduced in the groups which had been given CAPE, EA, SFN and CUR, and these 4 substances were observed to protect the lungs from the toxic effects of DI in a similar way.

The tissues most damaged by pesticides are the liver and kidneys. The liver is where pesticides undergo biotransformation and they are generally expelled by the kidneys. Therefore, it can be said that compared to other tissues, these two tissues suffer more damage³⁵. Yehia *et al.* who examined sublethal concentrations of diazinon, parathion and dimethoate have revealed histopathological changes in the liver of sea bass³⁶. In the present study, hepatocyte necrosis, degenerative changes and inflamed cell infiltration were observed.

In a study by Kalender *et al.* investigating the nephrotoxic effect of methyl parathion as an organophosphate insecticide and the protective effects of Vitamin C and E, vascular dilation and glomerular atrophy were determined in the kidney tissue 4 weeks after the administration of methyl parathion³⁷. Yehia *et al.* examined the histopathological effect of DI on rabbit kidneys, and tubule swelling, hyperplasia and cell infiltration were determined³⁸. In the present study, it was determined that hydropic degeneration, necrosis and cell infiltration observed in the kidneys were due to the administration of DI and that CAPE, EA, SFN and CUR reduced the damage.

As a result, CAPE, EA, SFN and CUR may prevent significantly the toxic effects of DI, which are seen as negative changes of the serum enzymes AChE, amylase and GGT, and as a significant degree of damage to the lungs, liver and kidneys. Also, histopathologic results indicated that these medication haven't completely eliminated the toxic effects of DI, but partially prevented and reduced the degenerative toxic effects created by DI. This research has led us to believe that CAPE, EA, SFN and CUR may be protective medications in cases of acute diazinon toxicity.

REFERENCES

- World Health Organization (WHO):** Guidelines for poison control, http://www.who.int/ipcs/publications/training_poisons/guidelines_poison_control/en/index.html.1997.
- Bagchi D, Bagchi M, Hassoun EA, Stohs SJ:** *In vitro* and *in vivo* generation of reactive oxygen species, DNA damage and lactate dehydrogenase leakage by selected pesticides. *Toxicology*, 104, 129-140, 1995.
- Colovic M, Krstic D, Petrovic S, Leskovic A, Joksic G, Savic J, Frankoc M, Trebsec P, Vasic V:** Toxic effects of diazinon and its photodegradation products. *Toxicology Letters*, 193, 9-18, 2010.
- Cox C:** Diazinon. *J Pestic Reform*, 12, 30-35, 1992.
- Ilhan A, Koltuksuz U, Ozen S, Uz E, Ciralik H, Akyol O:** The effects of caffeic acid phenethyl ester (CAPE) on spinal cord ischemia/reperfusion injury in rabbits. *Eur J Cardio Thorac Surg*, 16, 458-463, 1999.
- Hepsen IF, Bayramlar H, Gultek A, Ozen S, Tilgen F, Evereklioglu C:** Caffeic acid phenethyl ester to inhibit posterior capsule opacification in rabbits. *J Cataract Refract Surg*, 23, 1572-1576, 1997.
- Orhan H, Marol S, Hepsen IF, Sahin G:** Effects of some probable antioxidants on selenite-induced cataract formation and oxidative stress-related parameters in rats. *Toxicology*, 139, 219-232, 1999.
- Uz E, Sogut S, Sahin S, Var A, Ozyurt H, Gulec M, Akyol O:** The protective role of caffeic acid phenethyl ester (CAPE) on testicular tissue after testicular torsion and detorsion. *World J Urol*, 20, 264-270, 2002.
- Gurel A, Armutcu F, Hosnuter M, Unalacak M, Kargi E, Altinyazar C:** Caffeic acid phenethyl ester improves oxidative organ damage in rat model of thermal trauma. *Physiol Res*, 53, 675-682, 2004.
- Zhu H, Jia Z, Strobl JS, Ehrich M, Misra HP, Li Y:** Potent induction of total cellular and mitochondrial antioxidants and phase 2 enzymes by cruciferous sulforaphane in rat aortic smooth muscle cells: Cytoprotection against oxidative and electrophilic stress. *Cardiovasc Toxicol*, 8, 115-125, 2008.
- Zhao J, Kobori N, Aronowski J, Dasha PK:** Sulforaphane reduces infarct volume following focal cerebral ischemia in rodents. *Neuroscience Letters*, 393, 108-112, 2006.
- Hu R, Hebbbar V, Kim BR, Chen C, Winnik B, Buckley B, Soteropoulos P, Tolia P, Hart RP, Kong ANT:** *In Vivo* pharmacokinetics and regulation of gene expression profiles by isothiocyanate sulforaphane in the rat. *J Pharmacol Exp Ther*, 310, 263-271, 2009.
- Hanlon N, Coldham N, Gielbert A, Kuhnert N, Sauer MJ, King LJ:** Absolute bioavailability and dose-dependent pharmacokinetic behaviour of dietary doses of the chemopreventive isothiocyanate sulforaphane in rat. *Br J Nutr*, 99, 559-564, 2008.
- Yoon HY, Kang NI, Lee HK, Jang KY, Park JW:** Sulforaphane protects kidneys against ischemia-reperfusion injury through induction of the Nrf2-dependent phase 2 enzyme. *Biochem Pharmacol*, 75, 2214-2223, 2008.
- Thiyagarajan M, Sharma SS:** Neuroprotective effect of curcumin in middle cerebral artery occlusion induced focal cerebral ischemia in rats. *Life Sci*, 74, 969-985, 2004.
- Reddy AC, Lokesh BR:** Studies on the inhibitory effects of curcumin and eugenol on the formation of reactive oxygen species and the oxidation of ferrous iron. *Mol Cell Biochem*, 137, 1-8, 1994.
- Sreejayan Rao MN:** Nitric oxide scavenging by curcuminoids. *J Pharm Pharmacol*, 49, 105-107, 1997.
- Yuca A, Atessahin A, Ceribasi AO:** Amelioration of cyclosporine A-induced renal, hepatic and cardiac damages by ellagic acid in rats. *Basic Clin Pharmacol Toxicol*, 103, 186-191, 2008.
- Hassoun EA, Vodhanel J, Abushaban A:** The modulatory effects of ellagic acid and vitamin E succinate on TCDD-induced oxidative stress in different brain regions of rats after subchronic exposure. *J Biochem Mol Toxicol*, 18, 196-203, 2004.
- Alp H, Aytakin I, Esen H, Alp A, Buyukbas S, Basarali K, Hatipoglu NK, Kul S:** Protective effects of caffeic acid phenethyl ester, ellagic acid, sulforaphan and curcuma on malathion induced damage in lungs, liver and kidneys in an acute toxicity rat model. *Revue Méd Vét*, 162, 333-340, 2011.
- Sahin HA, Sahin I, Arabaci F:** Sociodemographic factors in organophosphate poisonings: A prospective study. *Hum Exp Toxicol*, 22, 349-353, 2003.
- Panieri E, Krige JE, Bornman PC, Linton DM:** Severe necrotizing pancreatitis caused by organophosphate poisoning. *J Clin Gastroenterol*, 25, 463-465, 1997.
- Dressel TD, Goodale RL Jr, Hunninghake DB, Borner JW:** Sensitivity of the canine pancreatic intraductal pressure to subclinical reduction in cholinesterase activity. *Ann Surg*, 190, 6-12, 1979.
- Gokcimen A, Gulle K, Demirin H, Bayram D, Kocak A, Altuntas I:** Effects of diazinon at different doses on rat liver and pancreas tissues. *Pestic Biochem Physiol*, 87, 103-108, 2007.

- 25. Slotkin TA, Levin ED, Seidler FJ:** Comparative developmental neurotoxicity of organophosphate insecticides: Effects on brain development are separable from systemic toxicity. *Environ Health Perspect*, 114, 746-751, 2006.
- 26. Alp H, Aytekin I, Atakisi O, Hatipoglu NK, Basarali K, Ogun M, Buyukbas S, Altintas L, Ekici H, Alp A:** The effects of caffeic acid penethyl ester and ellagic acid on the levels of malondialdehyde, reduced glutathione and nitric oxide in the lung, liver and kidney tissues in acute diazinon toxicity in rats. *J Anim Vet Adv*, 10, 1488-1494, 2011.
- 27. Dutta HM, Meijer HJ:** Sublethal effects of diazinon on the structure of the testis of bluegill, *Lepomis macrochirus*: A microscopic analysis. *Environ Pollut*, 125, 355-356, 2003.
- 28. Dembélé K, Haubruge E, Gaspar C:** Concentration effects of selected insecticides on brain acetylcholinesterase in the common carp (*Cyprinus carpio* L.). *Ecotoxicol Environ Saf*, 45, 49-54, 2000.
- 29. Day KE, Scott IM:** Use of acetylcholinesterase activity to detect sublethal toxicity in stream invertebrates exposed to low concentrations of organophosphate insecticides. *Aquat Toxicol*, 18, 101-114, 1990.
- 30. Lee DH, Ha MH, Kim JH, Christiani DC, Gross MD, Steffes M, Blomhoff R, Jacobs DR:** Gamma-glutamyltransferase and diabetes - A 4 year follow-up study. *Diabetologia*, 46, 359-364, 2003.
- 31. Thomas BL, Douglas AN, James AP:** Serum gamma glutamyl transferase as a specific indicator of bile duct lesions in the rat liver. *Chem Ind Inst Toxicol*, 116 (2): 1984.
- 32. Paul JD:** Urinary gamma-glutamyl transferase as an indicator of acute nephrotoxicity in rats. *Arch Toxicol*, 47, 209-215, 1981.
- 33. Dressel TD, Goodale RL Jr, Zweber B, Borner JW:** The effect of atropine and duct decompression on the evolution of Diazinon-induced acute canine pancreatitis. *Ann Surg*, 195, 424-434, 1982.
- 34. Gokalp O, Altuntas I, Koylu H:** The effects of diazinon on pancreatic damage and ameliorating role of vitamin E and vitamin C. *Pestic Biochem Physiol*, 81, 123-128, 2005.
- 35. Kalender S, Kalender Y, Ogutcu A, Uzunhisarcikli M, Durak D, Acikgoz F:** Endosulfan-induced cardiotoxicity and free radical metabolism in rats: The protective effect of vitamin E. *Toxicology*, 3, 227-235, 2004.
- 36. Murty AS:** Toxicity of pesticides to fish. *CRR Pres*, 2, 76-80, 1986.
- 37. Kalender S, Kalender Y, Durak D, Ogutcu A, Uzunhisarcikli M, Cevrimli BS, Yıldırım M:** Methyl parathion induced nephrotoxicity in male rats and protective role of vitamins C and E. *Pestic Biochem Physiol*, 88, 213-218, 2007.
- 38. Yehia MAH, El-Banna SG, Okab AB:** Diazinon toxicity affects histophysiological and biochemical parameters in rabbits. *Exp Toxicol Pathol*, 59, 215-225, 2007.