

L4-L5 SPONDİLOLİSTEZİS VE FASET KİSTİ

L4-L5 Spondylolisthesis and Facet cyst

Metin GÜREL¹, Olcay ESER²

ÖZET

Faset eklem kistleri genellikle birleşik fasetteki osteoartrit ve/veya spondilolistezise bağlıdır. Biz bu vakada 45 yaşında sol bacak ağrısı olan bir bayan hastayı sunduk. Hastanın manyetik lomber görüntülemesinde L4-L5 seviyesinde faset kisti ve 2. derece spondilolistezis izleniyordu. Cerrahide L3 parsiyel, L4 total laminektomiye takiben total faset kist eksizyonu uygulandı. Spondilolistezis nedeniyle L3-L4-L5 posterior pediküler fiksasyon ve füzyon yapıldı. Hastanın ameliyat sonrası herhangi bir semptomu kalmadı.

Anahtar Kelimeler: *Faset kisti; Spondilolistezis.*

ABSTRACT

Facet joint cysts are usually associated with osteoarthritis of the adjacent facet joint and/ or spondylolisthesis.

In this report we describe a 45 year old woman patient presenting with left leg pain. Magnetic resonance imaging of spine revealed a facet cyst at L4-L5 left facet joint with L4-L5 grade 2 spondylolisthesis. At the surgery L3 partial, L4 total laminectomy and total cyst excision was done. Because of the spondylolisthesis L3-L4-L5 posterior transpedicular fixation and fusion made. The patient remained symptom free after operation.

Key words: *Facet cyst; Spondylolisthesis.*

¹Konya Meram Resource and Education Hospital, Neurosurgery Department, Konya

²Department of Neurosurgery, Balıkesir University, Balıkesir, Turkey

Metin GÜREL, Uzm. Dr.
Olcay ESER, Prof. Dr.

İletişim:

Dr. Metin GÜREL
Meram Resource and Education Hospital, Department of Neurosurgery, Konya, Turkey
Tel: +090 505 3910271
e-mail:
gurelmetin@hotmail.com

Geliş tarihi/Received: 16.02.2015
Kabul tarihi/Accepted: 15.06.2016

Bozok Tıp Derg 2016;6(3):73-6
Bozok Med J 2016;6(3):73-6

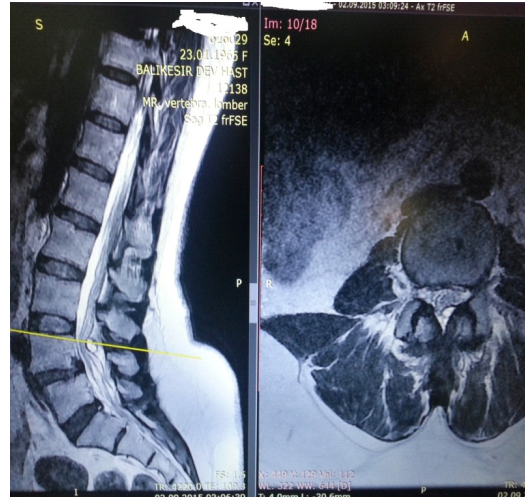
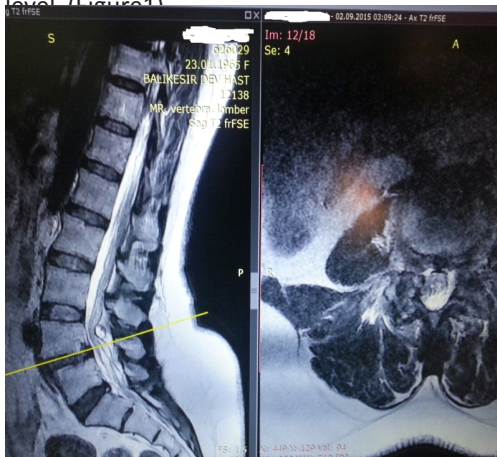INTRODUCTION

Synovial cysts of the spine are arised from the zygapophyseal joint capsule of lumbar spine which often causes radicular pain the number of reported synovial cysts of the lumbar spine has been increasing likely due to availability of the technique of magnetic resonance imaging (MRI) These cysts are usually associated with osteoarthritis of the adjent facet joint and/ or spondylolisthesis particularly in middle aged or elderly patients. (1)

Conservative treatments; such as medications and facet joint or epidural enjections are sometime effective. Although surgical resection is required in some case due to persistant radikular symtoms and / or occasional paresis (2). As facet cysts seem to be mainly releated to spinal segmental instability which will eventually resolve as the spine settles in to the stabilization phase of degeneration (3). In this report we describe an facet joint cyst with spondylolisthesis succesfully treated by total exision and posterior stabilization with fusion.In such cases where instability is present, joint facet preservation will not be necessary and subsequent segmental instrumentation would be recommended (4).

CASE REPORT

A 45 years old woman who had a left leg pain on walking.She had neurologic claudication. There was no power lose .Sensation was normal all modalities Lateral lumbosakral X-Ray graphi shows the listesis at L4-L5 level. (Figure1)



Figures1-2: Magnetic resonans imaging of L4-L5 grade2 spondilolisthesis and facet joint cyst

Magnetic rezonans imaging scan showed grade 2 L4-L5spondilolisthesis with facet joint cyst (Figure 2-3). Lumbar tomography scan at the L4-L5 level bilateral pars interarticularis fracture seen.

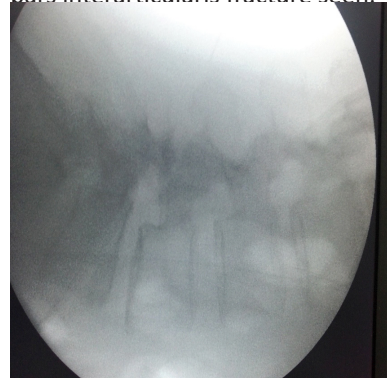

Figure 3: Per op lumbar X-ray imaging showing spondilolisthesis

At surgery left L3 hemiparsiel laminectomy, L4 total laminectomy was done (Figure 4). Total cyst exision made (Figure5). After this L3-L4-L5 posterior pedicular fixation and fusion was performed (Figure6).

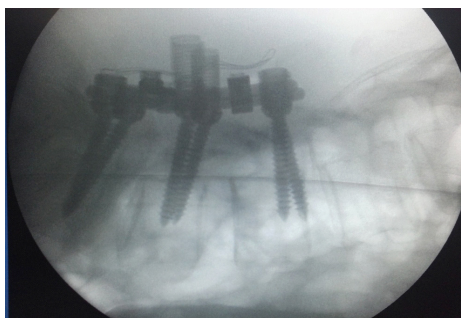


Figure 4: Post op transpedicular fixation

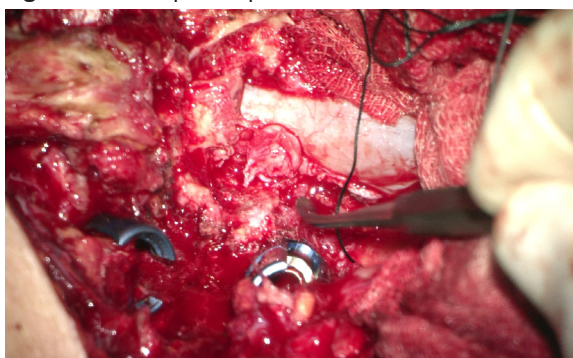


Figure 5:The facet cyst which is attached to the dura mater and facet joint ,(arrow) duramatter of spine cord (arrowhead)

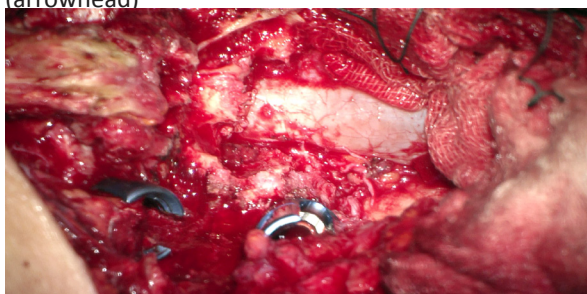


Figure 6: After exision of the facet cyst

DISCUSSION

Synovial cysts arising from the lumbar spine facet joints are most commonly seen in the setting of degenerative spondylosis of the facet joints. The incidence of lumbar facet synovial cysts detected by imaging ranges from

0.8–2.0%. Lumbar facet joint cysts most commonly arise at the L4-L5 spinal level. On MR imaging, synovial cysts are typically T2-hyperintense and T1-hypointense, but the cyst signal is variable, depending on protein content, previous hemorrhage, and calcification (5, 6).

Synovial cysts of the spine are cystic formations connected to the facet joint and containing synovial fluid lined by a cuboid or pseudostratified columnar epithelium. They may result in lumbar radiculopathy in a significant number of cases (7).

Instability conditions such as degenerative spondylolisthesis (DS) in segments of the lumbar spine are common reasons for surgical treatment. These alterations are often associated with spinal stenosis. Facet joint cysts and osteoarthritis of the facets. Patients mainly suffer from low back pain and radicular pain or spinal claudication. Facet cysts are a relatively common source of neural compression in the lumbar spine (6). Open decompression and fusion are frequently used to treat the stenosis and instability associated with this pathology. Intraspinous synovial cysts are usually located in the lower lumbar spine and most of them are adjacent to the facet joint. These cysts that are located on the midline are very rare (2). Large (> 1.5 mm) facet effusions are highly predictive of degenerative spondylolisthesis at L4-L5 in the absence of measurable anterolisthesis on supine MR (8).

Synovial cysts are thought to be related to degenerative spinal changes and segmental instability, with retrospective studies supporting these hypotheses (8). MRI prevalence studies have also shown cysts to have significant associations with facet arthropathy, facet joint osteoarthritis, and spondylolisthesis (9).

Symptomatic synovial cysts of the lumbar spine were associated with degenerative spondylolisthesis and with instability of the facet joint. These findings may support the theory that increased segmental motion plays a role in the pathogenesis of synovial cysts (10). In treating synovial cysts, the primary aim is relief of the pain symptoms, while the secondary focus is laid on minimizing instability. Some authors suggest that patients with instability, detected on flexion-extension x-rays, need to receive fusion upfront (11). Lumbar

synovial cysts are an increasingly common finding on MR imaging in both symptomatic and asymptomatic populations. Trauma may play a role in their formation and a higher index of suspicion may be warranted in males with active occupations (11). Synovial cysts of the lumbar spine contribute significantly to narrowing of the spinal canal and lateral thecal sac and nerve root compression. Cysts form as a result of arthrotic disruption of the facet joint, leading to degenerative spondylolisthesis in up to 40% of patients.

CONCLUSION

Lumbar synovial cyst surgery includes unilateral or bilateral laminotomies, hemilaminectomies, or laminectomies alone or in combination with in situ or instrumented fusion.

Surgical decompression with cyst excision remains the treatment of choice. In patients with associated pars defect or spondylolisthesis, lumbar decompression with resection of cysts may not be enough to reduce back pain symptoms warranting concurrent fusion or pars repair for better symptomatic relief. Open surgery is conventional approach often supplemented by fusion. Synovial cyst of the lumbar spine is rare pathology with spondylolisthesis which can cause severe pain and is difficult to resolve by conservative management (4). In our case we made total cyst excision and above the spondylolisthesis ; L3-L4-L5 posterior transpedicular fixation and fusion.

REFERENCES

1. Lattig F, Fekete TF, Grob D, Kleinstück FS, Jeszenszky D, Mannion AF. Lumbar facet joint effusion in MRI: a sign of instability in degenerative spondylolisthesis? *Eur Spine J*. 2012;21(2):276-81.
2. Massey GM, Caputo AM, Michael KW, Isaacs RE. Lumbar facet cyst resolution following anterior interbody fusion. *Clin Neurosci*. 2013;20(12):1771-3.
3. Reust P, Wendling D, Lagier R, Pageaut G, Reverdin A, Jaquet G et al. Degenerative spondylolisthesis, synovial cyst of the zygapophyseal joints, and sciatic syndrome: report of two cases and review of the literature. *Arthritis Rheum*. 1988;31(2):288-94.
4. Campa-Santamarina JT, Towne S, Alimi M, Navarro-Ramirez R, Roger H. Minimally Invasive Approach For Extraforaminal Synovial Cyst L5-S1. *Curues*. 2015; 7(10):362
5. Chaput C, Padon D, Rush J, Lenehan E, Rahm M. The significance of increased fluid signal on magnetic resonance imaging in lumbar facets in relationship to degenerative spondylolisthesis. 2007;32(17):1883-7.
6. HS Bae JY, In CB, Choi EJ, Lee PB, Nahm FS. Epiduroscopic Removal of a Lumbar Facet Joint Cyst. *Korean J Pain*. 2015;28(4):275-9.
7. Cambron SC, McIntyre JJ, Guerin SJ, Li Z, Pastel DA. Lumbar facet joint synovial cysts: does T2 signal intensity predict outcomes after percutaneous rupture? *AJNR Am J Neuroradiol*. 2013;34(8):1661-4.
8. Nakayama S, Fujino H, Inomori S, Shuto T, Basugi N, Kuwabara T. A case of a lumbar spinal synovial cyst located on the midline. *No Shinkei Geka*. 1998;26(8):717-22.
9. Kjerulf TD, Terry DW Jr, Boubelik RJ. Lumbar synovial or ganglion cysts. *Neurosurgery*. 1986; 9(3):415-20.
10. Doyle AJ, Merrilees M. Synovial cysts of the lumbar facet joints in a symptomatic population: prevalence on magnetic resonance imaging. *Spine*. 2004; 29(8):874-8.
11. Apostolaki E, Davies AM, Evans N, Cassar-Pullicino VN. MR imaging of lumbar facet joint synovial cysts. *Eur Radiol*. 2000;10(4):615-23.