

A Case of Unilateral Purtscher Like Retinopathy After Spinal Surgery

Spinal Cerrahi Sonrasında Tek Taraflı Purtscher Benzeri Retinopati Olgusu

Esin SÖĞÜTLÜ SARI,^a
 Işıl KUTLUTÜRK,^b
 Alper YAZICI,^a
 Nesime TISKAOĞLU^a

^aDepartment of Ophthalmology,
 Balıkesir University Faculty of Medicine,
 Balıkesir

^bClinic of Ophthalmology,
 Kocaeli State Hospital,
 Kocaeli

Received: 02.03.2016
 Received in revised form: 12.06.2016
 Accepted: 13.06.2016
 Available online: 22.02.2018

Correspondence:
 Esin SÖĞÜTLÜ SARI
 Balıkesir University Faculty of Medicine,
 Department of Ophthalmology, Balıkesir,
 TÜRKİYE/TURKEY
 dresinsogutlu@gmail.com

ABSTRACT Purtscher like retinopathy has the same presentation like Purtscher retinopathy but without any trauma history. A 48-year-old female presented to our clinic with a one month history of severe visual loss in her left eye. She had no systemic illness or trauma history. She had undergone disc herniation surgery one month before when applied to us. Her laboratory findings were normal but a slightly elevated total cholesterol level. Her vision was 20/20 in the right eye and counting fingers at 50 centimeter in the left eye. Fundus examination showed patched pattern of retinal whitening and hemorrhages. The clinical presentation of the patient might be related to increased orbital pressure due extended interval of prone positioning that led to chest compression.

Keywords: Purtscher like retinopathy; spinal surgery; trauma

ÖZET Purtscher benzeri retinopati Purtscher retinopati ile aynı klinik bulgulara sahiptir ancak hastada travma öyküsü bulunmaz. Kırk sekiz yaşında kadın hasta bir aydır var olan sol gözde görme kaybı şikayeti ile başvurdu. Hastanın travma ya da sistemik hastalık hikayesi yoktu. Hasta kliniğimize başvurusundan bir ay önce disk herni ameliyatı geçirmişti. Laboratuvar incelemesinde hafifçe artmış total kan kolesterol düzeyi dışında bir anormallik yoktu. Görme keskinliği sağ gözde tam, sol gözde 50 santimetreden parmak sayma düzeyinde idi. Fundus muayenesinde yama şeklinde retinal beyazlaşma ve kanamalar mevcuttu. Hastanın klinik görünümünün, uzun süre yüzüstü pozisyonun yol açtığı göğüs kompresyonunun orbita basıncını artırması ile ilişkili olabileceği düşünüldü.

Anahtar Kelimeler: Purtscher benzeri retinopati; spinal cerrahi; travma

Purtscher retinopathy is a traumatic angiopathy first described by Otmar Purtscher evaluating a head trauma patient in 1910.¹ The etiology is not known clearly but believed to be associated with occlusion of the arterioles that supplies the peripapillary capillaries.² Although the first case described in literature was a trauma case, Purtscher like retinopathy has been defined in different conditions such as acute pancreatitis, childbirth, chronic renal failure, barotrauma, steroid injections in and around the orbit and nasal passages, retrobulbar anesthesia, retinal vasculitis associated with autoantibodies, preeclampsia, lupus and other non-trauma related cases.²⁻⁴ The diagnostic clinical findings of Purtscher retinopathy is seen bilaterally in 60% of cases.³ They are localized to the peripapillary area and posterior pole of the retina. It is a clinical diagnosis with ophthalmoscopic

features consisting of cotton wool spots, Purtscher flecken, retinal hemorrhages and a pale oedematous optic disc.⁵

CASE REPORT

A 48-year-old female presented to our clinic with severe visual loss in her left eye for one month. She had undergone surgery for a disc herniation one month before. The surgery was a two-hour procedure with no complication. Her laboratory findings were normal but a slightly elevated total cholesterol level. Her vision was 20/20 in the right eye and counting fingers at 50 centimeter in the left eye. On fundus examination, the right eye was normal but the left eye revealed cotton wool spots surrounding the optic disc in a concentric pattern, pre and intraretinal hemorrhages and Purtscher flecken with pale edematous optic nerve head (Figure 1). A fundus fluorescein angiogram (FFA) revealed blockage by intraretinal hemorrhages and cotton wool spots (Figure 2). Macular optical coherence tomography showed retinal nerve fiber layer swelling (Figure 3). Informed consent was obtained from the patient.

DISCUSSION

Purtscher retinopathy is a rare condition seen mostly in male patients who have suffered traumas.⁵ While the exact pathogenesis of the disease is still unknown, many theories have been put for-

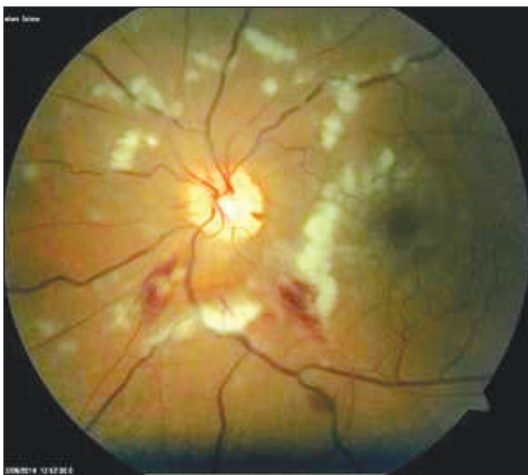


FIGURE 1: Color fundus photo reveals cotton wool spots and retinal hemorrhages at the posterior pole which are seen as hypo-fluorescent in angiographic images.

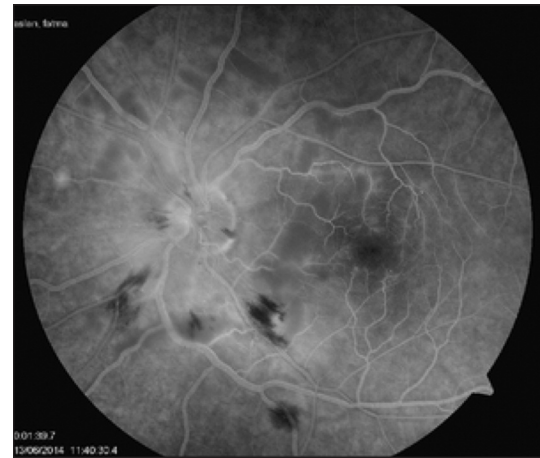


FIGURE 2: Late fundus fluorescein angiography image demonstrated fluorescein blockage areas related to the cotton wool spots and retinal hemorrhage.

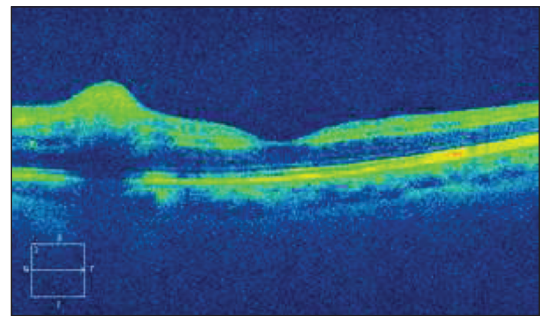


FIGURE 3: Optical coherence tomography showed retinal fiber layer swelling.

ward such as lymph extravasation due to an increase in intracranial pressure, venous dilatation due to an increased intrathoracic pressure, vasculitis secondary to lipase and microemboli in the arterioles potentially arising from air, fat, fibrin clots and leucocyte aggregates. The most recent mechanism is the vascular endothelial dysregulation resulting from a rheological event at inner retinal layer of posterior pole.^{2,6-8} In Purtscher like retinopathy, when there is non-traumatic etiology, an excessive activation of the complement system in respiratory distress, acute pancreatitis, connective tissue disorders, amniotic fluid and renal failure can lead to leukocyte aggregation. Patients generally present within 24-48 hours after the causing event with loss of visual acuity and accompanying visual field loss but in some cases vision loss of variable severity is realized in hours to days after the initial pathology.^{5,6} In the present

case although there was no trauma or sudden thoracic compression or any other reasons of Purtscher like retinopathy ethology history, it was present to clinical findings of Purtscher retinopathy. Because the patient had a long time prone position after spinal surgery. This event supports the theory of venous reflux occurring after sudden chest trauma or interventions of prolonged prone position.⁹

Although, no current consensus on the treatment of this disorder; the steroids have been reported to be ameliorative effect in some cases. Agarwal et al reported a spontaneous visual recovery in 50% of the cases.⁶ Spontaneous recovery of visual acuity and field is generally seen within 3-6 weeks. Our patient did not have any apparent reason when applied. We believe the loss of vision is associated with the surgery she had before. Purtscher flecken, cotton wool spots and retinal hemorrhages have been reported to might persist for a month. Atrophy of the retinal pigment epithelium and optic disc pallor are associated findings of Purtscher retinopathy.^{5,7}

The ethology is not still clear because of limited reports of the different type of Purtscher retinopathy cases. To our knowledge, this is the first case of Purtscher like retinopathy following

spinal surgery. Our case is also unique due to late admission and the lack of improvement in symptoms.

Source of Finance

During this study, no financial or spiritual support was received neither from any pharmaceutical company that has a direct connection with the research subject, nor from a company that provides or produces medical instruments and materials which may negatively affect the evaluation process of this study.

Conflict of Interest

No conflicts of interest between the authors and / or family members of the scientific and medical committee members or members of the potential conflicts of interest, counseling, expertise, working conditions, share holding and similar situations in any firm.

Authorship Contributions

Idea/Concept: Esin Söğütlü Sarı; **Design:** Esin Söğütlü Sarı, Işıl Kutlutürk; **Control/Supervision:** Esin Söğütlü Sarı; **Data Collection and/or Processing:** Esin Söğütlü Sarı, Nesime Tıskaoğlu; **Analysis and/or Interpretation:** Esin Söğütlü Sarı, Nesime Tıskaoğlu, Alper Yazıcı; **Literature Review:** Alper Yazıcı, Işıl Kutlutürk, Esin Söğütlü Sarı, Nesime Tıskaoğlu; **Writing the Article:** Alper Yazıcı, Işıl Kutlutürk, Esin Söğütlü Sarı, Nesime Tıskaoğlu; **Critical Review:** Alper Yazıcı, Işıl Kutlutürk, Esin Söğütlü Sarı, Nesime Tıskaoğlu; **References and Fundings:** Esin Söğütlü Sarı; **Materials:** Alper Yazıcı, Işıl Kutlutürk, Esin Söğütlü Sarı, Nesime Tıskaoğlu.

REFERENCES

1. Yalçınbayır Ö, Toka F. [Purtscher's retinopathy and Terson's syndrome]. Ret-Vit 2012;20 Özel Sayı:71-5.
2. Buckley SA, James S. Purtscher's retinopathy. Postgrad Med J 1996;72(849):409-12.
3. Jeon SY, Jung E, Seol HJ, Hur YJ. Development of Purtscher-like retinopathy after pre-eclampsia combined with acute pancreatitis. Obstet Gynecol Sci 2013;56(4):261-4.
4. Mayer C, Khoramnia R. Purtscher-like retinopathy caused by acute pancreatitis. Lancet 2011;378(9803):1653.
5. Agrawal A, McKibbin M. Purtscher's retinopathy: epidemiology, clinical features and outcome. Br J Ophthalmol 2007;91(11):1456-9.
6. Agrawal A, McKibbin MA. Purtscher's and Purtscher-like retinopathies: a review. Surv Ophthalmol 2006;51(2):129-36.
7. Günenç Ü, Önal A, Erkin E, Saatçi AO, Maden A, Ergin M. [A case of bilateral Purtscher retinopathy]. Turkiye Klinikleri J Ophthalmol 1995;4(2):142-5.
8. Miguel AI, Henriques F, Azevedo LF, Loureiro AJ, Maberley DA. Systematic review of Purtscher's and Purtscher-like retinopathies. Eye (Lond) 2013;27(1):1-13.
9. Niggemann P, Seifert M, Förg A, Schild HH, Urbach H, Krings T. Positional venous MR angiography: an operator-independent tool to evaluate cerebral venous outflow hemodynamics. AJNR Am J Neuroradiol 2012;33(2):246-51.