



DOI: 10.14744/eur.2024.58070
Eur Eye Res 2024;4(2):115–121

EUROPEAN
EYE
RESEARCH

ORIGINAL ARTICLE

Evaluation of ocular surface features following corneal collagen cross-linking treatment in keratoconus patients: 24-month results

 Gozde Sahin Vural,¹  Esin Sogutlu Sari,²  Alper Yazici,³  Cenap Guler¹

¹Department of Ophthalmology, Balıkesir University, Balıkesir, Türkiye

²Department of Ophthalmology, Uludağ University, Bursa, Türkiye

³Department of Ophthalmology, West Eye Hospital, Izmir, Türkiye

Abstract

Purpose: The aim of the study was to determine the effects of corneal collagen cross-linking (CXL) on tear function parameters in a long-term period retrospectively.

Methods: Twenty-four eyes of 17 keratoconus patients after CXL treatment were included in the study. The ocular surface disease index questionnaire (OSDI), tear osmolarity, tear break-up time (T-BUT), Oxford ocular surface staining score, Schirmer I test, and the National Eye Institute Visual Function Questionnaire-25 were performed before and after CXL at 1st and 24th months. All parameters were compared.

Results: Tear osmolarity significantly increased during follow-up ($p=0.001$). The increment in T-BUT was significant between pre-operative and 1st month ($p=0.001$). Oxford grading score increased progressively but the difference was only significant between pre-operative and 24 months ($p<0.05$). Schirmer's score improved at 1st month but altered in favor of dry eye at 24 months similar to T-BUT. OSDI and tear osmolarity were significantly increased in all visits ($p<0.05$).

Conclusion: Dry eye disorder was demonstrated as a significant complication of CXL in keratoconic eyes in a long-term period. Even if we performed CXL at early times, we need to follow patients for ocular surface disorders as well as topographic progression for the period of long time because the side effects of CXL on the ocular surface last up to 24 months.

Keywords: Cross-linking; dry eye disorder; keratoconus; tear osmolarity.

Keratoconus is an asymmetric corneal disorder that may progress and cause steepening, thinning, and distortion of the cornea. In recent years, a new method, corneal collagen cross-linking (CXL), has been applied to prevent the progression of corneal ectasia.^[1] During the procedure, the corneal epithelium is usually removed and UV-A ex-

posure is applied. Both removals of epithelium and UV-A exposure damage to subepithelial nerve plexus and decrease corneal sensitivity. Damage in corneal nerves and decreased corneal sensitivity may lead to inhibition of blinking and induce basic tear secretion.^[2]

It has been proposed that keratoconus is related to ocular



Cite this article as: Sahin Vural G, Sogutlu Sari E, Yazici A, Guler C. Evaluation of ocular surface features following corneal collagen cross-linking treatment in keratoconus patients: 24-month results. Eur Eye Res 2024;4(2):115–121.

Correspondence: Gozde Sahin Vural, M.D. Department of Ophthalmology, Balıkesir University, Balıkesir, Türkiye

E-mail: gozdejcgri@hotmail.com

Submitted Date: 17.10.2023 **Revised Date:** 07.12.2023 **Accepted Date:** 02.01.2024 **Available Online Date:** 01.08.2024

OPEN ACCESS This is an open access article under the CC BY-NC license (<http://creativecommons.org/licenses/by-nc/4.0/>).



surface disorders such as tear quality reduction, goblet cell loss, and squamous metaplasia.^[3] Ocular surface disorders and impaired tear function lead to visual distortion and optical aberrations.^[4,5] Furthermore, ocular surface disorders related to abnormal corneal nerve morphology are seen in keratoconus patients and these pathologies initiate ocular discomfort and life quality impairment.^[6] In addition to keratoconus-related ocular surface disorders, CXL may have a synergistic effect on tear functions. We consider that the effect of CXL on ocular surface is significant. Therefore, we hypothesized that reduced corneal sensitivity after CXL may decrease blink rate, and increase exposure of corneal epithelium and tear evaporation. Related to these factors, ocular surface pathologies such as dry eye disorder and tear dysfunction may occur. For this reason, we followed ocular surface parameters in keratoconus patients until 24 months after CXL and compared them with pre-operative values.

Materials and Methods

This retrospective study followed the tenets of the Declaration of Helsinki, and it was approved by the local ethical committee (Registration Number: 2021/43). All participants gave informed consent. A power analysis was performed to determine the number of patients that needed to be enrolled in the study. The keratoconus patients who have Grade 1 or 2 keratoconus according to the Amsler-Krumeich keratoconus classification system (Grade 1, eccentric corneal bulging, myopia, and/or astigmatism <5 D and corneal radius ≤ 48 D, no corneal opacities; Grade 2, myopia and/or astigmatism >5 D and <8 D and/or corneal radius ≤ 53 D, no central opacities, pachymetry ≥ 400 μm) were included.^[7] 24 eyes of 17 mild-or-moderate progressive keratoconus patients who have performed epi-off CXL procedure in Balıkesir University Ophthalmology Department between January and April 2017 were included in the study. All participants had ≥ 400 μ corneal thickness in pachymetry.

Age, gender, systemic disorders, and medications were noted. Exclusion criteria were a history of ocular surface disorder, ocular surgery, any type of topical drug use, and contact lens wear. All included subjects underwent a detailed ophthalmic examination including best corrected visual acuity, intraocular pressure measurement with a non-contact tonometer, biomicroscopic examination, and non-dilated fundus examination. To estimate dry eye symptoms, an ocular surface disease index questionnaire (OSDI-includes 12 questions about the effect of dry-eye symptoms on life quality; Allergan, Irvine, California, USA)

has been performed by themselves. In addition, tear osmolarity (quantified by TearLab Osmolarity System; San Diego, California, USA), tear break-up time (T-BUT), Oxford grading score of ocular surface staining (with Lissamine Green), and Schirmer I test were performed at early times of the examination day before and 1–24 months after treatment. At the final visit, the National Eye Institute Visual Function Questionnaire-25 test was additionally performed. Pre-post-treatment values were compared.

Corneal CXL Procedure

Under topical anesthesia, the corneal epithelium was removed by rubbing the central cornea with a 20% alcohol solution and scrapping with a crescent knife at an intended 8.0-mm zone mechanically. Corneal limbus and conjunctival tissues were protected from alcohol insertion and ocular surface was washed with a balanced salt solution. After that, isotonic riboflavin solution (0.1% riboflavin in 20% dextran T500 solution, Meran Medicine, BNM Inc., Istanbul, Türkiye) was applied to central cornea every 2 min for 30 min and the UV-A irradiation was applied using a commercially available UV-A system (Meran Tıp, BNM Inc., Istanbul, Türkiye) for 10 min at 9 mW/cm². At the end of irradiation, corneal epithelium was washed with 30 cc balanced salt solution. A bandage contact lens was placed over the cornea. A standardized treatment protocol which includes fluorometholone eye drops (4 times/day) and artificial tears (4 times/day) for 1 month was applied to all patients. The corneal epithelial defect was followed on the 1st, 7th, and 30th day. Any complication detected during follow-up period.

Statistical Analysis

The normality distribution was assessed by Kolmogorov–Smirnov test. Pre- and post-OSDI and tear film tests (T-BUT, Schirmer I test, Oxford scores, tear osmolarity value) within groups were compared with the paired-samples t-test. The statistically significant ratio of 5% is accepted.

Results

At the beginning of the study, 24 eyes of 17 patients were enrolled. Ten patients lost during 24 months of follow-up and finally, 11 eyes of were evaluated. The study included 11 eyes of seven patients with progressive keratoconus. The mean age was 24.45 \pm 4.27 (20–32) years, and 5 (45.4%) of the patients were female and 6 (54.5%) of the patients were male. Table 1 reveals the tear osmolarity, T-BUT, Schirmer's score, OSDI score, and Oxford grading score at baseline, 1st month, and 24 months postoperatively.

Table 1. Mean values of test results and pre-operative to post-operative comparisons

Ocular surface parameters	Pre-operative (V1) (n: 24)	1-month (V2) (n: 24)	24-month (V3) (n: 11)	P-value		
				V1 versus V2	V1 versus V3	V2 versus V3
OSDI1 (min-max)	2.82±2.82 (0–7)	17.00±17.98 (0–44)	43.09±15.57 (20–66)	0.011	0.001	0.009
Tear Osmolarity (mOsm/L) (min-max)	280.63±8.52 (264–292)	287.90±8.90 (276–302)	297.72±10.70 (278–314)	0.001	0.001	0.001
T-BUT2 (sec) (min-max)	10.27±2.72 (7–14)	15.00±3.87 (10–20)	13.55±8.21 (5–26)	0.001	0.256	0.625
Oxford Grading Score (min-max)	0	0.27±0.46 (0–1)	0.55±0.68 (0–2)	0.082	0.025	0.277
Schirmer's I test (mm) (min-max)	9.73±3.49 (5–14)	15.00±6.97 (6–24)	9.64±5.71 (4–22)	0.001	0.963	0.063
NEI-VFQ25 ³			71.27±19.73			

1OSDI: Ocular Surface Disease Index Questionnaire, 2T-BUT: tear film break-up time, 3NEI-VFQ25: The National Eye Institute Visual Function Questionnaire, P-value: Statistically significant ratio, Mean values of test results and P values for comparison of pre-operative and post-operative results at each time point. Data were compared by means of a paired-samples t-test.

A significant progressive increase was detected in OSDI and tear osmolarity at the post-operative 1st month and 24th months compared to pretreatment ($p=0.009$ for OSDI, and $p=0.001$ for tear osmolarity) (Figs. 1 and 2). Despite the fact that T-BUT increased progressively during follow-up, it was only significant between pre-operative and 1-month post-operative values ($p=0.001$) (Fig. 3). Similar to T-BUT, Oxford grading score increased progressively but it was only significant between pre-operative and 24 months ($p=0.025$) (Fig. 4). The Schirmer I test increased in 1st month compared with pre-operative values, although it has the lowest value in 24 month during follow-up period (Fig. 5).

Discussion

Corneal collagen crosslinking is the unique treatment option for preventing progression, and also to block the pathophysiology in keratoconus and post-refractive surgery corneal ectasia. It also reduces the requirement for keratoplasty. Besides the advantages, CXL has an effect on initiating the alterations on the ocular surface. In addition to optical aberrations and refractive errors, tear film dysfunction leads to impaired visual acuity in keratoconus patients who are relatively younger ages at the time of diagnosis, and have longer life expectancy.^[8] In this report, we investigated the effect of CXL on ocular surface and tear function parameters. We declared that CXL may lead to oc-

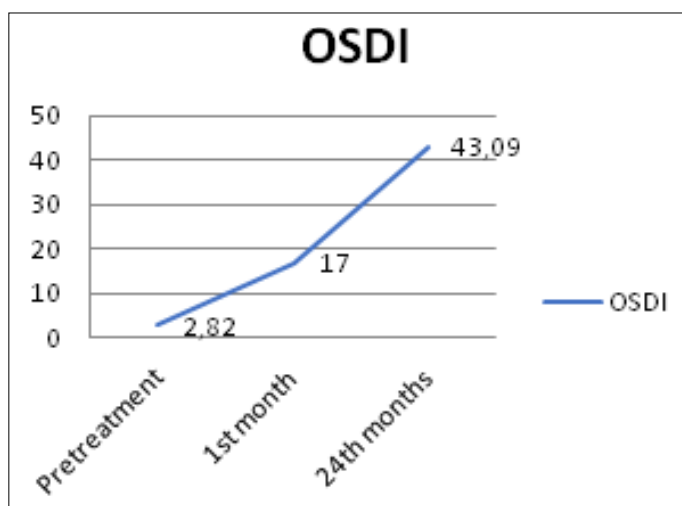


Fig. 1. Ocular surface disease index alterations in keratoconus patients at preoperatively, 1st month, and 24 months after corneal collagen cross-linking.

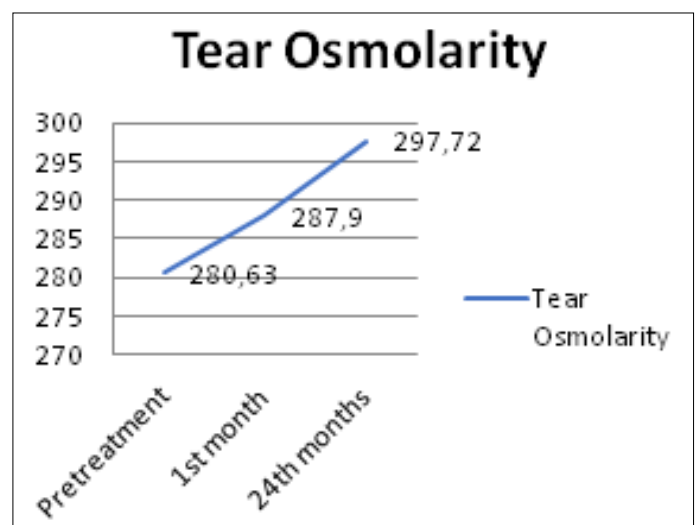


Fig. 2. Tear osmolarity alterations in keratoconus patients at preoperatively, 1st month, and 24 months after corneal collagen cross-linking.

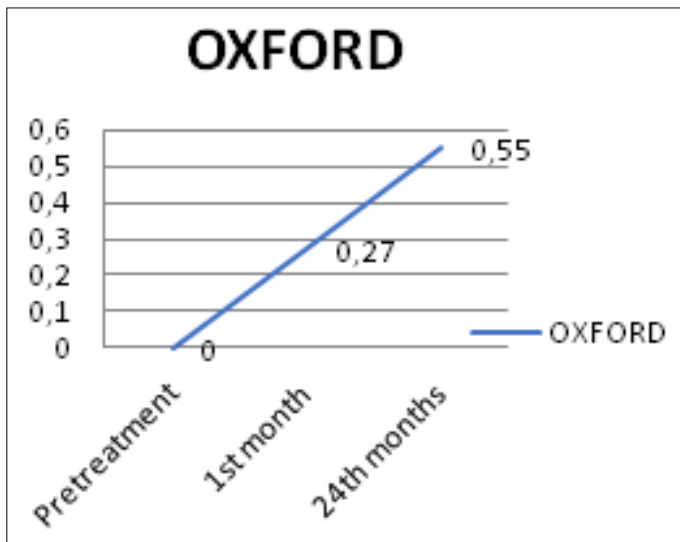


Fig. 3. Tear break-up time alterations in keratoconus patients at preoperatively, 1st month, and 24 months after corneal collagen cross-linking.

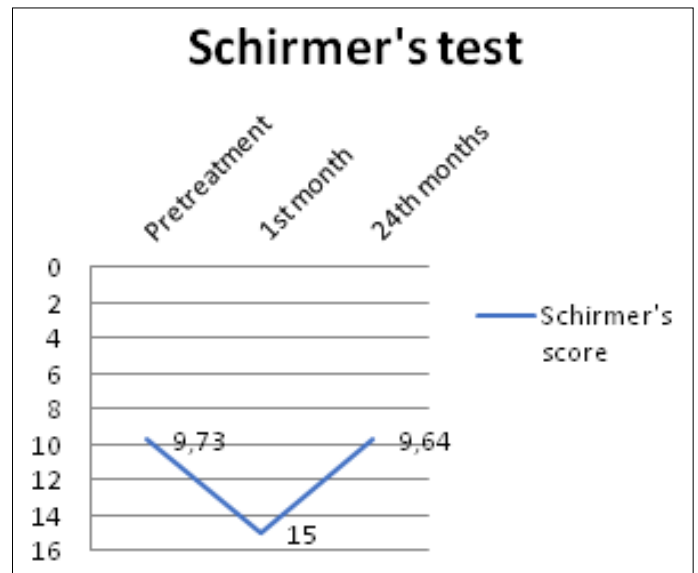


Fig. 5. Schirmer's score alterations in keratoconus patients at preoperatively, 1st month, and 24 months after corneal collagen cross-linking.

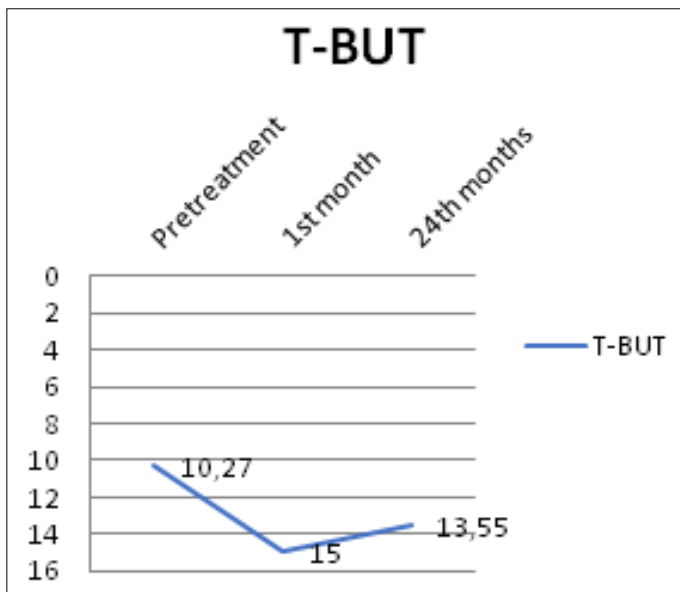


Fig. 4. Oxford grading score alterations in keratoconus patients at preoperatively, 1st month, and 24 months after corneal collagen cross-linking.

ular surface disturbance by evaluating OSDI, tear osmolarity, T-BUT, Oxford grading score, and Schirmer's score at 1st and 24th months. We observed that CXL has negative effects on tear function and concluded that if we performed CXL for progression, we should follow patients for ocular surface disorders as well as topographic progression for a long time. Because the side effects of CXL on ocular surface may last up to 24 months.

OSDI score was significantly higher in 1st month and 24th month follow-up. We believe that increased OSDI strongly implies ocular surface disease after CXL. OSDI also remains

the ability to continue daily activities and the perception of the individual's health related to dry eye. Several studies declared that there was no significant difference in the levels of OSDI scoring but none of these publications had a long follow-up period of 2 years.^[9-12]

In this study, we evaluated tear osmolarity, which is a quantitative method for diagnosis and classification of dry eye.^[13] We observed that the tear osmolarity increased gradually similar to OSDI after CXL. Tear osmolarity has been a gold standard method to diagnose tear concentration with high sensitivity and specificity. In keratoconus patients, the alterations in components and concentration of tear proteins may be observed after CXL. Recalde et al. resulted positive correlation between tear osmolarity and tear proteins that may be related to increased oxidative stress, apoptosis, and inflammation of the ocular surface.^[9] Some authors have not found a change in the tear osmolarity after CXL with Dresden protocol^[14,15] while some of them have performed accelerated CXL (A-CXL).^[10,12] Current studies that have been processed with the Dresden protocol similar to our study have not accessed out follow-up period or those that have reached our follow-up period have not performed osmolarity. In studies, the A-CXL method is preferred; the monitoring period is different in each case: 3, 6, 12, 18, and 24 months. However, a similar follow-up period is considered only in the study of Kontadakis et al., they have performed tear function parameters except for the tear osmolarity. The significant differences in the tear osmolarity may be related to different CXL methods and A-CXL may be superior to Dresden protocol for tear film func-

tion. Furthermore, comparative studies with both methods should be held with a long monitoring period including the evaluation of tear film parameters.

Similar to OSDI and the tear osmolarity, Oxford staining score rised progressively in favor of dry eye but the difference was statistically significant only in 24th months when compared with pretreatment values. Several reports resulted a significant change in Oxford stating score, although Recalde et al. observed a significantly positive correlation between tear S100A6 levels and ocular surface staining scores which indicates the damage to the ocular surface at 6 and 12 months after the procedure. They have proposed that S100A6 is an indicator of cellular apoptosis. If S100A6 concentration is reduced in tear, corneal staining diminishes indicating less ocular surface injury.^[9]

The musin is an essential constituent of the mucin layer which stabilizes tear film and moistens the ocular surface.^[16] Tear mucin is mostly produced by conjunctival goblet cells, also by non-goblet conjunctival epithelial cells, and the corneal epithelium.^[17] The quality of mucin is described as T-BUT clinically. In untreated keratoconus patients, T-BUT values were found significantly lower compared with healthy subjects.^[3] In this report, we resulted an improvement in T-BUT in the 1st month but there was no change in 24 month. Increased T-BUT in the 1st month may be associated with a post-operative treatment scheme including non-preservative artificial tears throughout 1 month, 4 times a day.

Alterations in T-BUT scores may be related to possible changes in the quality and/or quantity of mucin secretion by the injured corneal epithelium, diminished goblet cell, and conjunctival non-goblet epithelial cells.^[17,18] In addition to that, steep corneas may lead to ocular surface disorders related to corneal exposure.^[3] In this study, crosslinking was found to be effective for halting the progression of keratoconus in all patients and none of the corneas showed progressive steepening and thinning after treatment at 24th months. Besides that, Kalkan Akçay et al. proposed that there was no significant change in T-BUT and additionally they evaluated conjunctival goblet cell density. They concluded that there was not any significant correlation between T-BUT values and conjunctival goblet cell density changes after A-CXL. They commented that regenerated corneal epithelium after complete re-epithelialization produces a better quality and quantity of mucin. Through in vivo confocal microscopy, Mazzotta et al. showed that epithelial cell mosaic improved after standard CXL, especially in the apex region, compared with the pre-operative

corneal epithelium.^[19] The evaluation of tear function was also declared unexpected results. In this study, dry eye was not aqueous-deficient. Tear production was also evaluated by the Schirmer I test. No significant difference was obtained during the follow-up. We commented that all subjects were prescribed non-preservant artificial tears and it could have possible improving effects on tear film parameters familiar with T-BUT. Both Schirmer's test and T-BUT reversed to the pretreatment statement at 24th month.

Besides, the remnants of corneal epithelium on the peripheral cornea may compensate for tear secretion, or the same effect may be caused by aberrant activity of amputated corneal nerves.^[20] CXL has been shown to have no effect on tear production in previous studies with different monitoring periods in each case: 1 month–24 months.^[10-12,14] Uysal et al. were not detected a change in the average of Schirmer's score after A-CXL^[11] and Taneri et al. postulated that several dry eye parameters have not been influenced by CXL (according to Dresden protocol) at 3 and 6 months postoperatively.^[14] These findings are similar to our results.

Before performing CXL, we should remember that corneal innervation, sensitivity, and tear function are already abnormal in keratoconic patients.^[3] In keratoconus, ocular surface changes such as decreased corneal sensitivity and T-BUT, and increased ocular surface staining score are obtained by Dogru et al.^[3] In addition to that, they reported that goblet cell loss and conjunctival squamous metaplasia (with impression cytology) may exist in keratoconus and all of these may be related to the keratoconus progression.

Bleshoy declared that the sensitivity in keratoconic corneas is impaired in all zones.^[21] The alterations in corneal innervations of keratoconus patients have been shown in confocal microscopic studies. Compared with controls, the sub-basal nerve was thicker, and more tortuous with lower density.^[22-24] In addition to impaired corneal nerve density in keratoconus, Kontadakis et al. postulated that corneal sensitivity decreased in the post-operative 1st month and restored to pre-operative levels at post-operative 9 months after CXL.^[15] In confocal microscopic studies, Kymionis et al. showed that the corneal reinnervation initiates about the 3rd month after CXL but did not restore to pre-operative density.^[25] Xia et al. declared that corneal nerves showed improvement at post-treatment 90 days and corneal nerve fiber density completely recovered after 180 days in rabbits.^[26] Similarly, the previous studies reported more rapid regeneration of subepithelial nerve fibers. Mazzotta et al. reported that recovery initiates in 1st month and is completed 6 months after procedure. However, corneal nerve

formation does not still return to pre-operative form at 2 years. These studies may explain our results which show the tendency toward dry eye at 24 months.^[19] In regard to these studies, it could be claimed that CXL may lead to noteworthy transient hypoesthesia due to transient denervation.^[15] It has been reported that keratocytes and the subepithelial nerve plexus regenerate in about 6 months although we observed the long-term effects on the ocular surface in 2nd year.

In the short follow-up period, the toxicity due to topical drugs, mechanical injury through lid speculum, and inflammation may likely cause ocular surface disorders. Furthermore, there are several hypotheses that explain these results. Kalkan Akçay et al. have found alterations in the conjunctival impression cytology after CXL and described them as the toxicity of UV-A radiation.^[10] The corneal limbal region is the main source of epithelial stem cells that have a significant role in providing ocular surface stability. Although limbal area is protected from intentional radiation directly during the procedure, scattered UV-A light or inadvertent irradiation on limbal epithelial cells affects ocular surface after treatment. Beyond that, the adverse effect of collagen fragments and degradation products of corneal epithelium (released into tears) may be hazardous to tear film stability. In addition to that, there is irregular distribution of tear film on the cornea and ocular surface because of the corneal ectasia.^[27,28]

The pathogenetic mechanism of keratoconus and other ectatic corneal disease is commonly mentioned as the release of inflammatory mediators due to eye rubbing which leads to changes in corneal collagen and progresses ectasia. A positive correlation between keratoconus and systemic or ocular allergic disorders has been mentioned. The major limitation of this study is the small sample size. Unfortunately, few patients completed the 24-month follow-up period. Another limitation of our study is not to evaluate the allergic status of patients and we could not obtain adequate data about allergic pathologies. Both systemic and ocular allergies and anti-allergic treatment have an effect on the ocular surface and may generate dry eye symptoms. For this reason, comorbidities should be remembered in a long follow-up period. Contact lens use also affects corneal sensitivity.^[29] None of our patients have a soft or rigid gas-permeable contact lens history. This minimizes the effect of lenses on measurements and all of them have been prescribed only glasses after treatment. In addition, we could not reach the data about the patient's corneal topography data, visual acuity, and other treatment modalities; they received before CXL. For this reason, we could not conclude about it.

Conclusion

Our data showed that CXL may lead to dry eye disorder which is a significant complication of the procedure. After CXL, we should follow patients for ocular surface disorders as well as topographic progression for a long time because the side effects of CXL on the ocular surface may last up to 24 months. As a result, the iatrogenic dry eye seems to be a considerable complication after CXL.

Ethics Committee Approval: This study was approved by Balıkesir University Faculty of Medicine Ethics Committee (10.02.2021 and 2021/43).

Peer-review: Externally peer-reviewed.

Authorship Contributions: Concept: E.S.S., A.Y., C.G.; Design: E.S.S., A.Y.; Supervision: E.S.S., A.Y., C.G.; Resource: G.S.V.; Materials: G.S.V., E.S.S.; Data Collection and/or Processing: G.S.V.; Analysis and/or Interpretation: G.S.V.; Literature Search: G.S.V.; Writing: G.S.V.; Critical Reviews – E.S.S., A.Y., C.G.

Conflict of Interest: None declared.

Use of AI for Writing Assistance: Not declared.

Financial Disclosure: The authors declared that this study received no financial support.

References

- Davidson AE, Hayes S, Hardcastle AJ, Tuft SJ. The pathogenesis of keratoconus. *Eye (Lond)* 2014;28:189–95. [\[CrossRef\]](#)
- Touboul D, Efron N, Smadja D, Praud D, Malet F, Colin J. Corneal confocal microscopy following conventional, transepithelial, and accelerated corneal collagen cross-linking procedures for keratoconus. *J Refract Surg* 2012;28:769–75. [\[CrossRef\]](#)
- Dogru M, Karakaya H, Özçetin H, Ertürk H, Yücel A, Özmen A, et al. Tear function and ocular surface changes in keratoconus. *Ophthalmology* 2003;110:1110–8. [\[CrossRef\]](#)
- Rieger G. The importance of the precorneal tear film for the quality of optical imaging. *Br J Ophthalmol* 1992;76:157–8.
- Goto E, Yagi Y, Matsumoto Y, Tsubota K. Impaired functional visual acuity of dry eye patients. *Am J Ophthalmol* 2002;133:181–6. [\[CrossRef\]](#)
- Jiang X, Liu X, Liu X, Wu X, Jose PA, Liu M, et al. Low-dose aspirin treatment attenuates male rat salt-sensitive hypertension via platelet cyclooxygenase 1 and complement cascade pathway. *J Am Heart Assoc* 2020;9:e013470. [\[CrossRef\]](#)
- Alió JL, Shabayek MH. Corneal higher order aberrations: A method to grade keratoconus. *J Refract Surg* 2006;22:539–45.
- Godefrooij DA, de Wit GA, Uiterwaal CS, Imhof SM, Wisse RP. Age-specific incidence and prevalence of keratoconus: A nationwide registration study. *Am J Ophthalmol* 2017;175:169–72. [\[CrossRef\]](#)
- Recalde JI, Duran JA, Rodriguez-Agirretxe I, Soria J, Sanchez-Tena MA, Pereiro X, et al. Changes in tear biomarker levels in keratoconus after corneal collagen crosslinking. *Mol Vis*

- 2019;25:12–21.
10. Kalkan Akçay E, Kilicarslan A, Uysal BS, Hondur G, Kosekahya P, Altinkaynak H, et al. Tear function and ocular surface alterations after accelerated corneal collagen cross-linking in progressive keratoconus. *Eye Contact Lens* 2017;43:302–7. [\[CrossRef\]](#)
 11. Uysal BS, Akcay E, Kilicarslan A, Mutlu M, Hondur G, Kosekahya P, et al. Tear function and ocular surface changes following corneal collagen cross-linking treatment in keratoconus patients: 18-month results. *Int Ophthalmol* 2020;40:169–77.
 12. Recalde JI, Acera A, Rodríguez-Agirretxe I, Sánchez-Tena MA, San-Cristóbal J, Durán JA. Ocular surface disease parameters after collagen cross-linking for keratoconus. *Cornea* 2017;36:148–52. [\[CrossRef\]](#)
 13. Irkec MT, Turkish OSDI Study Group. Reliability and validity of Turkish translation of the ocular surface disease index (OSDI) in dry eye syndrome. *Invest Ophthalmol Vis Sci* 2007;48:408.
 14. Taneri S, Oehler S, Asimellis G, Kanellopoulos AJ. Influence of corneal cross-linking for keratoconus on several objective parameters of dry eye. *J Refract Surg* 2013;29:612–6. [\[CrossRef\]](#)
 15. Kontadakis GA, Kymionis GD, Kankariya VP, Pallikaris AI. Effect of corneal collagen cross-linking on corneal innervation, corneal sensitivity, and tear function of patients with keratoconus. *Ophthalmology* 2013;120:917–22. [\[CrossRef\]](#)
 16. Jumblatt MM, McKenzie RW, Jumblatt JE. MUC5AC mucin is a component of the human precorneal tear film. *Invest Ophthalmol Vis Sci* 1999;40:43–9.
 17. Watanabe H. Significance of mucin on the ocular surface. *Cornea* 2002;21:S17–22. [\[CrossRef\]](#)
 18. Kinoshita S, Kiorpes TC, Friend J, Thoft RA. Goblet cell density in ocular surface disease. A better indicator than tear mucin. *Arch Ophthalmol* 1983;101:1284–7. [\[CrossRef\]](#)
 19. Mazzotta C, Traversi C, Baiocchi S, Caporossi O, Bovone C, Sparano MC, et al. Corneal healing after riboflavin ultraviolet-a collagen cross-linking determined by confocal laser scanning microscopy in vivo: Early and late modifications. *Am J Ophthalmol* 2008;146:527–34. [\[CrossRef\]](#)
 20. Belmonte C. Eye dryness sensations after refractive surgery: Impaired tear secretion or “phantom” cornea? *J Refract Surg* 2007;23:598–602. [\[CrossRef\]](#)
 21. Bleshoy H. Corneal sensitivity in keratoconus. *J Br Contact Lens Assoc* 1986;9:9–12. [\[CrossRef\]](#)
 22. Teng CC. Electron microscope study of the pathology of keratoconus: I. *Am J Ophthalmol* 1963;55:18–47. [\[CrossRef\]](#)
 23. Niederer RL, Perumal D, Sherwin T, McGhee CN. Laser scanning in vivo confocal microscopy reveals reduced innervation and reduction in cell density in all layers of the keratoconic cornea. *Invest Ophthalmol Vis Sci* 2008;49:2964–70. [\[CrossRef\]](#)
 24. Mocan MC, Yilmaz PT, Irkec M, Orhan M. In vivo confocal microscopy for the evaluation of corneal microstructure in keratoconus. *Curr Eye Res* 2008;33:933–9. [\[CrossRef\]](#)
 25. Kymionis GD, Diakonis VF, Kalyvianaki M, Portaliou D, Siganos C, Kozobolis VP, et al. One-year follow-up of corneal confocal microscopy after corneal cross-linking in patients with post laser in situ keratosmiles ectasia and keratoconus. *Am J Ophthalmol* 2009;147:774–8, 778.e1. [\[CrossRef\]](#)
 26. Xia Y, Chai X, Zhou C, Ren Q. Corneal nerve morphology and sensitivity changes after ultraviolet a/riboflavin treatment. *Exp Eye Res* 2011;93:541–7. [\[CrossRef\]](#)
 27. Reinstein DZ, Gobbe M, Archer TJ, Silverman RH, Coleman DJ. Epithelial, stromal, and total corneal thickness in keratoconus: Three-dimensional display with artemis very-high frequency digital ultrasound. *J Refract Surg* 2010;26:259–71. [\[CrossRef\]](#)
 28. Meek KM, Tuft SJ, Huang Y, Gill PS, Hayes S, Newton RH, et al. Changes in collagen orientation and distribution in keratoconus corneas. *Invest Ophthalmol Vis Sci* 2005;46:1948–56.
 29. Martin XY, Safran AB. Corneal hypoesthesia. *Surv Ophthalmol* 1988;33:28–40. [\[CrossRef\]](#)