



## LETTER TO THE EDITOR

## The effectiveness of high dose steroid in post-corona severe headache

*Koronavirüs hastalığı sonrası şiddetli baş ağrısında yüksek doz steroidin etkinliği*

Nermin TEPE,<sup>1</sup> Oktay Faysal TERTEMİZ<sup>2</sup>

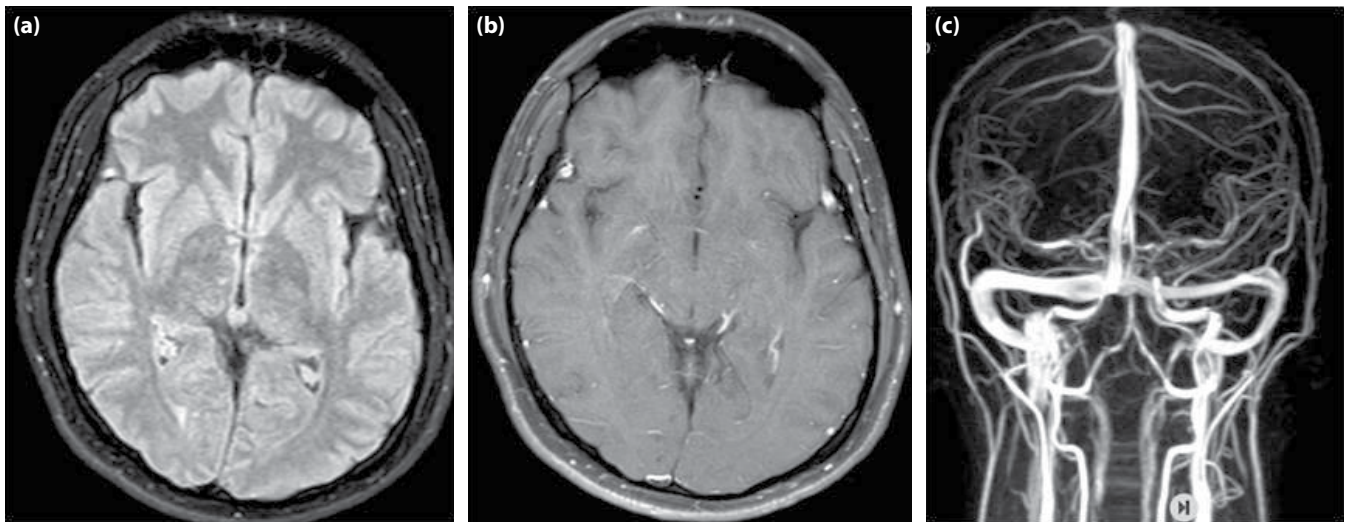
To the Editor,

The coronavirus disease (COVID-19), which made a pandemic in the world in 2019, causes various organ pathologies during and after the disease process.

With neurological involvement, the central nervous system (dizziness, headache, cerebrovascular disease, seizure, impaired consciousness) and peripheral nervous system (anosmia, neuropathic pain, Guillain-Barre syndrome and its variants) can be affected.<sup>[1]</sup>

We wanted to share our patient, who had no previous history of headaches and developed a headache 2 months after being positive for COVID-19 PCR and was resistant to medical treatment.

A 28-year-old male health-care worker had a positive PCR test on a nasal swab made for screening purposes. Favipiravir was started and isolated at home. 2 months later, a severe, throbbing headache started from the back of the head and spread to the forehead, with nausea, vomiting, and sensitivity to light and sound. He was unresponsive to nonsteroidal and opioid-derived analgesics. A COVID-19 PCR repeated twice was found to be negative. The patient with no pathology in the brain and chest tomography was evaluated in our outpatient clinic. Contrast-enhanced brain MRI and venography were not detected in the pathology (Fig. 1). Body temperature, blood poisoning, lightning saturation, and pulse rate were not detected. Lymphopenia, AST-ALT, sedimentation, and CRP levels were increased (Table 1).



**Figure 1.** (a) non-contrast normal brain MR axial section; (b) contrast-enhanced normal brain MR axial section; (c) normal brain MR venography.

<sup>1</sup>Department of Neurology, Balıkesir University Faculty of Medicine, Balıkesir, Türkiye

<sup>2</sup>Department of Algology, İzmir University of Health Sciences Tepecik Training and Research Hospital, İzmir, Türkiye

Submitted (Başvuru) 07.03.2022 Revised (Revizyon) 21.04.2022 Accepted (Kabul) 27.04.2022 Available online (Online yayımlanma) 13.10.2023

**Correspondence:** Dr. Nermin Tepe. Balıkesir Üniversitesi, Nöroloji Anabilim Dalı, İstanbul, Türkiye.

**Phone:** +90 - 505 - 757 43 59 **e-mail:** tepenermin@gmail.com

© 2023 Turkish Society of Algology

**Table 1.** Blood test results

	Basal	1 <sup>st</sup> week after steroid	1 <sup>st</sup> month after steroid
WBC	3.7×10 <sup>3</sup> /μL	7.1×10 <sup>3</sup> /μL	5.9×10 <sup>3</sup> /μL
Absolute lymphocyte	0.5×10 <sup>3</sup> /μL	2.2×10 <sup>3</sup> /μL	2×10 <sup>3</sup> /μL
CRP	53 mg/L	<2.98 mg/L	<3 mg/L
Sedimentation	44 mm/st	–	14 mm/st
ALT	83 IU/L	66 IU/L	23 IU/L
AST	64 IU/L	23 IU/L	26 IU/L

WBC: White blood cell; CRP: C-reactive protein; ALT: Alanine aminotransferase; AST: Aspartate aminotransferase.

TORCH panel, EBV and VDRL IgM, brucella, HIV, Hb-sAg, and HCV RNA were negative. No pathology was detected in CSF pressure or biochemistry; a total of 20 leukocytes were detected in the microbiological examination. No pathology was detected in CSF brucella (-), HSV1-2 IgM (-), or culture. With the preliminary diagnosis of encephalitis empirically, acyclovir 2\*1 g/day (IV) + moxifloxacin 1\*400 mg/day (IV) were started. After 72 hours, the patient's headache did not change. Methylprednisolone 250 mg/day (IV) was started. The NRS (numerical ratio scale) decreased from 10 to 8 on the 1<sup>st</sup> day, and there was no change in nausea and vomiting. The treatment was continued, NRS decreased to 4–5 on the 2<sup>nd</sup> day, and nausea and vomiting disappeared. Since there was no headache on the 3<sup>rd</sup> day, steroid treatment was not continued on the 4<sup>th</sup> day. He had two headache attacks within a week, which resolved in half an hour without the use of analgesics, and the NRS was 3. Improvement was also observed in the deteriorated laboratory parameters (Table 1). There was no headache at the follow-up 2 months later.

It is known that the SARS-CoV-2 virus, which affected the whole world in 2020, causes various peripheral and central nervous system signs and symptoms. It has been reported that late-stage findings (myalgia, fatigue, hot flushes, shortness of breath, chest tightness, tachycardia, headache, and anxiety) may be due to organ damage or a persistent hyperinflammatory process in the acute infection stage.<sup>[2]</sup>

In a study conducted in our country, headaches reported in 11–34% of hospitalized COVID-19 patients. Headache features were reported as new-onset, moderate severe, bilateral temporoparietal, throbbing or pressing in the forehead or periorbital region, and poor response to analgesics. The possible

pathophysiological mechanisms of headache include activation of peripheral trigeminal nerve endings by SARS-CoV-2 directly or through vasculopathy and/or increased circulating pro-inflammatory cytokines and hypoxia.<sup>[3]</sup> However, in the literature, as in our case, it was asymptomatic during the COVID-19 process, and headache resistance to acute analgesics in the late period was not reported. We think that severe headaches that did not respond to analgesics developed in our patient, who, as a health professional, was exposed to a high viral load. While it is a disadvantage for us not to have performed a viral analysis in CSF, PCR testing of CSF may not always produce a response. Although there have been cases that had a final diagnosis with a tissue biopsy, this may not always prove sufficient.<sup>[4]</sup>

Dexamethasone 6 mg/d is recommended in serious and critical COVID-19 treatment; the efficacy of pulse steroid treatment has been evaluated in some studies. In a randomized, controlled study, methylprednisolone was administered at a dose of 250 mg/d for 3 days and compared with test subjects who received standard care. Clinical recovery was found to be 94.1% in the steroid-receiving group and 57.1% in the other group.<sup>[5]</sup> In our patient, when she was unresponsive to analgesics and opioids, we tried steroid treatment for migrainous headaches as in status migrainous. Our response supports the improvement of the headache due to the suppression of the cytokine storm that may occur in COVID with high-dose steroids.

We wanted to share this case because it is an example showing that acute headaches may develop in the late post-corona period, may be severely migrainous, and may not respond to analgesics, and that short-term and high-dose steroid treatment can be given as an alternative treatment.

## References

1. Mao L, Jin H, Wang M, Hu Y, Chen S, He Q, et al. Neurologic manifestations of hospitalized patients with coronavirus disease 2019 in Wuhan, China. *JAMA Neurol* 2020;77:683–90.
2. Yende S, Kellum JA, Talisa VB, Peck Palmer OM, Chang CH, Filbin MR, et al. Long-term host immune response trajectories among hospitalized patients with sepsis. *JAMA Netw Open* 2019;2:e198686. [\[CrossRef\]](#)
3. Bolay H, Gül A, Baykan B. COVID-19 is a real headache! *Headache* 2020;60:1415–21. [\[CrossRef\]](#)
4. Paniz-Mondolfi A, Bryce C, Grimes Z, Gordon RE, Reidy J, Lednicky J, et al. Central nervous system involvement by severe acute respiratory syndrome coronavirus-2 (SARS-CoV-2). *J Med Virol* 2020;92:699–702. [\[CrossRef\]](#)
5. Edalatifard M, Akhtari M, Salehi M, Naderi Z, Jamshidi A, Mostafaei S, et al. Intravenous methylprednisolone pulse as a treatment for hospitalised severe COVID-19 patients: Results from a randomised controlled clinical trial. *Eur Respir J* 2020;56:2002808. [\[CrossRef\]](#)