



A Comparative Evaluation of Globe Trauma Features in a Tertiary Care Hospital Before and During the COVID-19 Pandemic

© Gözde Şahin Vural, © Semih Yılmaz, © Eyyüp Karahan, © Cenap Güler

Balıkesir University Faculty of Medicine, Department of Ophthalmology, Balıkesir, Turkey

Abstract

Objectives: To compare the clinical features, preoperative evaluation, and surgical approaches of globe trauma patients presenting to the emergency department before and during the coronavirus disease 2019 (COVID-19) pandemic.

Materials and Methods: We retrospectively analyzed 54 eyes of 54 patients with traumatic globe perforation who underwent primary globe repair. The patients were divided into two groups according to the official start of the COVID-19 pandemic in Turkey: Group 1, 1 May 2019-11 March 2020 and Group 2, 11 March 2020-1 January 2021. The demographic features, trauma history, time from trauma to admission and from admission to surgery, COVID-19 serology (polymerase chain reaction [PCR]) result, ophthalmological examination findings at admission, surgical interventions, and postoperative clinical features were obtained from the patients' records.

Results: The mean ages of the patients in Group 1 (n=21) and Group 2 (n=33) were 42.76±20.72 and 37.78±23.47 years, respectively (p=0.431). During the pandemic, garden/farm injuries increased while workplace injuries decreased. In Groups 1 and 2 respectively, time from trauma to admission was 461.4±1228.6 and 935.4±2039.6 min (p=0.342), time from admission to surgery was 604.2±679.8 and 392.7±306.9 min (p=0.125), and length of hospital stay was 7.23±4.96, and 3.78±2.28 days (p<0.005). All patients had a COVID-19 PCR test and all resulted negative. There was no significant difference between the groups in terms of the clinical features of the ocular and adnexal injuries, surgical interventions, or postoperative complications (p>0.05). Preoperative visual acuity was found to be an important prognostic factor associated with postoperative visual acuity.

Conclusion: Globe injuries require urgent intervention in terms of visual morbidity. Patterns of injury differ during the pandemic due to both restrictions and lifestyle changes. During the pandemic, patients were discharged as soon as possible after emergency treatment to minimize the time spent in the hospital.

Keywords: COVID-19, globe trauma, pandemic

Address for Correspondence: Gözde Şahin Vural, Balıkesir University Faculty of Medicine, Department of Ophthalmology, Balıkesir, Turkey

E-mail: gozdejcgri@hotmail.com **ORCID-ID:** orcid.org/0000-0002-6989-4378

Received: 28.07.2021 **Accepted:** 22.01.2022

Cite this article as: Şahin Vural G, Yılmaz S, Karahan E, Güler C. A Comparative Evaluation of Globe Trauma Features in a Tertiary Care Hospital Before and During the COVID-19 Pandemic. Turk J Ophthalmol 2022;52:102-108

© Copyright 2022 by Turkish Ophthalmological Association
Turkish Journal of Ophthalmology, published by Galenos Publishing House.

Introduction

The clinical entity characterized by severe lower respiratory tract infections of unknown cause that first appeared in the Wuhan province of the People's Republic of China in 2019 has affected the whole world. The World Health Organization named it coronavirus disease 2019 (COVID-19) and declared it a pandemic on 11 March 2020. Cases were also detected in Turkey and it spread rapidly through society. In response, the Turkish Ministry of Health decided in March 2020 to continue only emergency and oncological surgery and suspend all elective procedures.¹ During this period, the Turkish Ophthalmological Association published a list of which emergency surgeries and interventions can be performed, and globe injuries were the leading condition requiring urgent intervention according to this recommendation.² Globe traumas are common in developing countries and are important because they lead to vision loss and a subsequent decline in quality of life.^{3,4} In contrast to vision-impairing pathologies that are more common in advanced age, such as cataract, glaucoma, and age-related macular degeneration, globe trauma affects the younger population and leads to greater labor loss.

As in many countries, in Turkey it was recommended to stay at home as much as possible and leave only for essential reasons due to the COVID-19 pandemic. This led to many changes in work and social routines across the entire population. During the pandemic, there have also been changes in patterns of ocular injury in connection with the changes in people's social life and in the organization of the health system. Differences have emerged in the types of globe injuries, length of hospital stay, surgical decisions, preoperative COVID-19 serological evaluation, preparation for surgery, and the precautions taken during and after surgery. In addition to being a tertiary health care hospital, our center is also a pandemic hospital, so attempts were made to treat emergency globe traumas while implementing the appropriate precautions and protective methods during this period. The aim of this study was to retrospectively examine parameters such as injury type, preoperative characteristics, anesthesia methods, and surgical techniques in cases of globe trauma treated in our tertiary care hospital by emergency surgery before and during the pandemic.

Materials and Methods

Patients who were referred to the Department of Ophthalmology in Balıkesir University Faculty of Medicine between May 2019 and January 2021 due to emergency eye trauma and underwent emergency primary globe repair were included in the study. Approval for the study was obtained from Balıkesir University Clinical Research Ethics Committee (decision number: 2021/122) and the Turkish Ministry of Health (registration number: T00-18-07). Patients without appropriate preoperative or postoperative follow-up were excluded. Study data were obtained retrospectively from patient records. The patients were divided into two groups, those who presented before the pandemic (Group 1) and during the pandemic (Group 2), based

on the date of 11 March 2020, when pandemic restrictions began in Turkey. The patients' demographic characteristics (age, gender), initial ophthalmological examination findings, trauma history, time from trauma to hospital admission, and time from admission to surgical intervention were recorded. Visual acuity, intraocular pressure, side of trauma, ocular history, and Ocular Trauma Score (OTS) recorded during detailed eye examination were analyzed.⁵ In addition, operation time, type of anesthesia (local or general anesthesia), serological tests (hepatitis B virus, hepatitis C virus, and human immunodeficiency virus), American Society of Anesthesiologists physical status classification, and COVID-19 real-time polymerase chain reaction (PCR) test result were recorded. The anatomic location of the trauma (skin, cornea, limbus, conjunctiva, sclera, lens), presence of tissue loss, orbital fracture (confirmed by computed tomography), intraocular or intraorbital foreign body, chemosis, proptosis, prolapse of ocular tissues (iris, choroid, vitreous, lens, intraocular lens), vitreous hemorrhage, and the type of trauma according to Birmingham Eye Trauma Terminology System (BETTS) were recorded.⁶ Among the procedures performed during surgery, canthotomy, exploration with 360-degree limbal peritomy, surgical interventions to the periorbital muscles, anterior chamber lavage, conjunctival autografting to the corneal/limbal area, intracameral antibiotic administration at the end of surgery, and temporary tarsorrhaphy were examined. The patients' total length of hospital stay was recorded. Visual acuity at postoperative 1 week was accepted as postoperative vision. Lens extraction pars plana vitrectomy, penetrating keratoplasty, and evisceration performed in a different session in the late postoperative period were noted. The patients' total follow-up time was evaluated.

Statistical Analysis

The data were analyzed using SPSS version 23.0 software (IBM Corp, Armonk, NY, USA). Chi-square analysis was used for the age and gender distributions of the groups. Independent-samples t-test was used to compare quantitative values between the groups. Pearson's correlation analysis was used to evaluate correlations between the data. Results with p values less than 0.05 were considered statistically significant.

Results

Fifty-four eyes of 54 patients who met the inclusion criteria were evaluated in this study. There were 21 patients in the pre-pandemic group (Group 1) and 33 patients in the post-pandemic group (Group 2). Both periods covered approximately 10.5 months (Group 1: 1 May 2019-11 March 2020; Group 2: 11 March 2020-1 January 2021). The mean age was 42.76 ± 20.72 years in Group 1 and 37.78 ± 23.47 years in Group 2 ($p=0.431$). The female:male ratio was 0.16 (3:18) in Group 1 and 0.22 (6:27) in Group 2 ($p=0.708$). The right:left eye ratio was 2.00 (14:7) in Group 1 and 1.53 (20:13) in Group 2 ($p=0.653$).

Characteristics pertaining to the etiology of globe traumas are shown in Figure 1. In Group 1, home accidents occurred due to falls in 3 patients (14.2%) and sharp objects in 4 patients

(19.0%) (knives in 2 cases, scissors in 1 case, and a paper clip in 1 case). In Group 2, home accidents were related to sharp objects in 9 patients (27.2%) (scissors in 3 cases, exploded glass bottles in 3 cases, a knife in 1 case, a paper clip in 1 case, and broken spectacle glass in 1 patient) and falls in 3 patients (9.0%). According to BETTS, there were 18 open-globe injuries (85.7%), 2 ruptures (9.5%), and 1 penetrating injury (4.7%) in Group 1, while in Group 2 there were 27 open-globe injuries (81.8%), 1 rupture (3.0%), 2 penetrating injuries (6.0%), and 3 perforating injuries (9.0%). There was no significant difference between the groups in terms of injury types (p=0.400). All patients with globe injuries in the pre-pandemic period were operated under general anesthesia (100%), while 93.9% (n=31) of post-pandemic

patients were operated under general anesthesia and 6.1% (n=2) were operated under local anesthesia (p=0.250). COVID-19 PCR test was performed on all 33 patients operated during the pandemic, with results obtained preoperatively in 21 of these patients (63.6%) and postoperatively in 12 patients (36.3%). None of the patients' COVID-19 PCR tests resulted positive. Two of the patients in Group 2 (6.06%) had a previous history of ocular surgery, while there was no history of ocular surgery in Group 1 (Table 1). In terms of preoperative and intraoperative clinical characteristics, there were no significant differences in findings or surgical interventions between globe injuries before and during the pandemic (Table 2). There was a significant correlation between preoperative visual acuity and postoperative visual acuity (p=0.04, R=0.733). The time from emergency admission to surgery was not associated with postoperative visual acuity (p=0.879).

Discussion

The COVID-19 pandemic brought about dramatic changes in both social and working life all over the world. In Turkey, COVID-19 pandemic-related movement restrictions were implemented for all age groups over time, starting with citizens over 65 years of age on March 21, 2020. During this period, people started to spend most of their time at home, in garden areas, and in fields. Workplace restrictions resulted in people spending less time in their work environments. According to this study, there was a 1.5-fold increase in globe traumas, especially those occurring indoors, after the start of the pandemic. In contrast, Pellegrini et al.⁷ suggested that there was

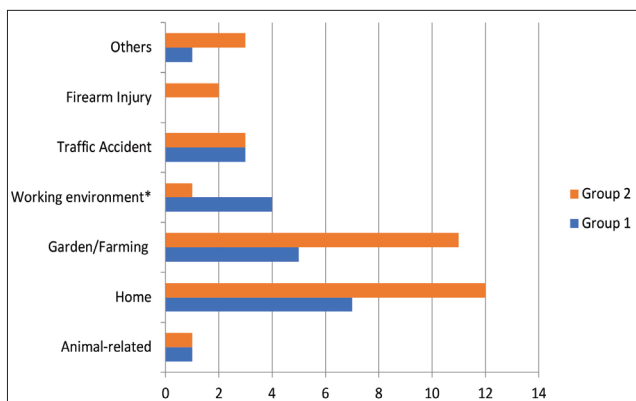


Figure 1. Etiological characteristics of globe traumas before and during the pandemic; *Statistically significant difference (p<0.048)

Table 1. Demographic characteristics and results of preoperative and postoperative evaluations of patients with globe injury before (Group 1) and during (Group 2) the pandemic

	Group 1 (n=21) Mean ± SD	Group 2 (n=21) Mean ± SD	p value
Age (years)	42.76±20.72	37.78±23.47	0.431
Gender, F/M (n)	3/18	6/27	0.708
Ocular surgery history (n)	0	1	0.421
Side, right/left (n)	2/00	1/53	0.653
Preoperative visual acuity (Snellen decimal)	0.06±0.19	0.19±0.38	0.159
Time from trauma to admission (min)	461.42±1228.69	935.45±2039.62	0.342
Time from admission to surgery (min)	604.28±679.83	392.72±306.98	0.125
Anesthesia method, general/local (n)	21/0	31/2	0.250
Preoperative COVID-19 PCR result (%)	-	63.6	
ASA score	1.28±0.46	1.24±0.43	0.729
OTS	41.04±25.04	50.00±26.14	0.218
Operative time (min)	43.28±22.78	40.12±14.16	0.531
Length of hospital stay (days)	7.23±4.96	3.78±2.28	0.001*
Postoperative visual acuity (Snellen decimal)	0.25±0.34	0.33±0.39	0.464
Follow-up time (months)	6.69±6.19	2.54±3.14	0.002*

F: Female, M: Male, PCR: Polymerase chain reaction, ASA: American Society of Anesthesiologists Physical Status Classification, OTS: Ocular Trauma Score, SD: Standard deviation, min: Minute, COVID-19: Coronavirus disease 2019

Table 2. Preoperative clinical findings, intraoperative surgical procedures, and later surgical interventions of patients with globe trauma before (Group 1) and during (Group 2) the pandemic

	Group 1 (n=21)	Group 2 (n=33)	p value
Preoperative evaluation			
Skin	2	4	0.767
Cornea	13	24	0.404
Limbus	7	12	0.820
Conjunctiva	11	19	0.854
Sclera	10	14	0.708
Lens	3	7	0.523
Type of globe trauma*			
Open-globe injury	18	27	
Rupture	2	1	
Penetrating injury	1	2	
Perforating injury	-	3	
Tissue loss	1	5	0.236
Orbital bone fracture	2	1	0.310
Foreign body (intraocular/intraorbital)	1	2	0.839
Intraocular	1	1	
Intraorbital	-	1	
Chemosis	2	3	0.957
Proptosis	1	0	0.206
Ocular tissue prolapse			
Iris	4	4	0.485
Choroid	0	1	0.421
Vitreous	5	2	0.058
Lens	0	1	0.421
Intraocular lens	0	1	0.421
Vitreous hemorrhage	9	7	0.089
Intraoperative procedures			
Canthotomy	1	0	0.206
Exploration with 360-degree limbal peritomy	9	14	0.975
Surgical intervention to the periorbital muscles	3	5	0.930
Anterior chamber lavage	14	17	0.272
Conjunctival autograft to the cornea/limbal area	2	6	0.383
Intracameral vancomycin	1	1	0.743
Temporary tarsorrhaphy	1	0	0.206
Later surgical interventions			
Lens extraction	9	9	0.236
Vitrectomy	7	5	0.117
Penetrating keratoplasty	1	1	0.743
Evisceration	0	1	0.421
*Classified according to Birmingham Eye Trauma Terminology system			

a decrease in globe injuries and that this was associated with behavioral changes during the quarantine period (reduction of sports competitions and related injuries, reduction of childhood globe injuries because of school closures) and patients' reluctance to present to emergency departments due to the risk of COVID-19 transmission. We believe that the increase in the number of cases in the present study is a result of the implementation of flexible working systems in many secondary hospitals and the lack of surgical intervention for globe traumas outside tertiary hospitals. As globe injuries especially affect the young age group,^{8,9} investigating their etiology and taking appropriate preventive measures is as important as appropriate treatment and follow-up. According to the results of this study, the frequency of globe injuries occurring in the home and garden/farm environments and those caused by firearms increased during the pandemic. Similarly, Hamroush et al.¹⁰ found an increase in traumatic ocular injuries at home compared to the corresponding period of the previous year. They showed this was a result of increases in gardening, do-it-yourself activities in the home, and home exercise (jump rope, elastic band injuries). Wu et al.¹¹ also determined that 84% of severe ocular traumas during the pandemic occurred at home. Some studies have demonstrated that the increase in time spent at home during the pandemic were associated with increases in alcohol consumption and subsequent home accidents and firearm injuries.¹² In our study, traumas caused by animals and traffic accidents were found to be stable compared to the pre-pandemic period. Apart from this, there was a decrease in globe traumas occurring in the workplace and working environment, but it was not statistically significant. Globe injuries, especially those accompanied by foreign bodies, are more common among males.^{13,14,15} Consistent with this, 83.3% of the patients in our study were male. The risk of globe injury was five times higher in males than females (odds ratio: 5.0). This result may be attributable to the fact that men more frequently work in jobs with potential exposure to high-energy trauma, participate in contact sports, and engage in activities involving physical contact, such as fighting.

In our study, the time from trauma to hospital admission increased from 461 minutes in the pre-pandemic group to 935 minutes in the post-pandemic group. This may be due to both the delay in patients presenting to the hospital during the pandemic because of concern about infection and the movement restrictions enforced as part of lockdown measures during this period.

During the pandemic, practices such as preoperative COVID-19 PCR testing, minimizing length of hospital stay, and admission to an isolation ward until the results of pre-admission COVID-19 PCR tests are obtained were implemented in our hospital. In addition to the informed consent form for surgical interventions that patients previously signed before elective and emergency operations, consent was also obtained from patients or their relatives using the "Additional Information about the Risks Related to the COVID-19 (Coronavirus) Pandemic and Consent Form" issued by the Turkish Ophthalmological Association.

Although samples for COVID-19 PCR tests were collected and sent for analysis for all patients who presented during the pandemic, surgery was performed after receiving the results in only 63.6% of cases. As trauma patients' PCR results were not known, each patient was considered COVID-19-positive and their operations were performed using all necessary precautions.

There are different opinions in the literature regarding whether to perform emergency or elective surgery on patients with globe trauma.^{16,17,18,19} Endophthalmitis is one of the most important risk factors determining prognosis in globe traumas.²⁰ None of the patients in this study developed endophthalmitis. Essex et al.²¹ showed that the risk of developed endophthalmitis increased by 1.01 fold with each hour after open-globe trauma. They argued that globe traumas should be treated as soon as possible, as the only modifiable factor in open-globe traumas is the time from trauma to surgery. In this study, there was no significant difference in the patients' time from emergency admission to surgery. The first goal in the treatment of globe injuries is to prevent tissue prolapse and ensure globe integrity by primary suturing, and to provide appropriate treatment for possible infections. Since late sequelae are also common in these patients, the change in visual acuity is evaluated secondarily. In our study, there was no difference between the two groups in terms of preoperative or postoperative visual acuity, but postoperative visual acuity was significantly increased in both groups.

Although elective ocular surgeries were restricted worldwide during the pandemic, it is not possible to prevent trauma cases. However, in some eye injuries (e.g., superficial injuries, corneal abrasions, lamellar conjunctival incisions, simple uncomplicated orbital fractures) it is recommended that surgery should not be performed or should be performed as an elective procedure.²² Therefore, determining OTS during preoperative evaluation is crucial to estimate the urgency of surgery and postoperative visual expectation. In our study, we observed no difference in terms of OTS before and during the pandemic, and the mean operative time was similar. During the pandemic, local anesthesia methods (topical anesthesia) were preferred except for cases in which general anesthesia was absolutely necessary. All patients in the pre-pandemic group were operated under general anesthesia, whereas the ratio of general to local anesthesia was 31:2 in globe trauma cases during the pandemic ($p=0.250$).

There were no differences in the clinical characteristics and surgical interventions of globe injury cases before and during the pandemic (Table 2). In 2004, Kuhn et al.⁶ developed an international identification system to create a standard definition for describing the features of mechanical globe traumas (BETTS). This classification system is important both in terms of creating a standardized language among ophthalmologists and providing a one-to-one relationship between definitions and clinical features. The aim of the system was to create a nomenclature that could be used in daily practice by classifying mechanical globe traumas in a simple and understandable way. We used the BETTS to classify the patients in this study and found that there were no significant differences between the groups in terms of clinical

characteristics. When we evaluated the cases according to trauma site, the groups showed no difference in traumatized tissues. The most commonly affected area in all patients was the cornea (68.5%). Intravitreal hemorrhage was detected in 29.6% of the patients. There is no definite information regarding the timing of vitrectomy in open-globe traumas. While some authors advocate early pars plana vitrectomy, others consider it more appropriate to wait 7-14 days after primary repair.¹⁸ In our study, the average timing of pars plana vitrectomy was approximately 11.3 days after primary repair.

In this study, the length of hospital stay was significantly shorter for patients who presented during the pandemic. This difference can be attributed to the efforts made to move patients out of the emergency department and get them to a level where they can be treated in the outpatient or home setting as quickly as possible. In the literature, the recommendation for postoperative patient follow-up is to discharge the patient after the first postoperative day and schedule outpatient visits on postoperative day 3 and at 1 week.²³ As opposed to the face-to-face examinations we performed during follow-up, evidence indicates that telemedicine practices, which have not yet been widely implemented in Turkey, are beneficial in terms of reducing patients' hospital visits and minimizing the risk of transmission in situations such as the pandemic.²⁴ The significant difference in the mean follow-up times of the patients in our study is due to the fact that the operations of patients in the pre-pandemic group were performed chronologically earlier (Group 1: 6.6 months, Group 2: 2.5 months; $p < 0.05$).

Conclusion

During the COVID-19 pandemic, emergency surgeries continue to be performed in other pandemic hospitals such as ours and throughout the country. As globe injuries occur mostly in the younger population and can cause permanent visual morbidity, they should be treated as soon as possible and with the most appropriate surgical approach. In this study, the postoperative improvement in vision was satisfactory in both groups. Therefore, if patients are treated with the appropriate precautions, visual gain is achieved. Considering that globe trauma is more common in the young population, it is very important to determine and apply appropriate treatment algorithms. All available protective measures should be taken to protect both patients and healthcare professionals during the pandemic. The data obtained in our study encompass a limited time period. Therefore, multicenter studies involving larger patient groups are needed.

Ethics

Ethics Committee Approval: Approval for the study was obtained from Balıkesir University Clinical Research Ethics Committee (decision number: 2021/122).

Peer-review: Externally peer reviewed.

Authorship Contributions

Surgical and Medical Practices: G.S.V., E.K., Concept: G.S.V., Design: G.S.V., Data Collection or Processing: S.Y., G.S.V.,

Analysis or Interpretation: G.S.V., E.K., C.G., Literature Search: G.S.V., S.Y., Writing: G.S.V.

Conflict of Interest: No conflict of interest was declared by the authors.

Financial Disclosure: The authors declared that this study received no financial support.

References

1. T.C. Sağlık Bakanlığı Bilim Kurulu Çalışması . COVID-19 (SARS-CoV-2 ENFEKSİYONU) REHBERİ. Nisan 2020
2. Türk Oftalmoloji Derneği Covid-19, <https://koronavirus.todnet.org/pandemi-nedeni-ile-acil-kabul-edilen-gz-ameliyatlari> (accessed 19 March 2021).
3. Matsa E, Shi J, Wheeler KK, McCarthy T, McGregor ML, Leonard JC. Trends in emergency department visits for pediatric acute ocular injury. *JAMA Ophthalmol.* 2018;136:895-903.
4. Négrel AD, Thylefors B. The global impact of eye injuries. *Ophthalmic Epidemiol.* 1998;5:143-169.
5. Kuhn F, Maisiak R, Mann L, Mester V, Morris R, Witherspoon CD. The Ocular Trauma Score (OTS). *Ophthalmol Clin North Am.* 2002;15:163-165.
6. Kuhn F, Morris R, Witherspoon CD, Mester V. Birmingham Eye Trauma Terminology system (BETT). *J Fr Ophthalmol.* 2004;27:206-210.
7. Pellegrini M, Roda M, Di Geronimo N, Lupardi E, Giannaccare G, Schiavi C. Changing trends of ocular trauma in the time of COVID-19 pandemic. *Eye (Basingstoke).* 2020;34:1248-1250.
8. Tabatabaei SA, Soleimani M, Behrooz MJ, Sheibani K. Systemic oral antibiotics as a prophylactic measure to prevent endophthalmitis in patients with open globe injuries in comparison with intravenous antibiotics. *Retina.* 2016;36:360-365.
9. Cabalag MS, Wasiak J, Syed Q, Paul E, Hall AJ, Cleland H. Early and late complications of ocular burn injuries. *J Plast Reconstr Aesthetic Surg.* 2015;68:356-361.
10. Hamroush A, Qureshi M, Shah S. Increased risk of ocular injury seen during lockdown due to COVID-19. *Contact Lens and Anterior Eye.* 2020;43:216.
11. Wu C, Patel SN, Jenkins TL, Obeid A, Ho AC, Yonekawa Y. Ocular trauma during COVID-19 stay-at-home orders: a comparative cohort study. *Curr Opin Ophthalmol.* 2020;31:423-426.
12. Rhodes HX, Petersen K, Biswas S. Trauma Trends During the Initial Peak of the COVID-19 Pandemic in the Midst of Lockdown: Experiences From a Rural Trauma Center. *Cureus.* 2020;12:e9811.
13. Sahraravand A, Haavisto AK, Holopainen JM, Leivo T. Ocular trauma in the Finnish elderly – Helsinki Ocular Trauma Study. *Acta Ophthalmol.* 2018;96:616-622.
14. Liggett PE, Pince KJ, Barlow W, Ragen M, Ryan SJ. Ocular Trauma in an Urban Population: Review of 1132 Cases. *Ophthalmology.* 1990;97:581-584.
15. Sii F, Barry RJ, Abbott J, Blanch RJ, MacEwen CJ, Shah P. The UK paediatric ocular trauma study 2 (POTS2): Demographics and mechanisms of injuries. *Clin Ophthalmol.* 2018;12:105-111.
16. Faghihi H, Hajizadeh F, Esfahani MR, Rasoulinejad SA, Lashay A, Mirshahi A, Karkhaneh R, Tabatabaey A, Khabazkhoob M, Faghihi S. Posttraumatic endophthalmitis: Report no. 2. *Retina.* 2012;32:146-151.
17. Bhagat N, Nagori S, Zarbin M. Post-traumatic Infectious Endophthalmitis. *Surv Ophthalmol.* 2011;56:214-251.
18. Jonas JB, Knorr HLJ, Budde WM. Prognostic factors in ocular injuries caused by intraocular or retrobulbar foreign bodies. *Ophthalmology.* 2000;107:823-828.
19. Zhang Y, Zhang MN, Jiang CH, Yao Y, Zhang K. Endophthalmitis following open globe injury. *Br J Ophthalmol.* 2010;94:1111-1114.
20. Hernández DMR-B, Gómez VL. Ocular Trauma Score comparison with open globe receiving early or late care1. *Cir Cir.* 2015;83:9-14.
21. Essex RW, Yi Q, Charles PGP, Allen PJ. Post-traumatic endophthalmitis. *Ophthalmology.* 2004;111:2015-2022.
22. Maurya RP. Ocular trauma during COVID-19 crisis: Trends and management. *Indian J Clin Exp Ophthalmol.* 2020;6:478-479.

23. Natarajan S, Nair AG, Hegde R, Sundar G, Bapaye MM, Mukherjee G, Bhasin P, Sachdev MS, Sharma N, Sinha R; AIOS Writing Group: Alok Sen, Ashok Kumar Grover, Bhaskar Srinivasan, Jeevan S. Titiyal, Jayanta Kumar Das, Kasturi Bhattacharjee, Kim Ramasamy, J K S Parihar, Mehul Shah, O P Agrawal, Prashant Bawankule, Rajiv Raman, Ruchir Mehta, Rupesh Agrawal, Sanjiv Mohan, Shakeen Singh, Thirumalesh M B, Usha Kim, Vinod Kumar Baranwal. Guidelines for the management of ocular trauma during the COVID-19 pandemic. *Indian J Ophthalmol.* 2020;68:2483-2485.
24. Maj G, Simon DP, Usa MC. Teleophthalmology in the Evaluation of Ocular Trauma, <https://academic.oup.com/milmed/article/168/3/205/4820062> (2003, accessed 19 March 2021).